

# Superior Canal Dehiscence: A Comparative Postmortem Multislice Computed Tomography Study

Philipp Mittmann, MD<sup>1</sup>, Arne Ernst, MD<sup>1</sup>, Rainer Seidl, MD<sup>1</sup>, Anna-Felicitas Skulj, MD<sup>2</sup>, Sven Mutze, MD<sup>2</sup>, Marc Windgassen, MD<sup>3</sup>, and Claas Buschmann, MD<sup>3</sup>

OTO Open

1-6

© The Authors 2018

Article reuse guidelines:

sagepub.com/journals-permissions

DOI: 10.1177/2473974X18793576

http://oto-open.org



No sponsorships or competing interests have been disclosed for this article.

Received March 8, 2018; revised July 11, 2018; accepted July 19, 2018.

## Abstract

**Objective.** Superior canal dehiscence is defined by missing bony coverage of the superior canal against the middle cranial fossa. The gold standard in diagnosis is high-resolution computed tomography (CT). A false-positive CT scan, identifying a dehiscence when one is not present, could lead to unnecessary surgical therapy. This study aims to compare postmortem CT scans with autopsy findings with regard to superior canal dehiscence.

**Study Design.** Postmortem study.

**Setting.** Tertiary referral center.

**Subjects and Methods.** Twenty-two nontraumatic death cases within a 3-month period (January to March 2017) were included with 44 temporal bones. Each body underwent postmortem head CT prior to medicolegal autopsy. The middle fossa floor was exposed, and if present, the superior semicircular canal dehiscence was identified and measured. In each case, 3 comparable photographs were taken during the autopsy (left temporal bone, right temporal bone, overview).

**Results.** Autopsy findings revealed bony dehiscences in 11% of the temporal bones, whereas CT scan revealed bony dehiscences in 16%. The length of the dehiscences were longer when measured by CT imaging.

**Conclusion.** The diagnosis of superior canal dehiscence syndrome requires high-resolution CT with clinical symptoms and physiologic evidence of a third mobile window. Our study underlines a mismatch between multislice CT imaging in the coronal plane and the presence of a dehiscence on autopsy.

## Keywords

semicircular dehiscence, postmortem CT, vertigo, high-resolution CT

Superior canal dehiscence (SCD) was first described by Minor et al in 1998, and it is characterized by missing bony coverage of the superior canal against the middle cranial fossa.<sup>1</sup> Patients with SCD syndrome may present with different vestibular and audiologic symptoms. In addition to oscillopsia and rotational vertigo, Tullio phenomenon, Hennebert sign, and Valsalva-related vertigo can be present with vestibular symptoms.<sup>1,2</sup> Hyperacusis to bone-conducted sound, autophony, low-frequency air-bone gap, and negative bone conduction thresholds are characteristic.<sup>1,3</sup> Pathophysiologically, the symptoms are assumed to be related to a third window phenomenon, which should lead to a modified labyrinthine perception of noise and pressure-related changes inside the labyrinthine fluid system.<sup>1,4-6</sup>

In a study of 1000 temporal bones among 596 people, incidence of bony dehiscence was 0.5%.<sup>7</sup> With clinical symptoms, the radiologic evaluation (high-resolution, flat panel, or cone beam computed tomography) with a maximum slice thickness of 0.5 mm is important to detect a superior semicircular canal dehiscence. Besides radiologic findings, further diagnostic points (eg, pure tone audiogram, cervical vestibular evoked myogenic potential) have to be observed to determine that pressure is being transmitted via the dehiscence, causing symptoms.<sup>8,9</sup>

<sup>1</sup>Department of Otolaryngology-Head and Neck Surgery, Unfallkrankenhaus Berlin, Berlin, Germany

<sup>2</sup>Department of Radiology, Unfallkrankenhaus Berlin, Berlin, Germany

<sup>3</sup>Charité-Universitätsmedizin Berlin, Freie Universität Berlin, Humboldt-Universität zu Berlin, and Berlin Institute of Health, Institute of Legal Medicine and Forensic Sciences, Berlin, Germany

## Corresponding Author:

Philipp Mittmann, MD, Department of Otolaryngology-Head and Neck Surgery, Unfallkrankenhaus Berlin, Warener Str 7, 12683 Berlin, Germany. Email: philipp.mittmann@googlemail.com



Creative Commons CC-BY-NC: This article is distributed under the terms of the Creative Commons Attribution 4.0 License (<http://www.creativecommons.org/licenses/by/4.0/>) which permits any use, reproduction and distribution of the work without

further permission provided the original work is attributed as specified on the SAGE and Open Access pages (<https://us.sagepub.com/en-us/nam/open-access-at-sage>).

The association of the SCD length and the signs and symptoms of SCD syndrome is currently under discussion. A larger defect was shown to correlate with vestibulocochlear manifestations,<sup>10</sup> while other studies did not find an association between the SCD length and clinical presentation.<sup>11-13</sup> Audiologically, the air-bone gap increased with a larger SCD,<sup>13-15</sup> while other studies found no correlation between the SCD length and the degree of hearing loss.<sup>12,16</sup> Some of these studies comparing length with the air-bone gap used CT data,<sup>12,14</sup> and others used direct intraoperative observation via the middle fossa.<sup>13</sup> The location of the dehiscence closer to the ampulla seems to have a greater impact on auditory and vestibular symptoms.<sup>15</sup> Relatively small sample sizes and varied methods of measuring SCD length might explain these varying results.

The surgical therapeutic options include transmastoid canal occlusion or occlusion via the middle fossa. Both surgical strategies showed good results with a control of vertigo and hearing preservation.<sup>17,18</sup>

In the transmastoid approach, the dehiscence itself cannot be seen, whereas via the middle fossa, the dehiscence can be identified and plugged or sealed. However, the dehiscence might be challenging to identify due to missing anatomic landmarks.<sup>19</sup> In addition to contributing to the diagnosis, radiologic scans can affect preoperative planning.

The present study aims to evaluate the accordance of the radiologically determined size of the superior semicircular canal dehiscence and the real anatomic dehiscence.

## Material and Methods

The study was approved by the institutional review board at the Unfallkrankenhaus Berlin (IRB-ukb-HNO-2017/01) and was conducted according to the principles expressed in the Declaration of Helsinki.

Twenty-two death cases within a 3-month period (January to March 2017) were included in this prospective autopsy study, including both temporal bones from each body ( $n = 44$ ). The inclusion criteria were absence of putrefaction and any known head trauma and/or surgery prior to death, completely removed dura from the middle fossa, and completed CT scan. Prior to medicolegal autopsy, each body was

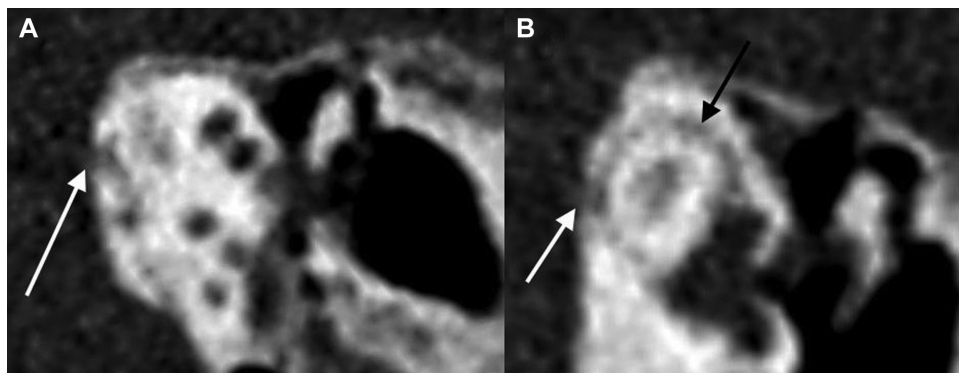
scanned with a 16-slice CT scanner (Toshiba Activion; Toshiba Medical Systems GmbH, Neuss, Germany) with a slice thickness of 0.5 mm and an overlap of 0.3 mm. Reconstructions of 2- and 3-dimensional volume-rendered images were performed with the accessory software as described previously.<sup>20,21</sup> The acquired CT images were analyzed and interpreted by an experienced neuroradiologist. The CT scans were reformatted coronal to the longitudinal axis of the temporal bone in the Poschl view. The images were obtained in a separate bone window in addition to a soft tissue window.

After the CT scan, all bodies underwent a forensic autopsy according to current German guidelines. The skull cap was opened circular with an oscillating bone saw, and the brain and the dura were removed carefully with an elevator. The middle fossa was exposed, and the superior semicircular canal dehiscence was identified and measured if present. Despite the putridity of the specimens, soft tissue remained in contact with bone over the superior semicircular canal. Three photographs were taken in each case (right temporal bone, left temporal bone, overview of the skull base) with a Sony  $\alpha 6000$  camera (24.3 megapixels; Sony Corp, Thailand) and a Sony objective (SELP 1650). Each picture was approximately 5 MB in size with a resolution of 350 dpi. The medical information about audiologic, vestibulocochlear, or neurologic symptoms was not available.

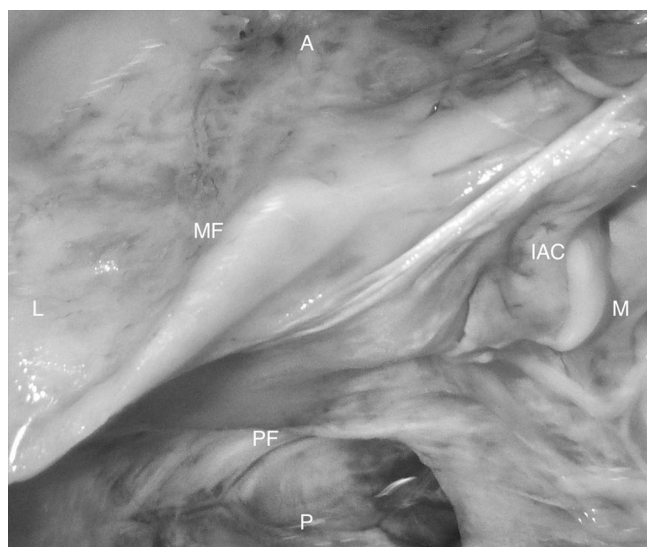
## Results

Eighteen bodies were male and 4 bodies were female, with a mean age of 43 years (range, 23-75 years). The causes of death included intoxication ( $n = 1$ ), hanging ( $n = 16$ ), drowning ( $n = 1$ ), smoke gas inhalation ( $n = 2$ ), and hemorrhagic shock ( $n = 2$ ). Of the 44 temporal bones, 2 showed radiologic dehiscences of the superior semicircular canal on the right side and 5 on the left side (**Figure 1**). One case was identified with a bilateral dehiscence. In total, 16% (7 of 44 temporal bones) showed bony dehiscences on CT scans.

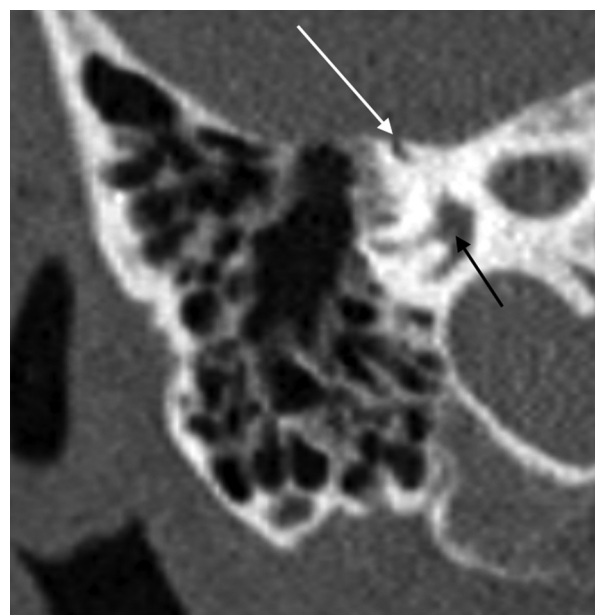
Autopsy findings revealed bony dehiscences in 11% (5 of 44 temporal bones; **Figure 2**). Three dehiscences of the superior semicircular canal were found on the left side and



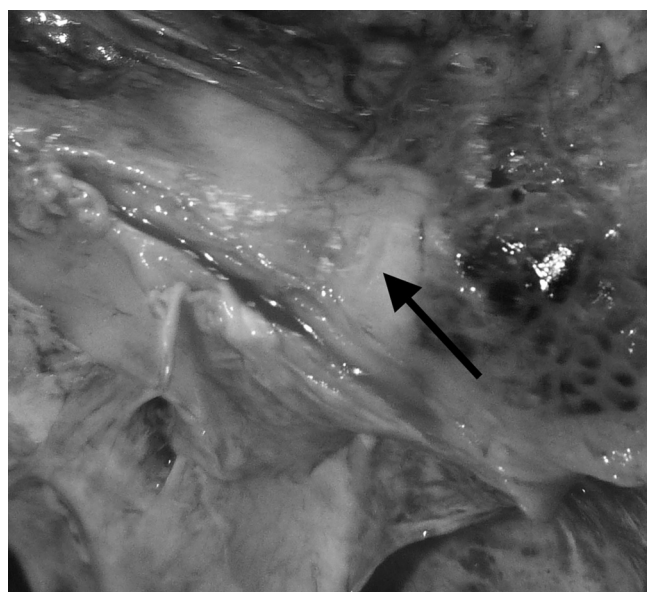
**Figure 1.** Reformatted 2-dimensional computed tomography scan of specimen 14 of the left side: Poschl view. (a, b) The white arrows point to the dehiscence; (b) the black arrow points to the superior semicircular canal.



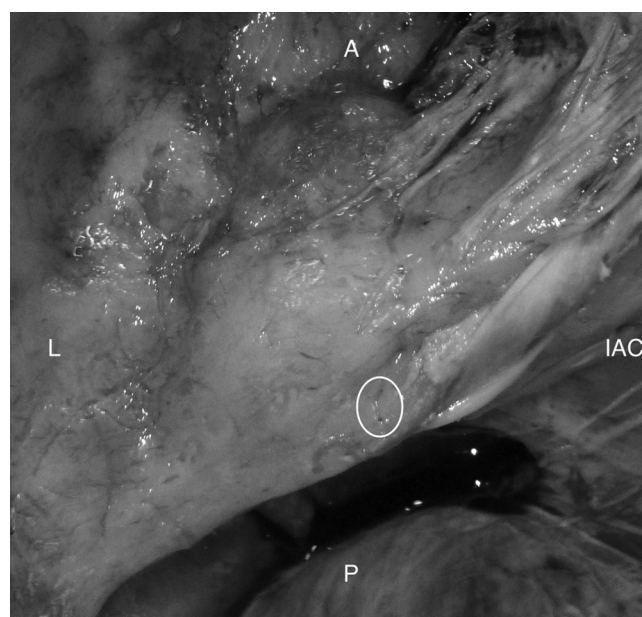**Figure 2.** Autopsy findings of the left middle fossa of specimen 14. A bony dehiscence of the superior semicircular canal was not seen, despite the radiologic findings in **Figure 1**. A, anterior; IAC, internal auditory canal; L, lateral; M, medial; MF, middle fossa; P, posterior; PF, posterior fossa.



**Figure 4.** Reformatted 2-dimensional computed tomography scan of specimen 19 of the right side, coronal to the longitudinal axis of the temporal bone. The white arrow points to the dehiscence, the black arrow to the labyrinth.



**Figure 3.** Autopsy findings of the right middle fossa of specimen 19. A bony dehiscence of the superior semicircular matched with the radiologic findings in **Figure 4**. The arrow points to the dehiscence.



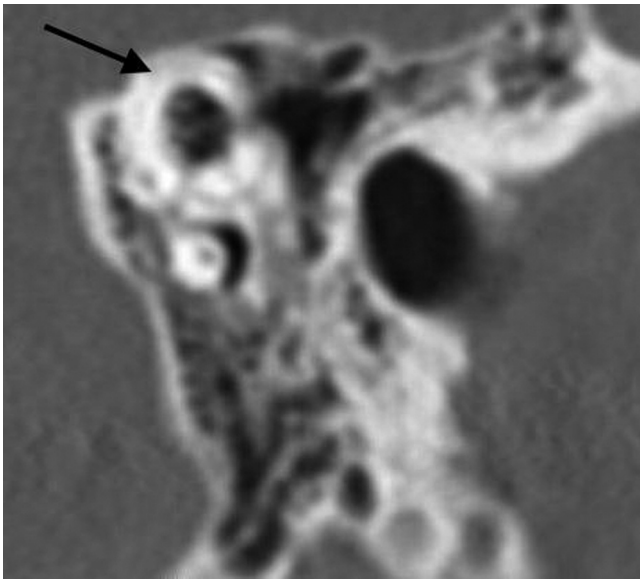
**Figure 5.** Autopsy findings of the left middle fossa of specimen 4. A bony dehiscence of the superior semicircular was seen during autopsy (circled) but not on the computed tomography scan. A, anterior; IAC, internal auditory canal; L, lateral; P, posterior.

2 on the right, whereas 1 specimen showed a bilateral dehiscence. Only in the case with the bilateral dehiscences did radiology and autopsy findings correlate (**Figures 3 and 4**). In the other cases, autopsy and radiology findings did not match (**Figures 5 and 6**). Fisher's exact test was conducted between the radiologic and autopsy findings of the bony dehiscences. There was not a statistically significant association between the radiologic and autopsy findings ( $P = .182$ ).

The sensitivity for CT scan identifying a dehiscence was 40%, and the specificity was 87%.

The total length of the bony dehiscences in the autopsy findings was 1 mm in 1 left temporal bone and 2 mm in the other temporal bones. In the radiologic evaluation, 3 dehiscences measured 1 mm; 1 measured 1.5 mm; and 1 measured 2 mm. Both temporal bones where autopsy and





**Figure 6.** Reformatted 2-dimensional computed tomography scan of specimen 4 of the left side, coronal to the longitudinal axis of the temporal bone. The black arrow points to the intact semicircular canal.

radiologic findings matched up had 2 mm in autopsy and 2.5 mm in radiologic evaluation (**Table 1**).

## Discussion

SCD syndrome is characterized by missing bony coverage to the middle fossa. Symptoms may vary, but they include audiologic and vestibular symptoms.

The gold standard to detect the SCD is the high-resolution CT of the temporal bone. If the clinical presentation is in accordance with the radiologic findings, surgical therapy can be an option.<sup>22</sup> The surgical planning will be based on the CT scan. In our study, we found differences between the radiologic and autopsy findings (**Figures 1** and **3**). Only 2 dehiscences detected by radiology were discovered on autopsy. Radiologically, 4 temporal bones showed small bony coverage over the superior semicircular canal. The bony patency of the middle fossa was confirmed in these cases. Different authors stated a relation between the size of the dehiscence and the clinical appearance. An extended defect can correlate with vestibulocochlear manifestations,<sup>9,13</sup> while other studies did not find an association between the SCD length and the clinical presentation or degree of hearing loss.<sup>8,11</sup> In our study, clinical symptoms were not part of the investigation, as medically relevant information was not available. The bony dehiscences were between 1 and 2 mm in total length. In comparison with the radiologic evaluation, our autopsy findings showed a smaller dehiscence. This is in line with the study by Tavassolie et al, who demonstrated that the real size of a bony dehiscence is usually smaller than that predicted by the CT scans.<sup>8</sup> Furthermore, they found 2 patients with radiologic dehiscences that were not seen intraoperatively but did show typical symptoms of the SCD syndrome.<sup>8</sup>

**Table 1.** Overview of All Subjects.<sup>a</sup>

No.	Sex	PM Interval, d	Right Side		Left Side	
			Autopsy Finding	CT Finding	Autopsy Finding	CT Finding
1	M	6				
2	M	6				
3	F	6				
4	M	4			1	
5	F	4				
6	M	6				1.5
7	M	7				
8	M	6				
9	M	5				
10	M	5	2			2
11	M	5				
12	M	6				
13	M	6				
14	M	5		1		1
15	M	4				
16	M	5				1
17	M	5			2	
18	M	6				
19	F	10	2	2.5	2	2.5
20	F	4				
21	M	6				
22	M	7				

Abbreviations: CT, computed tomography; F, female; M, male; PM, postmortem.

<sup>a</sup>Values are presented as semicircular canal dehiscence in millimeters. Blank cells indicate no findings.

The transmastoid occlusion of the superior canal is a surgical option in cases in which patients are suffering from symptoms of SCDS. Besides the transmastoid occlusion, an access above the middle fossa is described, including a resurfacing or occlusion of the superior semicircular canal. The middle fossa approach<sup>23</sup> gives the surgeon a direct view of the bony dehiscence but may pose greater risk to the patient. The transmastoid approach is safe, highly effective, and very familiar for otologists.<sup>24</sup> This approach could pose less risk for the patient but does not permit a direct view of the dehiscence. Nevertheless, resolution of symptoms is more important than the approach.<sup>25-27</sup>

At autopsy, we were able to identify 5 dehiscences, while CT scans identified 7 dehiscences. This makes up 11% of autopsy findings and 16% of radiologic findings. Compared with histologic or radiologic studies, which state the prevalence of SCD to occur in 0.5% to 3%, our study population shows a clearly higher prevalence of SCD.<sup>7,28</sup> The small number of individuals included in this study might bias these findings.

Postmortem CT is a standard instrument in autopsy practice. The advantage of this virtual autopsy is the generation

of a 3-dimensional preautopsy snapshot of the body with excellent visualization of skeletal pathologies.<sup>29</sup> Despite these advantages, the virtual autopsy cannot replace the traditional autopsy. Our findings underline the importance of the autopsy as it outmatches the virtual autopsy.

Our study has some limitations. Medical records were not available for all enrolled specimens. Neither was it known if the specimen with SCD had any auditory or vestibular symptoms. Our study population was limited to specimens with nontraumatic causes of death and made up only 22 specimens with 44 temporal bones. Nevertheless, in our study population, 11% of the temporal bones had bony dehiscences. This contrasts with the literature and may be explained by the small cohort. Furthermore, the quality of our CT scans is not typical for the radiologic diagnosis of SCD in clinical practice.

## Conclusion

Superior semicircular dehiscence syndrome should be diagnosed by clinical and radiologic findings. We found a divergence between radiologic and autopsy—that is, anatomic findings in terms of occurrence and length.

## Author Contributions

**Philipp Mittmann**, acquisition of data, drafting the article, final approval, agreement to be accountable for all aspects; **Arne Ernst**, contributions to conception and design, revising, final approval, agreement to be accountable for all aspects; **Rainer Seidl**, contributions to conception and design, revising, final approval, agreement to be accountable for all aspects; **Anna-Felicitas Skulj**, acquisition of data, drafting the article, final approval, agreement to be accountable for all aspects; **Sven Mutze**, acquisition of data, revising, final approval, agreement to be accountable for all aspects; **Marc Windgassen**, acquisition of data, revising, final approval, agreement to be accountable for all aspects; **Claas Buschmann**, acquisition of data, drafting the article, agreement to be accountable for all aspects.

## Disclosures

**Competing interests:** None.

**Sponsorships:** None.

**Funding source:** None.

## References

- Minor LB, Solomon D, Zinreich JS, Zee DS. Sound- and/or pressure-induced vertigo due to bone dehiscence of the superior semicircular canal. *Arch Otolaryngol Head Neck Surg*. 1998;124:249-258.
- Minor LB. Clinical manifestations of superior semicircular canal dehiscence. *Laryngoscope*. 2005;115:1717-1727.
- Zhou G, Gopen Q, Poe DS. Clinical and diagnostic characterization of canal dehiscence syndrome: a great otologic mimicker. *Otol Neurotol*. 2007;28:920-926.
- Chien W, Ravicz ME, Rosowski JJ, Merchant SN. Measurements of human middle- and inner-ear mechanics with dehiscence of the superior semicircular canal. *Otol Neurotol*. 2007;28:250-257.
- Merchant SN, Rosowski JJ. Conductive hearing loss caused by third-window lesions of the inner ear. *Otol Neurotol*. 2008;29:282-289.
- Rosowski JJ, Songer JE, Nakajima HH, Brinsko KM, Merchant SN. Clinical, experimental, and theoretical investigations of the effect of superior semicircular canal dehiscence on hearing mechanisms. *Otol Neurotol*. 2004;25:323-332.
- Carey JP, Minor LB, Nager GT. Dehiscence or thinning of bone overlying the superior semicircular canal in a temporal bone survey. *Arch Otolaryngol Head Neck Surg*. 2000;126:137-147.
- Tavassolie TS, Penninger RT, Zuniga MG, Minor LB, Carey JP. Multislice computed tomography in the diagnosis of superior canal dehiscence: how much error, and how to minimize it? *Otol Neurotol*. 2012;33:215-222.
- Belden CJ, Weg N, Minor LB, Zinreich SJ. CT evaluation of bone dehiscence of the superior semicircular canal as a cause of sound- and/or pressure-induced vertigo. *Radiology*. 2003;226:337-343.
- Pfammatter A, Darrouzet V, Gartner M, et al. A superior semicircular canal dehiscence syndrome multicenter study: is there an association between size and symptoms? *Otol Neurotol*. 2010;31:447-454.
- Martin C, Chahine P, Veyret C, Richard C, Prades JM, Pouget JF. Prospective radiological study concerning a series of patients suffering from conductive or mixed hearing loss due to superior semicircular canal dehiscence. *Eur Arch Otorhinolaryngol*. 2009;266:1175-1181.
- Chi FL, Ren DD, Dai CF. Variety of audiologic manifestations in patients with superior semicircular canal dehiscence. *Otol Neurotol*. 2010;31:2-10.
- Chien WW, Janky K, Minor LB, Carey JP. Superior canal dehiscence size: multivariate assessment of clinical impact. *Otol Neurotol*. 2012;33:810-815.
- Yuen HW, Boeddinghaus R, Eikelboom RH, Atlas MD. The relationship between the air-bone gap and the size of superior semicircular canal dehiscence. *Otolaryngol Head Neck Surg*. 2009;141:689-694.
- Nielsen ME, Hamberg LM, Silverman JB, et al. Superior canal dehiscence length and location influences clinical presentation and audiometric and cervical vestibular-evoked myogenic potential testing. *Audiol Neurotol*. 2014;19:97-105.
- Mikulec AA, McKenna MJ, Ramsey MJ, et al. Superior semicircular canal dehiscence presenting as conductive hearing loss without vertigo. *Otol Neurotol*. 2004;25:121-129.
- Ung N, Chung LK, Lagman C, et al. Outcomes of middle fossa craniotomy for the repair of superior semicircular canal dehiscence. *J Clin Neurosci*. 2017;43:103-107.
- Ernst A, Todt I, Wagner J. Dehiscence syndromes: diagnosis and treatment [in German]. *HNO*. 2016;64:790-796.
- Patel NS, Hunter JB, O'Connell BP, Wanna GB, Carlson ML. An easy and reliable method to locate the dehiscence during middle fossa superior canal dehiscence surgery: it is a (c)inch. *Otol Neurotol*. 2016;37:1092-1095.
- Rosset A, Spadola L, Ratib O. OsiriX: an open-source software for navigating in multidimensional DICOM images. *J Digit Imaging*. 2004;17:205-216.

21. Guddat SS, Gapert R, Tsokos M, Oesterhelweg L. Proof of live birth using postmortem multislice computed tomography (pmMSCT) in cases of suspected neonaticide: advantages of diagnostic imaging compared to conventional autopsy. *Forensic Sci Med Pathol*. 2013;9:3-12.
22. Ziylan F, Kinaci A, Beynon AJ, Kunst HP. A comparison of surgical treatments for superior semicircular canal dehiscence: a systematic review. *Otol Neurotol*. 2017;38:1-10.
23. Niesten ME, McKenna MJ, Grolman W, Lee DJ. Clinical factors associated with prolonged recovery after superior canal dehiscence surgery. *Otol Neurotol*. 2012;33:824-831.
24. Beyea JA, Agrawal SK, Parnes LS. Transmastoid semicircular canal occlusion: a safe and highly effective treatment for benign paroxysmal positional vertigo and superior canal dehiscence. *Laryngoscope*. 2012;122:1862-1866.
25. Agrawal SK, Parnes LS. Transmastoid superior semicircular canal occlusion. *Otol Neurotol*. 2008;29:363-367.
26. Amoodi HA, Makki FM, McNeil M, Bance M. Transmastoid resurfacing of superior semicircular canal dehiscence. *Laryngoscope*. 2011;121:1117-1123.
27. Zhao YC, Somers T, van Dinther J, Vanspauwen R, Husseman J, Briggs R. Transmastoid repair of superior semicircular canal dehiscence. *J Neurol Surg B Skull Base*. 2012;73:225-229.
28. Masaki Y. The prevalence of superior canal dehiscence syndrome as assessed by temporal bone computed tomography imaging. *Acta Otolaryngol*. 2011;131:258-262.
29. von Stillfried S, Isfort P, Knuchel-Clarke R. Postmortem imaging procedures: experiences and perspectives [in German]. *Pathologe*. 2017;38:412-415.