

Sialendoscopy for Non-Stone Disorders: The Current Evidence

Evren Erkul, MD; M. Boyd Gillespie, MD, MSc

Objective: Review the current literature on the use of sialendoscopy in the treatment of non-stone disorders of the major salivary glands.

Data Sources: Eligible articles that reported on the use of sialendoscopy in the treatment of non-stone disorders were identified using MEDLINE, Embase, and Google Scholar through May 2016. The search used key words sialendoscopy, salivary endoscopy, salivary scope, salivary duct stenosis, salivary duct stricture, Sjogren's disease, radioiodine sialadenitis, salivary duct obstruction, sialadenitis, chronic sialadenitis, juvenile recurrent parotitis, parotitis, and radiation sialadenitis.

Review Methods: Full-length prospective and retrospective original articles; systemic reviews; and meta-analysis, including adults and children with adequate data for evaluating the sialendoscopy for non-stone disorders, were included. Individual case reports were excluded.

Results: There is an increasing trend for the use of sialendoscopy for salivary obstruction caused by a wide variety of non-stone disorders worldwide. The studies of sialendoscopy for non-stone disorders are often retrospective, of smaller sample size, and more subjective in measurement of patient outcome. The most common indications currently for the procedure are scars, juvenile recurrent parotitis, radioiodine sialadenitis, and Sjögren syndrome, respectively.

Conclusion: Although the initial evidence for the use of sialendoscopy for non-stone disorders is not as established as that for stones, it remains a promising gland-preserving tool in the management of non-stone disorders of major salivary glands.

Key Words: Sialendoscopy, salivary endoscopy, sialendoscopy, salivary scope, salivary duct stenosis, salivary duct stricture, Sjögren's disease, radioiodine sialadenitis, salivary duct obstruction, sialadenitis, chronic sialadenitis, juvenile recurrent parotitis, parotitis, radiation sialadenitis.

INTRODUCTION

The focus of treatment in salivary gland obstructive pathologies is to preserve the gland and its functions with a minimally invasive method. This approach mirrors the wider trend in surgery as a whole, which is increasingly focused on improving function and recovery via the use of improved optical technologies combined with smaller, strategically placed incisions. As a result, there is a growing trend and increasing interest in an endoscopic approach to diagnose and treat salivary gland obstructive disorders worldwide.

The discovery of the major salivary gland ductal system in anatomical human studies was first reported in the 17th century. Approximately 350 years following

this discovery, Königsberger et al. performed the first successful salivary endoscopy with a 0.8-mm flexible endoscope in 1990.^{1,2} Katz removed stone with a flexible scope using blind passage of a basket in 1991, and both Nahlieli et al. and Marchal described different types of sialendoscopy instruments and methods over the next decade.^{3,4} Zenk et al. reported the use of semirigid sialendoscope in different types of obstructive salivary disorders in 22 patients in 2004.⁵ In the same year, Nahlieli et al. presented the successful use of the sialendoscope in pediatric patients for juvenile recurrent parotitis.⁶ Nahlieli et al. likewise described sialendoscopy in the management of radioiodine sialadenitis in 2006.⁷ Marchal described the combined endoscopic and external method for the removal of salivary stones while preserving the major salivary gland in 2007.⁸ Since the first description of the endoscopic treatment of salivary gland disorders, more than 200 articles have been published as new instruments, disposable materials, and techniques have evolved.

Sialendoscopy is a minimally invasive procedure with a low rate of complications performed under local or general anesthesia that provides superior anatomical detail. In a nationwide review of data from Denmark, a study showed that there was a 26% reduction in the number of gland excisions for benign salivary gland disease after the introduction of sialendoscopy in 2004 compared to the 5 years prior.⁹ Although originally described in the treatment of obstructive salivary stones, sialendoscopy is increasingly applied to non-stone-related obstructive disorders that currently comprise greater than 50% of the

This is an open access article under the terms of the Creative Commons Attribution-NonCommercial-NoDerivs License, which permits use and distribution in any medium, provided the original work is properly cited, the use is non-commercial and no modifications or adaptations are made.

From the Department of Otorhinolaryngology, Gulhane Military Medical Academy, Haydarpaşa Training Hospital (E.E.), Istanbul, Turkey; the Department of Otolaryngology–Head and Neck Surgery, Medical University of South Carolina (M.B.G.), Charleston, South Carolina, U.S.A.

Editor's Note: This Manuscript was accepted for publication 31 July 2016.

Financial Disclosure: The authors have no funding, financial relationships, or conflicts of interest to disclose.

Send correspondence to M. Boyd Gillespie, MD, MSc, Department of Otolaryngology Head and Neck Surgery, Medical University of South Carolina, Charleston, SC 29425. E-mail: gillesmb@musc.edu

DOI: 10.1002/liv.2.33

TABLE I. Types of Salivary Obstruction Presenting to the MUSC Salivary Center 2011 to 2015.			
MUSC Salivary Center	Stone	Non-Stone	% Non-Stone Pathology
FY 2011	158	112	41%
FY 2012	159	192	55%
FY 2013	191	174	48%
FY 2014	167	203	55%
FY 2015	90	213	70%
Grand total	765	894	54%

FY = fiscal year; MUSC = Medical University of South Carolina.

patients presenting with salivary gland obstruction at one tertiary referral academic salivary center (Table I). The various non-stone diagnoses amenable to treatment with sialendoscopy are the subject of this review.

MATERIALS AND METHODS

Eligible articles that reported on the use of sialendoscopy in the treatment of non-stone disorders were identified using MEDLINE, Embase, and Google Scholar, through May 2016. The search used key words sialendoscopy; salivary endoscopy; salivary scope; salivary duct stenosis; salivary duct stricture; Sjogren's disease; radioiodine sialadenitis; salivary duct obstruction; sialadenitis; chronic sialadenitis; juvenile recurrent parotitis; parotitis; and radiation sialadenitis. Full-length prospective and retrospective original articles, systemic reviews and meta-analysis including adults and children with adequate data for evaluating the sialendoscopy for non-stone disorders were included. Individual case reports were excluded.

RESULTS

Scars

Obstructive sialadenitis is the most common benign disease of the major salivary glands, and salivary duct scar is the second most common cause of obstructive salivary disorders after stones. Ductal scars are estimated to contribute to 25% of obstructive cases overall. In patients with obstructive symptoms and negative imaging for stones, ductal scar is found in up to 50% to 90% of patients who undergo diagnostic sialendoscopy.^{10,11} Like other obstructive salivary disorders, salivary duct scar typically presents with painful swelling of the affected gland, most commonly during meals. This may occasionally result in recurrent bouts of bacterial sialadenitis, with fever, glandular swelling, overlying skin erythema, and purulent ductal secretion. Less commonly, patients will note worsening dry mouth with a reduction in the amount of saliva that they experience. Ductal scar most commonly presents in the parotid gland (75% of cases) in both children and adults.^{12,13} The scar tissue is most often localized to the main duct and ostium.

Ultrasound, sialography, and sialendoscopy have important roles in the diagnosis of obstructive salivary duct scar. Because normal salivary ducts cannot be seen on ultrasonography, visualization of a dilated duct on ultrasonography after sialogogue challenge indicates a ductal obstruction, which can often be localized by following

the dilated duct distally to the point where it is blocked. Although visualization of a ductal blockage on ultrasonography in the absence of stone suggests ductal scar, diagnostic sialendoscopy is required to confirm the diagnosis of ductal scar via direct visualization because most imaging modalities, with the possible exception of sialography, do not have the sensitivity to detect ductal scar. The goal of diagnostic sialendoscopy is a complete description of the obstructive scar tissue (Table II). A stricture is usually a short segment of intraluminal scar with either a complete blockage or pinhole lumen. A stenosis is a long segment circumferential narrowing of the ductal lumen (Fig. 1).

In cases of ductal scar where conservative management fails, sialendoscopy is often the best option for treatment. Salivary duct scar is often more amenable to a purely endoscopy approach compared to salivary stones. A large retrospective series found that significantly more non-stone obstructions could be treated with endoscopic approaches alone compared to stones (77% vs. 17%).¹⁴ The endoscope tip, microdrill, basket, balloon, dilators, bougies, and laser may be required in the treatment of scars.^{2,13,15–17} Steroids may be especially beneficial in cases of type 1 inflammatory stenosis that presents with ductal wall edema and hyperemia. If scar tissue is localized in the ostium or main duct, the surgeon may elect to insert a salivary stent at the conclusion of the procedure. The combined approach may be

TABLE II. Description of Salivary Duct Scar Tissue.	
Factor	Description
Tissue color	Pink-salmon/thin vessels
	Pale/avascular
	Erythematous/red/dilated vessels
Tissue consistency	Pliable
	Stiff
Scar location	Ostium
	Main duct (distal)
	Main duct (proximal)
	Hilum
	Intraglandular duct
Scar distance from ostium	Centimeters
Scar type	Stricture
	Stenosis
Scar grade	I (0–50% stenosis; 1.3 mm scope)
	II (50%–70% stenosis; 1.1 mm scope)
	III (70%–99% stenosis; 0.8 mm scope)
	IV (100%)
Scar extent	S0: No stenosis
	S1: One or more diaphragmatic stenoses
	S2: Single stenosis, main duct
	S3: Multiple stenosis, or complete main duct
	S4: Diffuse (main duct and intraglandular)
Scar inflammation	Type I: Inflammatory
	Type II: Web stenosis, segmental dilations
	Type III: Fibrotic, long-segment stenosis

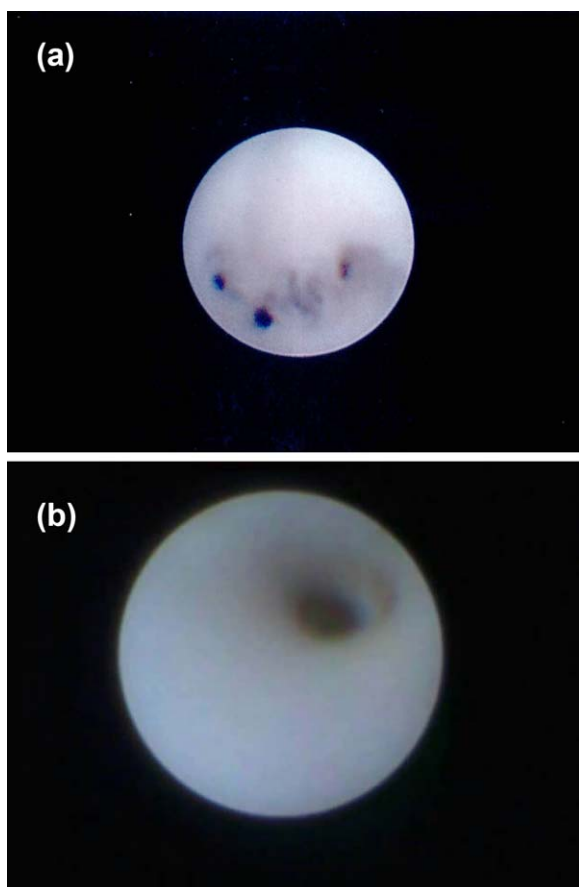


Fig. 1. Endoscopic view of a salivary duct stricture (A) and stenosis (B).

needed in cases of grade III (70%–99% blockage) or IV (100% blockage) scar of the ostium or main duct, which do not allow passage of a guidewire.

Several large series have shown excellent long-term outcomes with gland-preserving therapy for salivary duct scar. In a series of 82 patients with 98 parotid duct stenoses treated endoscopically, significant improvement was noted in symptoms and quality of life, as measured by a visual analog scale after a mean follow-up time

of 98 months.¹⁸ Although improved, 50% of patients continued to have low-grade swelling, and 20% continued to have recurrent pain. No patient underwent gland resection; however, 10% required repeat sialendoscopy. A separate large series of 206 patients with both stone and non-stone obstruction, most of which was due to ductal scar, observed improvement in both the stone (96%) and non-stone (81%) groups by patient report after sialendoscopy.¹⁴ When compared to the stone group, non-stone obstructions were associated with significantly higher rates of persistent symptoms (59% vs. 34%), as well as lower quality of life as measured by a modified oral health outcome survey. There was no higher rate in repeat surgery (6% vs. 13%) or gland excision (8% vs. 9%) in the stone group compared to the non-stone group. Kopec et al. reported the results of 35 Stensen's duct and 24 Wharton's duct stenoses treated with interventional sialendoscopy followed by stenting for 14 to 21 days. Most of the stenoses were localized in the papilla and distal part in both the parotid and submandibular glands. Although they did not report the evaluation method of symptom improvement, the authors found a 78% improvement of symptoms after a mean follow-up of 24 months.¹⁹

Juvenile Recurrent Parotitis

Juvenile recurrent parotitis (JRP) is the second most common salivary gland disease in children behind mumps; it most commonly occurs in boys between the ages of 4 months and 15 years.²⁰ The disease frequently presents unilaterally with acute swelling, independent of meals without seasonal or diurnal pattern. Pain, fever, hyposalivation, mucoid secretion, and/or redness of the skin overlying the affected gland are common symptoms that generally subside within 48 to 72 hours. These symptoms can recur every few weeks to months and may significantly reduce quality of life. Attempts to preserve the gland are of the essence because the disorder often resolves spontaneously at puberty. Although the exact cause of the disorder is unknown and may be multifactorial, ductal ectasia due to weakness of the surrounding tissue, genetic factors, allergy, and postviral inflammation have been suggested as possible etiologies.²⁰

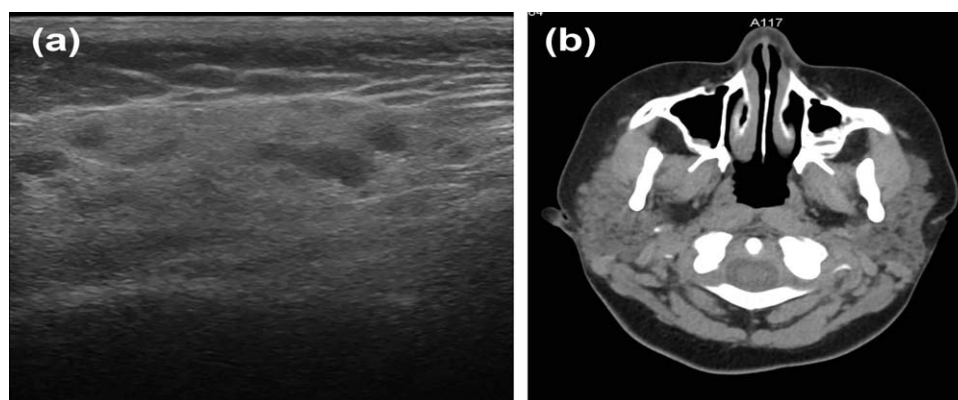


Fig. 2. Scattered hypodensities within a uniform enlarged salivary gland on ultrasound (A) and noncontrast computed tomography (B) are consistent with the diagnosis of juvenile recurrent parotitis.

Ultrasonography or computed tomography are the most commonly used imaging modalities and can help confirm the diagnosis due to JRP's stereotypic appearance. Imaging commonly shows scattered radiolucencies consistent with salivary stasis within the parenchyma of the gland, which are often described as a *Swiss cheese* or *moth-eaten* pattern (Fig. 2). The treatment of JRP consists of the prevention of recurring attacks, with sufficient hydration and avoidance of drying medications, as well as treating episodes with antibiotics, heat application, massage, dilation, and steroid and saline irrigation.²⁰ In recent years, studies have examined the role of sialendoscopy in the management of JRP. Sialendoscopy findings in JRP include a pale ductal wall without clearly seen blood vessels, tortuous or kinked ducts, ductal ectasia, focal/diffuse stenosis, and mucus plugs.^{20,21}

Canzi et al. reviewed the literature of the diagnostic and therapeutic outcomes after sialendoscopy treatment in patients with JRP.²¹ They reported 179 children (109 males, 70 females) with an average age of 7.8 years, with a mean frequency of JRP events prior to sialendoscopy of 5.5 attacks per year. Diffuse stenosis and multiple fibrinous debris/mucous plugs were observed in a high percentage of children (mean 56% and 45%, respectively). Ductal irrigation with isotonic saline plus steroids was commonly used with additional application of microdrills or balloon dilation in some patients. Complete resolution of JRP attacks after sialendoscopy treatment was observed in 78%, with the remaining 22% noting a reduction in the frequency of episodes.²¹ Ramakrishna et al. performed a systemic review of sialendoscopy for the treatment of JRP in 2015 and found a no further episode success rate of 81% without report of major complications.²² The benefits of sialendoscopy reported by various studies include the sialendoscopic differentiation of JRP from other pediatric salivary gland disorders, allowing therapeutic irrigation (saline and/or corticosteroid) and interventions (dilatation, balloon), reducing antibiotic usage, improving quality of life by reducing acute episodes, and minimally invasive treatment with a low risk of complications.^{22–26}

Despite the potential benefits, the role of sialendoscopy for JRP remains a subject of debate. Schneider et al. compared patients treated with sialendoscopy with corticosteroid irrigation to those treated with oral antibiotics alone.²⁷ The study found a significant reduction in episodes and pain in both groups, which led the authors to conclude that although sialendoscopy helps to confirm the diagnosis of JRP and provides a treatment option, its role requires ongoing evaluation in future prospective studies.²⁷ Rosbe et al. also compared the effectiveness and cost of sialendoscopy with conservative therapy and found that sialendoscopy had higher care costs with similar outcomes to conservative therapy alone.²⁸ Roby et al. treated the JRP patients with only ductal corticosteroid infusion without sialendoscopy and found a 75% improved quality of life similar with reported rates for sialendoscopy. The author hypothesized that the corticosteroid infusion, not the sialendoscopy, was the source of the improvement.²⁹ This study was limited by a small

sample size, with only eight patients completing the quality-of-life survey.

Although there are encouraging studies that show benefit with sialendoscopy for JRP, there is a lack of prospective, randomized controlled studies comparing it to conservative treatment alone. The best approach may be a wait-and-see approach with use of conservative measures, initially followed by the option of sialendoscopy if there are three episodes within a 6-month period or four episodes within a year. Other options include dilation and steroid infusion in the office, or under light sedation if salivary scopes are not readily available for use.

Radioiodine Sialadenitis

A major potential side effect of radioiodine (RAI) treatment for well-differentiated thyroid carcinoma is both short- and long-term radiation sialadenitis of the salivary glands. Salivary glands have a capacity to concentrate iodine 7 to 700 times higher than serum. Secretion of radioiodine into saliva from ductal epithelium may lead to periductal inflammation and fibrosis.^{30–32} The parotid gland is the most affected salivary gland because it consists of a higher proportion of serous cells, which are more susceptible to the hazardous effects of radiation compared to other cell types.^{30,32–34} The other effect of radioiodine is endothelial damage, which changes the biochemical content and quality of the saliva, thereby reducing its function.³⁰ Acute symptomatic sialadenitis varies with a range of 2% to 67% due to various factors.^{31,35,36} Early swelling and pain may be observed in the first few days after therapy, but the exact rate of early swelling and pain is not known. These symptoms are rapid, dose-related, and often heal without specific intervention.³⁰ Some glands, however, will undergo progressive damage, which present as persistent symptoms consistent with chronic sialadenitis.³⁰

Sialendoscopy has been helpful in delineating the pathogenesis of the chronic radioiodine sialadenitis. Initially, the ductal lumen narrows and forms strictures and mucus plugs. This creates an obstruction that causes the onset of symptoms of swelling and pain mostly during meals. The obstruction predispose to infection, thereby further worsening duct wall scarring and reduced salivary production.³⁰

Clement et al. reported a systemic review of intermediate- and long-term side effects after RAI treatment. The authors found that there is an association between symptomatic and objective salivary gland dysfunction and higher cumulative dosage of RAI.³⁷ However, they found that the prevalence of symptomatic salivary gland dysfunction was lower than objective salivary gland dysfunction (16%–54% vs. 37%–72%, respectively).³⁷ Dingle et al. evaluated RAI sialadenitis in thyroid cancer survivors and found an association between RAI dose and head-and-neck quality of life. When patients were divided into high- (> 150 mCi) and low-dose (< 150 mCi) groups, high-dose patients were 2.5 times more likely to experience sialadenitis, as well as a reduction in

swallowing-related and global head-and-neck quality of life.³⁸

Although the present literature is largely limited to small case series, sialendoscopy appears to be an effective method to manage RAI-induced sialadenitis in the majority of patients unresponsive to conservative measures, often with a single intervention. This success rate is attributed to the removal of mucus plugs, dilation of strictures, and reduction of inflammation from steroid irrigations. Management of sialadenitis and obstructive symptoms is more effective than reducing symptoms of xerostomia. Few complications have been reported, and the procedure is considered low risk. Nahlieli et al. presented the first series of RAI sialadenitis patients treated with sialendoscopy and 100 mg hydrocortisone irrigation in 2006, and found a success rate of 100% without complication in 15 patients.⁷ The authors noted that ductal obstruction was central to salivary pathology following radioiodine therapy.⁷ Kim et al. evaluated 10 patients treated with a median RAI dose of 165 mCi, with subjective symptom scores, salivary flow rate, and salivary gland scintigraphy prior to treatment and 3 months after sialendoscopy.³⁹ The study observed post-operative obstructive symptoms were significantly improved without significant change in xerostomia-related symptoms, salivary flow rates, or scintigraphy functional results.³⁹

Bomeli et al. published a retrospective analysis of 12 patients with RAI sialadenitis following a mean dose of 143 mCi treated with sialendoscopy.⁴⁰ Sialendoscopy revealed mucus plugs and debris in 32 glands, which were removed with irrigation or wire basket followed by irrigation with 40 mg triamcinolone. They reported a 75% symptom improvement with no serious complications after a median follow-up of 6 months.⁴⁰ In a similar study of 11 patients, Prendes et al. found a 54% complete resolution at a mean follow-up of 18 months.⁴¹ They stated that therapeutic sialendoscopy provides effective and sustained symptom improvement in most patients.⁴¹ These studies suggest that sialendoscopy is useful for the improvement of symptoms related to RAI sialadenitis in patients who are refractory to conservative medical therapy.

A limitation of these initial studies is the retrospective design and subjective reporting of symptoms. More comprehensive evidence is found in the study of Bhayani et al., which prospectively followed 26 RAI-sialadenitis patients undergoing sialendoscopy following the failure of conservative management.⁴² Patients were evaluated with quality-of-life and xerostomia questionnaires and quantitatively with sialometry. After a median follow-up of 23 months, 64% of patients demonstrated complete resolution of RAI-related symptoms and 28% demonstrated partial resolution, but only 31.8% had complete resolution of their xerostomia symptoms and only 45.5% had partial resolution. There was a statistically significant improvement in unstimulated saliva production after 6 months of follow-up. The authors conclude that the beneficial effects are most often seen in patients with obstructive sialadenitis, and to a lesser extent in patients with RAI-induced xerostomia.⁴²

Sjögren's Syndrome

Sjögren's syndrome (SS) is a progressive systemic autoimmune disorder characterized by ectopic lymphocyte invasion of nonlymphoid mucosa and visceral organs.⁴³ The salivary and lacrimal glands are the most commonly involved sites, and the parotid gland is more often affected than the submandibular gland. Patients commonly complain of oral and ocular dryness and thick ropey saliva. Imaging studies, blood autoantibodies, and minor salivary gland biopsy are used for the diagnosis of the disorder.⁴³ There are a number of medical treatments for xerostomia; however, there are no evidence-based therapeutic guidelines for the management of primary SS.⁴⁴ Consequently, current therapeutic decisions are based on a mix of personal experience, expert opinion, and reported studies. Sialendoscopy has been increasingly employed in the differential diagnosis and treatment of SS in recent years, with pale, avascular ductal walls; atrophic ducts; mucus plugs; sialodochitis; and strictures being the most common endoscopic findings.^{17,45,46}

Therapeutic sialendoscopy options for the disorder are irrigation with saline to wash out mucus plugs and dilate the duct; dilation of strictures with salivary dilators or balloons; and infusion of corticosteroids to reduce inflammation.^{17,45} Vashishta et al. retrospectively evaluated the role of sialendoscopy for idiopathic chronic sialadenitis in 51 patients, five of whom were found to have SS.¹⁰ The authors found that scars and mucus plugs were the most common findings. Complete resolution was noted in 61% of patients after a mean follow-up of 20 months.¹⁰ De Luca et al. retrospectively evaluated the endoscopic management of obstructive salivary gland disorders related to SS in 34 patients.⁴⁵ They found strictures, mucus plugs, and kinks with rates of 45%, 55%, and 4%, respectively. Parotid glands were more often affected than submandibular glands (65% vs. 23%). Pain was assessed using a visual analog score and quality of life by questionnaire. In all, 85% of the patients had no pain after 6 months; and 85% of the patients had improvement in somatic and mental fatigue, general health, and social functioning. The authors concluded that symptomatic improvement could be due to the anti-inflammatory effect of hydrocortisone, as well as mechanical duct dilatation from hydrostatic pressure with saline solution.⁴⁵ Shacham et al. treated eight patients with SS of parotid glands using endoscopic techniques of hydrostatic pressure, balloon for dilation, removal of mucus plugs, and infusion of hydrocortisone.⁴⁶ After a mean follow-up of 6 months, all eight patients experienced resolution of symptoms, leading the authors to conclude that endoscopic management can relieve symptoms and increase quality of life of the patients with SS.⁴⁶

Jager et al. reported a prospective, randomized controlled study comparing a noninterventional control group (10 patients) and sialendoscopy group (10 patients) using salivary flow, xerostomia inventory, and oral dryness score at 1 week prior, and 1 and 8 weeks following sialendoscopy.⁴⁷ They also analyzed patient

blood markers in these all female cohorts. The xerostomia inventory score and oral dryness score were significantly lower at 1 and 8 weeks in treated patients compared to controls. Salivary flow was higher in the sialendoscopy group at 1 week and 8 weeks; however, this failed to reach statistical significance. The authors concluded that sialendoscopy appears to have a positive effect on subjective and some objective measurements for oral dryness symptoms; however, it is difficult to fully discern the efficacy of this treatment due to the small sample size and a short follow-up period.⁴⁷

CONCLUSION

Sialendoscopy has become a mainstay in the treatment of stone-related salivary obstruction and is being increasingly applied to salivary obstruction caused by a wide variety of non-stone disorders. Unlike the large, prospective studies describing sialendoscopy for stones using measurable outcomes such as successful stone removal, studies of sialendoscopy for non-stone disorders are often retrospective, of smaller sample size, and more subjective in measurements of patient outcome. Although the initial results are promising, better evidence in the form of randomized, controlled trials limited to single specific disorder will better establish the efficacy of sialendoscopy in the management of various non-stone obstructive disorders.

BIBLIOGRAPHY

- Lydiatt DD, Bucher GS. The historical evolution of the understanding of the submandibular and sublingual salivary glands. *Clin Anat* 2012;25:2–11.
- Nahlieli O, Naker LH, Nazarian Y, Turner MD. Sialendoscopy: a new approach to salivary gland obstructive pathology. *J Am Dent Assoc* 2006;137:1394–1400.
- Nahlieli O, Nader A, Baruchin AM. Salivary gland endoscopy: a new technique for diagnosis and treatment of sialolithiasis. *J Oral Maxillofac Surg* 1994;52:1240–1242.
- Marchal F, Becker M, Dulguerov P, Lehmann W. Interventional sialendoscopy. *Laryngoscope* 2000;110:318–320.
- Zenk J, Koch M, Bozzato A, Iro H. Sialoscopy—initial experiences with a new endoscope. *Br J Oral Maxillofac Surg* 2004;42:293–298.
- Nahlieli O, Shacham R, Shlesinger M, Eliav E. Juvenile recurrent parotitis: a new method of diagnosis and treatment. *Pediatrics* 2004;114:9–12.
- Nahlieli O, Nazarian Y. Sialadenitis following radioiodine therapy: a new diagnostic and treatment modality. *Oral Dis* 2006;12:476–479.
- Marchal F. A combined endoscopic and external approach for extraction of large stones with preservation of parotid and submandibular glands. *Laryngoscope* 2007;117:373–377.
- Rasmussen ER, Lykke E, Wagner N, Nielsen T, Waersted S, Arndal H. The introduction of sialendoscopy has significantly contributed to a decreased number of excised salivary glands in Denmark. *Eur Arch Otorhinolaryngol* 2016 Aug;273:2223–2230. doi: 10.1007/s00405-015-3755-x.
- Vashishta R, Gillespie MB. Salivary endoscopy for idiopathic chronic sialadenitis. *Laryngoscope* 2013;123:3016–3020.
- Koch M, Zenk J, Bozzato A, Bumm K, Iro H. Sialoscopy in cases of unclear swelling of the major salivary glands. *Otolaryngol Head Neck Surg* 2005;133:863–868.
- Martins-Carvalho C, Plouin-Gaudon I, Quenin S, et al. Pediatric sialendoscopy: a 5-year experience at a single institution. *Arch Otolaryngol Head Neck Surg* 2010;136:33–36.
- Wu CB, Xue L, Zhang B, Sun NN, Zhou Q. Sialendoscopy-assisted treatment for chronic obstructive parotitis-our treatment strategy with 31 patients. *J Oral Maxillofac Surg* 2015;73:1524–1531.
- Gillespie MB, O'Connell BP, Rawl JW, McLaughlin CW, Carroll WW, Nguyen SA. Clinical and quality-of-life outcomes following gland-preserving surgery for chronic sialadenitis. *Laryngoscope* 2015;125:1340–1344.
- Atienza G, Lopez-Cedrun JL. Management of obstructive salivary disorders by sialendoscopy: a systematic review. *Br J Oral Maxillofac Surg* 2015;53:507–519.
- Pace CG, Hwang KG, Papadakis ME, Troulis MJ. Sialadenitis without sialolithiasis treated by sialendoscopy. *J Oral Maxillofac Surg* 2015;73:1748–1752.
- Gillespie MB, Intaphan J, Nguyen SA. Endoscopic-assisted management of chronic sialadenitis. *Head Neck* 2011;33:1346–1351.
- Koch M, Kunzel J, Iro H, Psychogios G, Zenk J. Long-term results and subjective outcome after gland-preserving treatment in parotid duct stenosis. *Laryngoscope* 2014;124:1813–1818.
- Kopeck T, Szyfter W, Wierzbicka M, Nealis J. Stenoses of the salivary ducts-sialendoscopy based diagnosis and treatment. *Br J Oral Maxillofac Surg* 2013;51:e174–e177.
- Iro H, Zenk J. Salivary gland diseases in children. *GMS Curr Top Otorhinolaryngol Head Neck Surg* 2014;13:Doc06.
- Canzi P, Occhini A, Pagella F, Marchal F, Benazzo M. Sialendoscopy in juvenile recurrent parotitis: a review of the literature. *Acta Otorhinolaryngol Ital* 2013;33:367–373.
- Ramakrishna J, Strychowski J, Gupta M, Sommer DD. Sialendoscopy for the management of juvenile recurrent parotitis: a systematic review and meta-analysis. *Laryngoscope* 2015;125:1472–1479.
- Mikolajczak S, Meyer MF, Beutner D, Luers JC. Treatment of chronic recurrent juvenile parotitis using sialendoscopy. *Acta Otolaryngol* 2014;134:531–535.
- Ardekian L, Klein H, Al Abri R, Marchal F. Sialendoscopy for the diagnosis and treatment of juvenile recurrent parotitis. *Rev Stomatol Chir Maxillofac Chir Orale* 2014;115:17–21.
- Gary C, Kluka EA, Schaitkin B, Walvekar RR. Interventional sialendoscopy for treatment of juvenile recurrent parotitis. *J Indian Assoc Pediatr Surg* 2011;16:132–136.
- Semsensohn R, Spektor Z, Kay DJ, Archilla AS, Mandell DL. Pediatric sialendoscopy: initial experience in a pediatric otolaryngology group practice. *Laryngoscope* 2015;125:480–484.
- Schneider H, Koch M, Kunzel J, et al. Juvenile recurrent parotitis: a retrospective comparison of sialendoscopy versus conservative therapy. *Laryngoscope* 2014;124:451–455.
- Rosbe KW, Milev D, Chang JL. Effectiveness and costs of sialendoscopy in pediatric patients with salivary gland disorders. *Laryngoscope* 2015;125:2805–2809.
- Roby BB, Mattingly J, Jensen EL, Gao D, Chan KH. Treatment of juvenile recurrent parotitis of childhood: an analysis of effectiveness. *JAMA Otolaryngol Head Neck Surg* 2015;141:126–129.
- Mandel SJ, Mandel L. Radioactive iodine and the salivary glands. *Thyroid* 2003;13:265–271.
- Van Nostrand D. Sialoadenitis secondary to (131)I therapy for well-differentiated thyroid cancer. *Oral Dis* 2011;17:154–161.
- An YS, Yoon JK, Lee SJ, Song HS, Yoon SH, Jo KS. Symptomatic late-onset sialadenitis after radioiodine therapy in thyroid cancer. *Ann Nucl Med* 2013;27:386–391.
- Jeong SY, Kim HW, Lee SW, Ahn BC, Lee J. Salivary gland function 5 years after radioactive iodine ablation in patients with differentiated thyroid cancer: direct comparison of pre- and postablation scintigraphies and their relation to xerostomia symptoms. *Thyroid* 2013;23:609–616.
- Fard-Esfahani A, Emami-Ardekani A, Fallahi B, et al. Adverse effects of radioactive iodine-131 treatment for differentiated thyroid carcinoma. *Nucl Med Commun* 2014;35:808–817.
- Hyer S, Kong A, Pratt B, Harmer C. Salivary gland toxicity after radioiodine therapy for thyroid cancer. *Clin Oncol* 2007;19:83–86.
- Almeida JP, Sanabria AE, Lima EN, Kowalski LP. Late side effects of radioactive iodine on salivary gland function in patients with thyroid cancer. *Head Neck* 2011;33:686–690.
- Clement SC, Peeters RP, Ronckers CM, et al. Intermediate and long-term adverse effects of radioiodine therapy for differentiated thyroid carcinoma—a systematic review. *Cancer Treat Rev* 2015;41:925–934.
- Dingle IF, Mishoe AE, Nguyen SA, Overton LJ, Gillespie MB. Salivary morbidity and quality of life following radioactive iodine for well-differentiated thyroid cancer. *Otolaryngol Head Neck Surg* 2013;148:746–752.
- Kim YM, Choi JS, Hong SB, Hyun IY, Lim JY. Salivary gland function after sialendoscopy for treatment of chronic radioiodine-induced sialadenitis. *Head Neck* 2016;38:51–58.
- Bomeli SR, Schaitkin B, Carrau RL, Walvekar RR. Interventional sialendoscopy for treatment of radioiodine-induced sialadenitis. *Laryngoscope* 2009;119:864–867.
- Prenades BL, Orloff LA, Eisele DW. Therapeutic sialendoscopy for the management of radioiodine sialadenitis. *Arch Otolaryngol Head Neck Surg* 2012;138:15–19.
- Bhayani MK, Acharya V, Kongkiatkamon S, et al. Sialendoscopy for patients with radioiodine-induced sialadenitis and xerostomia. *Thyroid* 2015;25:834–838.
- Vitali C, Bombardieri S, Jonsson R, et al. Classification criteria for Sjogren's syndrome: a revised version of the European criteria proposed by the American-European Consensus Group. *Ann Rheum Dis* 2002;61:554–558.
- Ramos-Casals M, Tzioufas AG, Stone JH, Siso A, Bosch X. Treatment of primary Sjogren syndrome: a systematic review. *JAMA* 2010;304:452–460.
- De Luca R, Trodella M, Vicidomini A, Colella G, Tartaro G. Endoscopic management of salivary gland obstructive diseases in patients with Sjogren's syndrome. *J Craniomaxillofac Surg* 2015;43:1643–1649.
- Shacham R, Puterman MB, Ohana N, Nahlieli O. Endoscopic treatment of salivary glands affected by autoimmune diseases. *J Oral Maxillofac Surg* 2011;69:476–481.
- Jager DJ, Karagozoglu KH, Maarse F, Brand HS, Forouzanfar T. Sialendoscopy of salivary glands affected by Sjogren syndrome: a randomized controlled pilot study. *J Oral Maxillofac Surg* 2016;74:1167–1174.