

Single-incision versus conventional laparoscopic appendectomy: A case-match study

SAGE Open Medicine
2: 2050312114524195
© The Author(s) 2014
Reprints and permissions:
sagepub.co.uk/journalsPermissions.nav
DOI: 10.1177/2050312114524195
smo.sagepub.com


Gaëtan-Romain Joliat, Emilie Uldry, Nicolas Demartines and Markus Schäfer

Abstract

Background: Three-port laparoscopic appendectomy is considered standard in many countries for the surgical treatment of acute appendicitis. Single-incision laparoscopic technique has been recently introduced and is supposed to minimize the aggression induced by surgery. Regarding appendectomy, comparison with standard laparoscopy, benefits and drawbacks of this novel technique remain to be evaluated. The goal of this study was to assess single-incision laparoscopic appendectomy compared to conventional laparoscopic appendectomy in terms of operation time, length of hospital stay, complication rate, and postoperative antibiotherapy rate.

Methods: From February 2011 to December 2011, single-incision laparoscopic appendectomy was proposed to patients admitted to the emergency room of the University Hospital of Lausanne (CHUV, Lausanne, Switzerland), diagnosed with uncomplicated acute appendicitis. Preoperative patients' information, technical difficulties during the operation, and postoperative follow-ups were recorded. Every patient who underwent single-incision laparoscopic appendectomy ($n = 20$) was matched 1:3 conventional laparoscopic appendectomy ($n = 60$), controlling for age, gender, body mass index, American Society of Anesthesiologists score, and histopathological findings.

Results: No statistically significant differences for median operation time, length of hospital stay, complication rate, and need for postoperative antibiotherapy were found. In 5 out of 20 single-incision laparoscopic appendectomy patients the Endoloop® Ligature was judged difficult to put in place.

Conclusion: This study suggests that single-incision laparoscopic appendectomy is a feasible and effective operative technique for uncomplicated acute appendicitis.

Keywords

Acute appendicitis, minimally invasive surgery, laparoscopic appendectomy, single-incision laparoscopic surgery, single-incision laparoscopic appendectomy

Date received: 7 November 2013; accepted: 31 December 2013

Introduction

Acute appendicitis is the most frequent abdominal surgical emergency in general surgery.¹ For many decades, appendectomy has been performed through an incision at McBurney's point. A limitation of this technique was the limited possibility to explore the entire abdominal cavity. Since the first description of an appendectomy performed laparoscopically in 1983,² laparoscopic appendectomy has evolved and represents now in many countries the standard technique for appendectomy.³

The conventional laparoscopic technique uses one umbilical trocar for the video camera and two others—most commonly placed suprapubic and left lower quadrant—for

dissection and retraction of tissues. The evolution from open surgery to laparoscopy has permitted to significantly improve cosmetic results, reduce the hospital stay, accelerate the patient recovery, diminish the postoperative pain, and decrease the wound infection rates. On the other hand,

Department of Visceral Surgery, University Hospital CHUV, Lausanne, Switzerland

Corresponding author:

Nicolas Demartines, Department of Visceral Surgery, University Hospital CHUV, Rue du Bugnon 46, 1011 Lausanne, Switzerland.
Email: demartines@chuv.ch

laparoscopy increases the operative time. The overall costs are, however, comparable.³

In a perspective of further improving postoperative outcome, novel less-invasive technologies have been introduced in clinical practice. Single-incision laparoscopy, that is, only one incision is performed to insert a single port containing three or four trocars, has been recently introduced. This novel technique was developed to further minimize the number of trocar orifices to access the abdominal cavity. On the other hand, the final role and clinical uses of this potentially promising new surgical approach remain to be more clearly defined.^{4,5} With the development of technology and surgical instruments, single-incision techniques to enter the abdomen have been described for various laparoscopic procedures, especially in gastrointestinal surgery (e.g. cholecystectomy, appendectomy, hernia repair, hemicolectomy, and gastric banding).^{6–8} A few studies have shown that single-incision laparoscopic appendectomy (SILA) is a feasible and safe option for appendectomy.^{9–26} However, comparisons with conventional laparoscopic appendectomy (CLA) in terms of operation time, length of hospital stay, postoperative complications, or operation difficulty remain to be undertaken to confirm what previous studies have found.^{27–31} In this study, we compared SILA (prospective cohort) to CLA (retrospective control group) using a case-match process, and we assessed the perioperative difficulty of SILA.

Methods

Patients

From February to December 2011, SILA was performed on 20 patients with uncomplicated acute appendicitis who were admitted to the emergency room of the University Hospital of Lausanne. Diagnosis was made clinically and by using different imaging techniques, that is, ultrasonography (US) and computed tomography (CT). CT, however, was mostly performed to exclude other differential diagnosis. Patients under 16 years of age, with complicated appendicitis (clinical, biological, or radiological signs of abscess, sepsis, or generalized peritonitis), with history of previous median laparotomy, or with immunodeficiencies (AIDS, corticotherapy, immunosuppressor treatment) were operated by CLA and excluded from this study. Clinical complicated appendicitis was defined by a diffuse guarding or tenderness and biological complicated appendicitis was defined by leucocytes higher than 30 G/l or C-reactive protein (CRP) higher than 100 mg/L.

All interventions were performed by five board-certified junior staff surgeons with advanced experience in minimally invasive surgery. In total, 20 patients received SILA. For these patients, various demographic, clinical, laboratory, and operative data were collected pre- and postoperatively. Age, gender, body mass index (BMI), comorbidities, American Society of Anesthesiologists (ASA) score, operative time,

length of hospital stay, complications, visual analog scale (VAS) for pain, and need for conversion to three trocars were harvested. A qualitative questionnaire was also given to the operator after every surgery to assess the difficulty of the operation. Use of Endoloop® Ligature, difficulty to introduce the trocar or to insufflate the carbon dioxide pneumoperitoneum, other problems encountered during the procedure, and need for washing were asked. Only the question on other problems encountered was an open-ended one, otherwise, all others were closed-ended questions (yes or no). A follow-up visit was performed 1 month after the operation according to our department guidelines. The local Ethics Committee of the University of Lausanne approved this study.

All the appendectomies done by conventional laparoscopy at the University Hospital of Lausanne (CHUV) between 1 January and 31 December 2010 were harvested ($n = 235$). The complicated appendicitis (clinical, biological, or radiological signs of abscess, sepsis, or generalized peritonitis), patients under 16 years of age, patients with immunodeficiencies or inflammatory bowel diseases (Crohn's disease or ulcerative colitis), and patients with history of previous median laparotomy were excluded ($n = 28$). In total, 207 patients were taken into account for the match process (Figure 1).

Surgical techniques

The operations were performed under general anesthesia with patients in supine position. The abdominal access was obtained by the use of a special trocar. TriPort® (Advanced Surgical Concepts, Bray, Ireland) is designed with three ports and an insufflating valve. A vertical 1.5-cm cutaneous and aponeurosis incision was made on the left side of the umbilicus (Hasson open technique). The TriPort trocar was then introduced in the abdominal cavity and a carbon dioxide pneumoperitoneum of 12 mmHg created. The procedure was performed with a 30° angled 5-mm diameter 60-cm length laparoscope. Conventional laparoscopic instruments, that is, straight non-flexible instruments, employed for standard laparoscopy were utilized. The standard procedure steps for appendectomy were applied. The meso-appendix was dissected along the edge of the appendix, and the specimen was ligated with an Endoloop and removed within a single-use specimen retrieval bag (Endo Catch™). The trocar was then gently removed, and the fascias were closed by 2-0 Vicryl sutures.

Case-match and statistical analysis

Each SILA patient was matched to three CLA patients by respecting the following five matching criteria: age (<40, 40–70, >70), gender (man, woman), ASA score (I, II), BMI (≤25, >25), and histological findings (normal, ulcerophlegmonous, perforated).

Continuous variables were compared and analyzed using a Mann–Whitney *U*-test, as the distribution was not Gaussian.

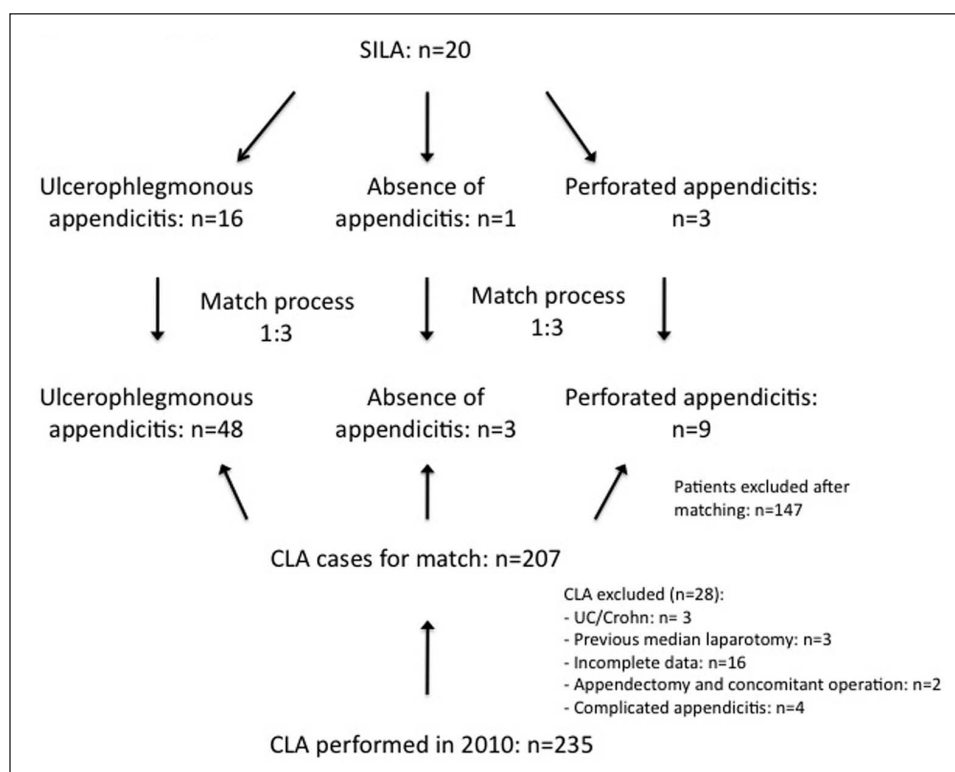


Figure 1. Selection process.

SILA: single-incision laparoscopic appendectomy; CLA: conventional laparoscopic appendectomy; UC: ulcerative colitis.

Discrete variables (categorical distribution) were interpreted using a Pearson chi-square test. A p -value < 0.05 was considered significant. All statistical analyses were performed by using GraphPad Prism 5 for Mac OS X (GraphPad Software Inc., San Diego, CA, United States).

Results

Both patient groups (SILA and CLA) were well matched regarding all five matching criteria. As histopathology was one matching criterion, there were no histological differences between the two groups. The main histological finding was an ulcerophlegmonous appendix, observed in 16 SILA patients and in 48 CLA patients (Table 1).

The operative time was calculated from the time of skin incision until wound closure. The median operative time was 55 min for the CLA group and 53 min for the SILA group. This 2-min difference was not statistically significant ($p = 0.65$). Likewise, median length of hospital stay, that is, hours spent from wound closure until discharge, was not significantly shorter with the single-incision approach ($p = 0.25$). In the SILA group, one complication occurred (wound infection) compared to six complications for CLA ($p = 0.67$). In all, 30% of SILA cases (three perforated appendices, one perioperative perforation, one long operation time due to conversion, and one elderly patient with multiple comorbidities)

and 15% of CLA patients (nine perforated appendices) received postoperative antibiotherapy ($p = 0.14$, Table 2).

For SILA patients, the mean VAS pain score was 3.6 at the postoperative ward admission and 1.7 on postoperative day 1. Endoloop Ligature was used in every appendectomy performed by single-port technique. Two SILA cases had to be converted to three-port laparoscopy. One had to be converted in order to be able to use a laparoscopic stapler and one due to impossibility of maintaining a sufficient pneumoperitoneum with the single port. The majority of SILA patients presented a localized purulent peritonitis (12 out of 20). For two patients, the single trocar was judged difficult to introduce, and in two cases, the pneumoperitoneum was insufficient. The main operative difficulty mentioned by the surgeons was the process of putting the Endoloop Ligature in place around the appendix (five cases). A pelvic washout was performed in 14 cases (Table 3).

Discussion

This current trial compared SILA to CLA by performing a 1:3 match case study. By that, we established a homogeneous patient population between the groups to reduce selection bias by matching according to age, gender, BMI, ASA score, and histological findings.

Table 1. Patient characteristics.

	SILA		CLA		p-value
Number of patients	20		60		
Median age, yrs (range)	25	(16–74)	30	(16–84)	0.62
Median weight, kg (range)	63.5	(50.0–80.0)	62.0	(45.0–95.0)	0.97
Median BMI, kg/m ² (range)	22.6	(16.9–26.1)	21.9	(18.5–31.7)	0.77
Gender (% female)	70%		70%		1.00
Histological findings					
Normal appendix	1		3		1.00
Ulcerophlegmonous appendix	16		48		1.00
Perforated appendix	3		9		1.00
ASA score (I/II)	11/9		33/27		1.00

SILA: single-incision laparoscopic appendectomy; CLA: conventional laparoscopic appendectomy; BMI: body mass index; ASA: American Society of Anesthesiologists.

Table 2. Operative and outcome data.

	SILA		CLA		p-value
Median operation time, min (range)	53	(31–122)	55	(28–158)	0.65
Median length of hospital stay, h (range)	37.7	(17.7–86.0)	40.4	(14.4–211.7)	0.25
Complications (%)	1	5%	6	10%	0.67
Wound infection	1	5%	1	2%	0.44
Operative site abscess	0		2	3%	0.44
Second-look laparoscopy	0		1	2%	0.57
Wound granuloma	0		2	3%	0.44
Postoperative antibiotherapy (%)	6	30%	9	15%	0.14

SILA: single-incision laparoscopic appendectomy; CLA: conventional laparoscopic appendectomy.

Table 3. SILA patient detailed operative and postoperative data.^a

Mean postoperative VAS at the ward admission	3.6 ± 1.4
Mean VAS postoperative day 1 (at rest)	1.7 ± 1.3
Mean VAS postoperative day 1 (when palpating the umbilicus)	2.9 ± 1.2
Use of Endoloop® Ligature/stapler	19/1
Conversion rate to three-port laparoscopy (%)	2/20 (10%)
Abdominal status	
Absence of peritonitis	7
Localized purulent peritonitis	12
Localized stercoral peritonitis	1
Operation difficulty	
Difficulty to introduce the trocar	2
Insufficient pneumoperitoneum	2
Difficult anatomical position of the appendix	2
Difficulty to put the Endoloop	5
Peroperative perforation	1
Washout	
Pelvis	14
Perihepatic	2

SILA: single-incision laparoscopic appendectomy; VAS: visual analog scale.

^aAll means are expressed ± standard deviations.

The median SILA operation time was comparable to standard laparoscopic appendectomies ($p = 0.65$). In contrast, other published trials found a longer time for the single-incision technique.^{29,30} Since our center has a particular interest in minimal invasive surgery, our results suggest that well-trained laparoscopic surgeons can perform single-port appendectomies without increasing their operation time.

We found that SILA had a similar median length of hospitalization as CLA (37.7 vs 40.4 h, $p = 0.25$), calculated from the end of the operation until discharge of the patient. Considering this outcome, SILA could become a technical alternative to CLA in selected appendicitis patients. No statistically significant differences between the two groups were noted in all the measured outcomes (i.e. operative time, length of hospital stay, complications, and postoperative antibiotherapy).

The conversion rate for SILA was low (10%). None of the SILA cases had to be converted to open surgery. One case had to be converted to three-port laparoscopic appendectomy due to technical problem. As a perioperative perforation at the base of the appendix occurred, the surgeon had to use a 12-mm stapling device to obtain a safe closure of the appendiceal stump. As the TriPort® system does not contain a 12-mm trocar, a conversion to CLA became necessary. The

other case to be converted was because of a problem with the single trocar to maintain a satisfying pneumoperitoneum. These conversions were due to instrument problems and did not happen because of the SILA technique per se.

According to the questionnaire given to the operators, SILA technique was judged as easy as CLA in terms of assessed items (trocar placement, pneumoperitoneum, Endoloop placement), even though some operative difficulties, like for instance the Endoloop® Ligature use (five surgeons judged difficult to put the Endoloop®), were mentioned. Unanimously, for the five staff surgeons who participated in this study, the loss of triangulation of the instruments and the reduced ergonomics did not affect the difficulty and feasibility of the operation.

Additionally, all means of VAS pain scores (at the ward and on postoperative day 1) for SILA were <4, corresponding to light-moderate pain according to the World Health Organization.³² Therefore, we can conclude that good analgesia was realized and that SILA did not provoke uncontrollable postoperative pain.

Until now (follow-up between 16 and 26 months), no umbilical hernias have been observed in the SILA group. A bigger umbilical incision size for the single port appears to be as safe as a conventional laparoscopy trocar orifice. This latter assertion needs to be proven by additional studies and would need a longer follow-up to detect late complications.

Wound infection and incisional hernia represent the main theoretical risks of SILA performed with a midline trocar (umbilical trocar). Available data regarding these issues are, for the moment, scarce. Nevertheless, if these presupposed risks turned out to be real, they could potentially be avoided by placing the trocar lateral to the midline or suprapubic.

SILA can be easily undertaken with conventional instruments used for standard laparoscopy. For appendectomy, it seems that the triangulation rule stipulated by conventional laparoscopy does not play a crucial role. An interesting question though would be to determine the learning curve of SILA. It seems indeed that SILA could be simple to teach, as the operative technique and the instrument manipulation are similar to CLA.

In terms of general costs, SILA could be a cost-effective alternative to CLA as the single port is cheaper than three conventional trocars, but this needs to be proven by a cost-effectiveness analysis.

The cosmetic aspect was not analyzed in our study. We have therefore no evaluation of the value of a potentially invisible scar hidden in the umbilicus fold. This aspect should be assessed with the use of a validated cosmetic score. If SILA is as safe as CLA, the esthetic perspective can be an important point to consider, especially because appendicitis occurs preponderantly in young patients for whom an invisible scar can matter.

BMI plays an important role in the decision whether or not to perform a SILA on an adult. Single-incision

technique with standard instruments appears to be more difficult in obese patients because the dissection is more complicated and fastidious. CLA seems, for obese patients, easier and more straightforward. Indeed, the instrument triangulation and a large workspace allow usually a good and safe dissection in the case where abdominal fat is abundant. However, SILA has been proven to be equivalent to CLA in children.³³

Another question about SILA concerns the feasibility and applicability of this technique to perforated appendicitis. Our study enrolled three perforated appendicitis operated by single-incision approach that showed no real additional difficulty. However, this still needs to be confirmed, and evaluation of the applicability of SILA to complicated appendicitis remains, at the moment, unknown.

Conclusion

Within the limits of a retrospective control group, our study suggests that SILA is a feasible operative technique for uncomplicated acute appendicitis.

As SILA has appeared only recently as a new instrument in the toolbox of the general surgeon, larger cohort studies or prospective randomized controlled trials assessing operation time, pain, cosmesis, and complications are needed to clarify when this technique should be used.

Acknowledgements

This article has been presented in parts at the 99th Annual Congress of the Swiss Surgical Society, 20–22 June 2012, Davos, Switzerland.

Declaration of conflicting interests

Gaëtan-Romain Joliat, Emilie Uldry, Nicolas Demartines, and Markus Schäfer have neither conflicts of interest nor financial ties to disclose.

Funding

This research received no specific grant from any funding agency in the public, commercial, or not-for-profit sectors.

References

1. Addiss DG, Schaffer N, Fowler BS, et al. The epidemiology of appendicitis and appendectomy in the United States. *Am J Epidemiol* 1990; 132(5): 910–925.
2. Semm K. Endoscopic appendectomy. *Endoscopy* 1983; 15(2): 59–64.
3. Wei B, Qi CL, Chen TF, et al. Laparoscopic versus open appendectomy for acute appendicitis: a metaanalysis. *Surg Endosc* 2011; 25(4): 1199–1208.
4. Rehman H, Rao AM and Ahmed I. Single incision versus conventional multi-incision appendectomy for suspected appendicitis. *Cochrane Database Syst Rev* 2011; 7: CD009022.
5. Komdorffer JR Jr, Fellingner E and Reed W. SAGES guideline for laparoscopic appendectomy. *Surg Endosc* 2010; 24(4): 757–761.

6. Mofid H and Zornig C. Single-access surgery laparoscopic cholecystectomy and appendectomy. *Surg Technol Int* 2010; 19: 61–64.
7. Ahmed K, Wang TT, Patel VM, et al. The role of single-incision laparoscopic surgery in abdominal and pelvic surgery: a systematic review. *Surg Endosc* 2011; 25(2): 378–396.
8. Chow A, Purkayastha S and Paraskeva P. Appendectomy and cholecystectomy using single-incision laparoscopic surgery (SILS): the first UK experience. *Surg Innov* 2009; 16(3): 211–217.
9. Raakow R and Jacob DA. Initial experience in laparoscopic single-port appendectomy: a pilot study. *Dig Surg* 2011; 28(1): 74–79.
10. Kössi J and Luostarinen M. Initial experience of the feasibility of single-incision laparoscopic appendectomy in different clinical conditions. *Diagn Ther Endosc* 2010; 2010: 240260.
11. Sesia SB, Frech M, Häcker F, et al. Laparoscopic “Single-Port” appendectomy in children. *Zentralbl Chir* 2011; 136(1): 50–55.
12. Saber AA, Elgamal MH, El-Ghazaly TH, et al. Simple technique for single incision transumbilical laparoscopic appendectomy. *Int J Surg* 2010; 8(2): 128–130.
13. Tam YH, Lee KH, Sihoe JDY, et al. A surgeon-friendly technique to perform single-incision laparoscopic appendectomy intracorporeally in children with conventional laparoscopic instruments. *J Laparoendosc Adv Surg Tech A* 2010; 20(6): 577–580.
14. Hayashi M, Asakuma M, Komeda K, et al. Effectiveness of a surgical glove port for single port surgery. *World J Surg* 2010; 34(10): 2487–2489.
15. Chouillard E, Dache A, Torcivia A, et al. Single-incision laparoscopic appendectomy for acute appendicitis: a preliminary experience. *Surg Endosc* 2010; 24(8): 1861–1865.
16. Chiu CG, Nguyen NH and Bloom SW. Single-incision laparoscopic appendectomy using conventional instruments: an initial experience using a novel technique. *Surg Endosc* 2011; 25(4): 1153–1159.
17. Feinberg EJ, O’Connor DJ, Feinberg ML, et al. Single-incision laparoscopic appendectomy: an early experience. *Am Surg* 2011; 77(3): 286–289.
18. Oltmann SC, Garcia NM, Ventura B, et al. Single-incision laparoscopic surgery: feasibility for pediatric appendectomies. *J Pediatr Surg* 2010; 45(6): 1208–1212.
19. Mayer S, Werner A, Wachowiak R, et al. Single-incision multiport laparoscopy does not cause more pain than conventional laparoscopy: a prospective evaluation in children undergoing appendectomy. *J Laparoendosc Adv Surg Tech A* 2011; 21(8): 753–756.
20. Kim HJ, Lee JI, Lee YS, et al. Single-port transumbilical laparoscopic appendectomy: 43 consecutive cases. *Surg Endosc* 2010; 24(11): 2765–2769.
21. Muensterer OJ, Puga Nougues C, Adibe OO, et al. Appendectomy using single-incision pediatric endosurgery for acute and perforated appendicitis. *Surg Endosc* 2010; 24(12): 3201–3204.
22. Vidal O, Ginestà C, Valentini M, et al. Suprapubic single-incision laparoscopic appendectomy: a nonvisible-scar surgical option. *Surg Endosc* 2011; 25(4): 1019–1023.
23. Rothenberg SS, Shipman K and Yoder S. Experience with modified single-port laparoscopic procedures in children. *J Laparoendosc Adv Surg Tech A* 2009; 19(5): 695–698.
24. Shekherdimian S and DeUgarte D. Transumbilical laparoscopic-assisted appendectomy: an extracorporeal single-incision alternative to conventional laparoscopic techniques. *Am Surg* 2011; 77(5): 557–560.
25. Garey CL, Laituri CA, Ostlie DJ, et al. Single-incision laparoscopic surgery in children: initial single-center experience. *J Pediatr Surg* 2011; 46(5): 904–907.
26. Dutta S. Early experience with single incision laparoscopic surgery: eliminating the scar from abdominal operations. *J Pediatr Surg* 2009; 44(9): 1741–1745.
27. Cho M, Min BS, Hong Y, et al. Single-site versus conventional laparoscopic appendectomy: comparison of short-term operative outcomes. *Surg Endosc* 2011; 25(1): 36–40.
28. St Peter SD, Adibe OO, Juang D, et al. Single incision versus standard 3-port laparoscopic appendectomy: a prospective randomized trial. *Ann Surg* 2011; 254(4): 586–590.
29. Frutos MD, Abrisqueta J, Lujan J, et al. Randomized prospective study to compare laparoscopic appendectomy versus umbilical single-incision appendectomy. *Ann Surg* 2013; 257(3): 413–418.
30. Soztek A, Colak T, Dirlik M, et al. A prospective randomized comparison of single-port laparoscopic procedure with open and standard 3-port laparoscopic procedures in the treatment of acute appendicitis. *Surg Laparosc Endosc Percutan Tech* 2013; 23(1): 74–78.
31. Kye BH, Lee J, Kim W, et al. Comparative study between single-incision and three-port laparoscopic appendectomy: a prospective randomized trial. *J Laparoendosc Adv Surg Tech A* 2013; 23(5): 431–436.
32. Ventafridda V, Saita L, Ripamonti C, et al. WHO guidelines for the use of analgesics in cancer pain. *Int J Tissue React* 1985; 7(1): 93–96.
33. Petnehazy T, Saxena AK, Ainoedhofer H, et al. Single-port appendectomy in obese children: an optimal alternative? *Acta Paediatr* 2010; 99(9): 1370–1373.