

Glial Tau Pathology in Tauopathies: Functional Consequences

Supplementary Issue: Molecular and Cellular Mechanisms of Neurodegeneration

Martha A. Kahlson and Kenneth J. Colodner

Department of Neuroscience and Behavior, Mount Holyoke College, South Hadley, MA, USA.

ABSTRACT: Tauopathies are a class of neurodegenerative diseases characterized by the presence of hyperphosphorylated and aggregated tau pathology in neuronal and glial cells. Though the ratio of neuronal and glial tau aggregates varies across diseases, glial tau aggregates can populate the same degenerating brain regions as neuronal tau aggregates. While much is known about the deleterious consequences of tau pathology in neurons, the relative contribution of glial tau pathology to these diseases is less clear. Recent studies using a number of model systems implicate glial tau pathology in contributing to tauopathy pathogenesis. This review aims to highlight the functional consequences of tau overexpression in glial cells and explore the potential contribution of glial tau pathology in the pathogenesis of neurodegenerative tauopathies.

KEYWORDS: tau, tauopathy, glial tau pathology, functional consequences, neurodegeneration, astrocytes, oligodendrocytes, microglia

SUPPLEMENT: Molecular and Cellular Mechanisms of Neurodegeneration

CITATION: Kahlson and Colodner. Glial Tau Pathology in Tauopathies: Functional Consequences. *Journal of Experimental Neuroscience* 2015:9(S2) 43–50 doi:10.4137/JEN.S25515.

TYPE: Review

RECEIVED: August 24, 2015. **RESUBMITTED:** December 21, 2015. **ACCEPTED FOR PUBLICATION:** December 29, 2015.

ACADEMIC EDITOR: Lora Talley Watts, Editor in Chief

PEER REVIEW: Three peer reviewers contributed to the peer review report. Reviewers' reports totaled 935 words, excluding any confidential comments to the academic editor.

FUNDING: Authors disclose no external funding sources.

COMPETING INTERESTS: Authors disclose no potential conflicts of interest.

COPYRIGHT: © the authors, publisher and licensee Libertas Academica Limited. This is an open-access article distributed under the terms of the Creative Commons CC-BY-NC 3.0 License.

CORRESPONDENCE: kcolodne@mtholyoke.edu

Paper subject to independent expert blind peer review. All editorial decisions made by independent academic editor. Upon submission manuscript was subject to anti-plagiarism scanning. Prior to publication all authors have given signed confirmation of agreement to article publication and compliance with all applicable ethical and legal requirements, including the accuracy of author and contributor information, disclosure of competing interests and funding sources, compliance with ethical requirements relating to human and animal study participants, and compliance with any copyright requirements of third parties. This journal is a member of the Committee on Publication Ethics (COPE).

Published by Libertas Academica. Learn more about this journal.

Introduction

Tauopathies are a class of >20 sporadic and familial neurodegenerative diseases characterized by aggregates of tau protein in the brain's neuronal and glial cells.^{1,2} These include, but are not limited to, progressive supranuclear palsy (PSP), corticobasal degeneration (CBD), Pick's disease (PiD), argyrophilic grain disease (AGD), frontotemporal dementia and parkinsonism linked to chromosome 17 (FTDP-17), and globular glial tauopathy (GGT), in addition to Alzheimer's disease (AD), the most common neurodegenerative dementia. While AD shows predominantly neuronal tau pathology in the form of neurofibrillary tangles, most other tauopathies are characterized by the presence of both neuronal and glial tau pathologies.^{3–5}

Tau is a low molecular weight microtubule-associated protein (MAP), abundant in the central and peripheral nervous systems, which stabilizes microtubules and promotes their assembly.⁶ Human tau is encoded by a single gene on chromosome 17, and alternative splicing of its mRNA transcript produces six different protein isoforms. These isoforms can contain either three (3R) or four (4R) microtubule-binding repeats in the carboxy-terminal half, and between zero and two (0–2N) amino-terminal inserts.^{7–9} Mutations in the *MAPT* gene, which encodes the tau protein, are predominantly associated with frontotemporal dementia and parkinsonism linked to chromosome 17 (FTDP-17 *MAPT*),^{10,11} though *MAPT*

mutations have also been observed in cases of PiD^{12–14} and GGT.¹⁵ These genetic studies demonstrate that tau mutations are sufficient to cause tauopathies and directly implicate tau dysfunction as a primary pathogenic event in neurodegenerative disease.

In the healthy brain, tau is predominantly expressed in neurons, where it localizes to axons to promote axonal transport and neuronal integrity.¹⁶ To a lesser extent, tau localizes to dendrites where it targets factors that modulate postsynaptic receptor activity.^{16,17} Tau is also expressed at lower levels in glial cells. Oligodendrocytes are rich in microtubules and express tau mainly in the cell soma and cellular processes, where it appears to play a role in establishing early axonal contact, in stabilizing microtubules during process formation, and in myelination.^{18–22} Tau is found at trace levels in astrocytes and does not appear to be a major astrocytic cytoskeletal element.^{21,23} Microglia contain microtubule networks,²⁴ but whether tau is normally present in these glial cells remains unclear. While tau expression is variable among glial cells in the normal brain, the pathological accumulation of tau in glial cells is a common feature of many tauopathies.

Characteristics of Glial Tau Pathology

In tauopathies, glial tau pathology is often found alongside neuronal tau pathology; however, their ratio varies across diseases. For example, in AD, the majority of tau pathology



is neuronal, while in other tauopathies tau pathology ranges from moderately to predominantly glial.^{3,25,26} The majority of glial tau pathology observed in tauopathy brains occurs in oligodendrocytes and astrocytes,^{4,27,28} though tau pathology is also seen in microglia.^{27,28}

Tau pathology in oligodendrocytes varies in size and morphology across tauopathies, with the most prevalent lesion being tau-positive cytoplasmic inclusions termed coiled bodies. These filamentous and tubular structures, prominent in PSP, CBD, PiD, and other tauopathies, display diverse morphologies such as fine and branching in PSP and thick and comma-like in CBD.^{4,5,29} Another type of oligodendrocytic tau pathology, argyrophilic threads, is found in the inner and outer loop processes of myelinating oligodendrocytes in PSP and CBD.^{4,29} Finally, globular glial inclusions, tau-positive structures that are equal or greater in size than oligodendrocytic nuclei, are a prominent feature of GGT.^{30,31}

Oligodendrocytic tau pathology is often concomitant with astrocytic tau pathology in diseased brains. Some of these tau-positive astrocytic lesions are a common feature among several tauopathies, while other lesions are characteristic of a single disorder. Thorn-shaped astrocytes are short, tau-positive perinuclear deposits commonly localized to the subpial region, periventricular white matter, and temporal lobe white matter.^{4,32–34} These tau-bearing cells are found in several tauopathies, including PSP, AGD, PiD, and combined tauopathies, and in the elderly with and without AD-related pathology. In contrast to the relatively common thorn-shaped astrocyte, astrocytic plaques, annular tau deposits in distal astrocytic processes, are pathognomonic for CBD.^{35,36} Similarly, tufted astrocytes, tau-positive inclusions characterized by densely packed fibrils that form tufts in the proximal processes surrounding astrocytic nuclei, are the pathological signature of PSP.^{3,37,38} Other morphologies include globular astroglial inclusions found in GGT and diffuse fine granular tau immunopositivity in astrocytic processes of elderly patients, which are similar to bush-like astrocytes in AGD.³⁹

Astrocytes are typically classified into two major subtypes, protoplasmic and fibrous, which are distinguished by different molecular profiles and morphologies and by their distribution in the gray and white matter, respectively.⁴⁰ Some of the diversity of astrocytic tau lesions may correspond to particular astrocyte subtypes. For example, in PiD, two types of astrocytic tau pathologies are present. The first type, ramified astrocytes with tau-positive processes, is believed to be tau deposits in protoplasmic astrocytes, given their localization to cortical gray matter. The second form, tau-positive astrocytic lesions that resemble small Pick body-like inclusions, are believed to be tau deposits in fibrous astrocytes as they are prominent in white matter.^{3,4} Similarly, thorn-shaped astrocytes, given their morphology and white matter localization, are thought to represent tau accumulation in fibrous astrocytes,⁴ whereas astrocytic plaques and tufted astrocytes are believed to be protoplasmic

in nature as they are found in gray matter and display CD44 immunoreactivity, with less-intense glial fibrillary acidic protein (GFAP) reactivity.^{4,35} The significance of each astrocytic subtype in regulating the formation of these distinct astrocytic tau pathologies remains to be defined.

Glial tau pathology can be characterized further by its ultrastructural and biochemical properties, which varies across tauopathies. Ultrastructurally, glial tau inclusions typically consist of straight tubules/filaments and/or twisted filaments^{4,29} that mimic the coincident neuronal tau inclusions within individual diseased brains.²⁹ Biochemically, glial tau aggregates are generally composed of 3R and 4R tau isoforms in tauopathy-associated patterns, with some exceptions. PSP, CBD, GGT, and AGD are 4R tauopathies, and these diseases contain predominantly 4R glial tau pathology, though 3R-containing glial tau inclusions have been noted.⁴¹ While PiD is a 3R tauopathy, some glial tau-positive inclusions have been shown to contain 4R tau.¹³ FTDP-17 *MAPT* can be characterized by tau inclusions that are 4R predominant, 3R predominant, or a mixture of 3R/4R, depending on the *MAPT* mutation.^{39,42} The glial tau inclusions in these cases vary, but cases of 4R predominant lesions have been described.^{26,43} Interestingly, the differentially spliced N-terminal exon 3 is often absent from glial tau tangles.^{44–46} In summary, glial tau pathology displays diverse cellular and biochemical characteristics and is prominent in tauopathy brains.

Glial Tau Pathology and Reactive Gliosis

Glial cells have long been associated with neurological disease through the morphological and molecular changes seen in astrocytes and microglia in response to brain disease and injury.^{47,48} These changes, termed reactive gliosis, are characterized by an upregulation in the intermediate filament protein GFAP in astrocytes and a transition from resting to activated state in microglia.^{47,48} Reactive astrocytes and microglia are routinely implicated as secondary effectors of toxicity, often through the release of proinflammatory cytokines, but they have also proven protective in some contexts.^{48,49}

Tauopathies display widespread reactive gliosis in affected brain regions, and astrocytic and microglial activation correlate closely with regions of degeneration.^{50,51} For astrocytes, it appears that the relationship between tau pathology and astrocyte activation varies; some astrocytic tau structures appear to be related to reactive gliosis, while others appear to be independent. For example, thorn-shaped astrocytes morphologically resemble reactive astrocytes, and their presence in several tauopathies suggests that they represent a more general pathological response that would be consistent with reactive gliosis.³² Tau-bearing cells with reactive astrocytic morphology are also a feature of PiD.⁵² On the other hand, an examination of tufted astrocytes and reactive gliosis in postmortem PSP brain found that the distribution of tufted astrocytes did not correlate with the density of reactive gliosis.⁵¹ Furthermore, in PSP cases with vascular infarcts or Alzheimer-type

pathology, the presence of tufted astrocytes was independent of the gliosis surrounding areas of focal vascular and plaque lesions.⁵¹ This spatial distribution of tufted astrocytes suggests that these astrocytic tau lesions are pathologically independent of the reactive gliotic process. The extent to which other astrocytic tau lesions relate to reactive gliosis has not been determined.

For microglia, the relationship between microglial tau pathology and the reactive gliotic process remains to be established, but there is evidence to suggest that a relationship exists. In tauopathy brains, tau-positive microglia (identified with Tau-2 antibody) were found exclusively in activated microglia,²⁷ though tau-positive microglia (identified with Tau-66 antibody) in resting/unreactive microglia have been reported.²⁸ Moreover, transfection of the longest isoform of human tau into cultured microglial cells activates microglia.⁵³ Reactive microglia have recently been shown to drive tau pathology in neurons⁵⁴ and participate in the spread of tau pathology,⁵⁵ underscoring the importance of understanding how microglial tau pathology and reactive microglia are related.

Functional Consequences of Glial Tau Pathology

Glial cells play an essential role in an array of functions in the normal brain,⁵⁶ and the presence of tau in glial cells has been shown to disrupt these functionalities. Most of the evidence to suggest that glial tau pathology has adverse consequences on brain function have come from transgenic models where tau is specifically overexpressed in astrocytes and/or oligodendrocytes.

Astrocytes play a key role in maintaining the blood–brain barrier (BBB) via astrocytic end feet directly apposed to vascular endothelial cells,⁵⁷ and tau has been shown to accumulate in these end feet in tauopathies.^{4,32} Targeted expression of human wild-type (WT) tau in murine astrocytes results in mild BBB disruption in aged mice, suggesting that tau interferes with the astrocyte's ability to properly maintain the BBB and implicates astrocytic tau pathology in tauopathy-associated BBB dysfunction.^{58,59} Moreover, recent experiments in an inducible model of neuronal tauopathy demonstrate that tau-induced BBB disruption can be mitigated by turning off tau expression, but the specific contribution of astrocytes was not investigated.⁶⁰ Therefore, additional experiments specifically addressing the contribution of astrocytic tau pathology to BBB integrity are necessary.

In addition to maintaining BBB integrity, astrocytes also modulate synaptic function by the secretion and uptake of neurotransmitters such as glutamate, the brain's major excitatory neurotransmitter.⁶¹ Glutamate transporters on astrocytes are responsible for the bulk of glutamate clearance, with glutamate transporter-1 (GLT-1) accounting for up to 95% of glutamate uptake.^{62–64} Astrocytic glutamate transport plays a role in long-term potentiation induction and synaptic plasticity,⁶⁵ and impaired glutamate clearance can be deleterious to brain cells

via overactivation of glutamate receptors. This overactivation can lead to calcium-dependent excitotoxicity, a process implicated in the pathogenesis of a number of neurodegenerative diseases, including tauopathies.⁶² In mice expressing either WT or FTDP-17 mutant tau in astrocytes, the presence of tau was shown to significantly reduce expression of glial glutamate transporters and decrease glutamate transport capacity.⁶⁶ This finding is consistent with a recent description of a frontotemporal dementia variant that displayed reduced GLT-1 staining in a subset of tau-bearing astrocytes.²⁵ Reduced glutamate transport is also a prominent feature of amyotrophic lateral sclerosis (ALS), a disease with significant clinical and pathological overlap with FTD, including tau pathology in glial cells.⁶⁷ While glial cells appear to play an active role in the pathogenesis of ALS,⁶⁸ the extent to which astrocytic tau pathology influences glutamate transport and the pathogenesis of ALS has not been explored. These studies suggest that astrocytic tau pathology can reduce glutamate uptake, and this altered glutamate buffering capacity may contribute to tauopathy disease progression.

The overexpression of tau has also been shown to affect oligodendrocyte function. Oligodendrocytes myelinate axons in the white matter of the central nervous system, and proper myelination is critical for normal brain physiology. Tauopathy brains are characterized by prominent white matter pathology, with abundant oligodendrocytic tau lesions,^{2,69} and evidence suggests that oligodendrocytic tau pathology has the capacity to disrupt myelin sheath maintenance. Targeted expression of FTDP-17 mutant tau to oligodendrocytes results in age-dependent disruption of myelin integrity, characterized by myelin fragmentation and atrophy.⁷⁰ These morphological changes correlate with a reduction in both fast and slow axonal transport and age-dependent motor deficits, underscoring the importance of oligodendrocytes and proper myelin maintenance for normal physiological function.⁷⁰ The capacity for oligodendrocytic tau to influence axonal transport dynamics in neurons may thus contribute to the impaired axonal transport implicated in tauopathies.⁷¹

Glial cells play an active role in maintaining neuronal survival,⁵⁶ and tau can impair this functionality. Glial-expressed tau has been shown to exert toxicity via both non-cell-autonomous alterations in neurons and cell-autonomous effects in glial cells. The expression of human tau in murine astrocytes or oligodendrocytes, *in vivo*, each leads to neurodegenerative changes in neurons,^{72,73} while the expression of human tau in *Drosophila* astrocytes and ensheathing glial cells results in neuronal death.⁷⁴ The capacity for glial tau expression to affect neuronal viability may be related to the cell-autonomous effects of tau on glial cell viability. In culture, overexpression of the longest human tau isoform in rat astrocytes leads to cytoskeletal collapse and astrocytic death.⁷⁵ These degenerative changes are accompanied by the accumulation of tau at distal processes that resemble CBD-associated astrocytic plaques.^{35,72} Similarly,

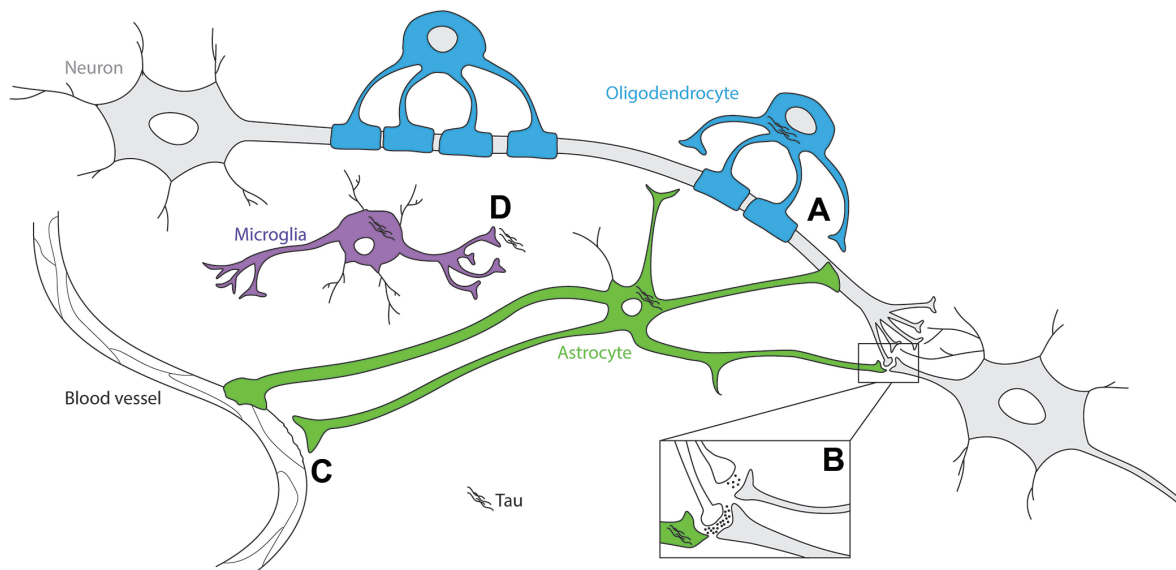


Figure 1. Schematic of functional consequences associated with tau pathology in glial cells. Tau overexpression disrupts oligodendrocyte (blue) and astrocyte (green) physiology and has been shown to lead to deficits in (A) myelin sheath integrity, (B) glutamate buffering at the synapse, and (C) maintenance of the BBB. These consequences are associated with neuronal degenerative changes and neuronal death. (D) Microglial cells (purple) have been shown to contribute to the spread of tau pathology across brain regions.

the expression of WT and FTDP-17 mutant tau in cultured oligodendrocytes results in oligodendrocytic cell death.⁷⁶ The gliotoxic nature of tau is also demonstrated, *in vivo*, in *Drosophila* expressing tau in glial cells.⁷⁴ While astrocytic and oligodendrocytic cell death has been documented in AD and related tauopathies,^{77–79} the role that tau plays, if any, in this cell death has not been established. Conversely, neuronal expression of human mutant tau in mice induces oligodendrocytic cell death,⁸⁰ underscoring the reciprocal importance of neuronal–glial communication. In *Drosophila* tauopathy models, tau is toxic when expressed in either glial cells or neuronal cells individually,^{74,81} and coexpression of tau in both neuronal and glial cells reveals a synergistic enhancement of cell death.⁷⁴ Given the coexistence of neuronal and glial tau pathologies in tauopathy brains, further examination of how coincident neuronal and glial tau expressions affect the disease process is warranted.

Studies overexpressing tau in microglial cells, *in vivo*, have not been reported, though transfection of the longest isoform of human tau into cultured microglial cells results in increased microglial activation, migration, and phagocytosis.⁵³ How tau may be altering microglial cell function is largely unexplored, but microglia have recently been shown to be active participants in the pathological spread of tau pathology.⁵⁵ While tau propagation appears to follow paths dictated by neuronal connectivity,⁸² activated microglia drive tau pathology formation⁵⁴ and actively propagate tau via exosome secretion.⁵⁵ Astrocytes and oligodendrocytes are also recipients of spreading tau pathology in a tauopathy-specific fashion,^{83,84} but the functional significance of propagated glial tau lesions remains to be established.

In summary, the presence of tau in glial cells has the capacity to disrupt a variety of normal glial cell functions leading to an array of deleterious consequences (Fig. 1). Any of these consequences has the potential to contribute to tauopathy pathogenesis.

Potential Mechanisms of Glial Tau Toxicity

Investigations into the mechanisms by which tau promotes toxicity have been performed predominantly in neuronal systems (reviewed in Refs. 1, 85), and studies have shown that some of these mechanisms also apply to tau-mediated toxicity in glial cells. Of the numerous factors that promote tau toxicity in neurons, there are three areas that appear to be particularly relevant to tau toxicity in glial cells: tau aggregation, cytoskeletal perturbations, and altered gene transcription.

Tau aggregation. The aggregation of hyperphosphorylated tau is a defining feature of all tauopathies. This aggregation is characterized by the progression from soluble monomeric tau species to intermediate dimer/trimers and soluble oligomers, and finally into insoluble tau filaments and tangles. The aggregation process and the factors that influence its kinetics have been the subject of extensive research, and the relationship between the various tau species and toxicity is still a matter of debate (reviewed in Refs. 86, 87). However, recent studies suggest that soluble oligomeric tau species may represent a more toxic species in comparison with insoluble tau tangles.⁸⁸ These toxic properties have been identified primarily in experiments expressing tau in neurons, but similar findings have been described in systems overexpressing tau in glial cells. For example, the *Drosophila* glial tauopathy model, which displays glial tau tangles concomitant with cell death,

used an inducible expression system to dissociate insoluble tau tangle formation from toxicity. In this study, glial tau expression was shut off at the onset of toxicity, which was sufficient in suppressing additional glial cell death, while the number of insoluble glial tau tangles was unaffected.⁷⁴ Consistent with experiments performed using a similar inducible approach in neuronal models,⁸⁹ this study suggests that the tangles themselves are most likely not the toxic tau species and implicates smaller soluble oligomeric tau moieties in promoting tau toxicity in glial cells.

Interestingly, phosphorylation of tau has been shown to promote and inhibit aggregation, depending on the specific residue phosphorylated, and phosphorylation is an important factor in promoting neuronal tau toxicity in neuronal tau transgenic models.^{90,91} Less is known about the specific pathological contribution of tau phosphorylation to toxicity in glial cells; however, in murine and *Drosophila* glial tau transgenic models, human tau is phosphorylated at tauopathy-associated epitopes and localizes to areas of degeneration.^{70,72,74} Although these studies demonstrate that both mouse and fly glial kinases are capable of phosphorylating human tau, definitive evidence demonstrating an essential role for phosphorylation in mediating tau toxicity in glial cells has yet to be established. Future experiments using tau constructs that mimic and prevent phosphorylation would help assist in this endeavor and might yield valuable insights given the considerable diversity among tauopathies in the phosphorylation profile of glial tau aggregates.²⁶

Regardless of which tau species is the primary toxic moiety, the pathological accumulation of tau in glial cells implies a dysfunction in the protein regulatory systems tasked with handling misfolded proteins: the ubiquitin/proteasome, autophagy, and chaperone systems. There is evidence to suggest that impairment in each of these systems may contribute to glial tau accumulation. In tauopathy brains, glial tau aggregates are variably ubiquitinated,²⁶ implying a dysfunction in the ubiquitin/proteasome degradation pathway. Moreover, in cultured oligodendrocytes, inhibition of ubiquitin-dependent pathway enzymes and the proteasome were both shown to result in tau aggregation.⁹²

Dysfunction in the autophagy system may also contribute to tau aggregation in glial cells, as inhibition of the histone deacetylase, HDAC6, in cultured oligodendrocytes was found to compromise aggregates formation and alter tau aggregation.⁹³ Inhibition of HDAC6 resulted in elevated acetylated tau levels and slower tau degradation,⁹⁴ similar to how acetylation regulates tau degradation in neurons.⁹⁵ These findings linking acetylation to tau degradation are noteworthy, as acetylated tau is a feature of glial tau pathology in human tauopathies.⁹⁶

The final protein regulatory system whose dysfunction is implicated in the pathological accumulation of tau is the chaperone system, the cellular machinery responsible for refolding misfolded proteins and preventing their abnormal

accumulation. One family of chaperone proteins, heat-shock proteins (HSPs), are synthesized at higher levels in response to cellular stress and can directly interact with tau to promote its degradation.⁹⁷ Glial cells constitutively express high levels of HSPs in normal physiological states and show a dramatic increase in inducible HSPs upon cellular stress and disease.⁹⁸ A number of immunohistochemical studies have indicated that HSPs are generally upregulated in glial cells of human tauopathy brains, but only a fraction of glial tau tangles are positive for HSPs.^{98–101} In these cases, many HSP-positive cells lack tau pathology, suggesting that the disease-associated upregulation of HSPs may antagonize aggregate formation. Moreover, the accumulation of tau in neuronal cells induces HSP upregulation in astrocytes,¹⁰² underscoring the role of neuronal–glial communication in regulating glial chaperone expression.

These studies implicate dysfunction of one or more protein regulatory systems in the pathological formation of glial tau aggregates, but the extent to which the potentially toxic oligomeric tau species and/or phosphorylation is regulated by these systems remains to be established.

Cytoskeletal perturbations. Cell culture systems have found that the overexpression of tau in glial cells induces toxicity via tau-mediated cytoskeletal disruption. In primary rat astrocytes, the overexpression of human tau is toxic, and astrocytic cell death is characterized by selective destruction of detyrosinated microtubules and collapse of the intermediate filament network.⁷⁵ Similarly, oligodendrocytes derived from oligodendrocytic tau transgenic mice displayed thin microtubules and a defective microtubule network before dying.⁷⁶ This destabilization of microtubules is associated with a decrease in the levels of the motor protein kinesin,⁷⁵ which is integral to the trafficking of vesicles, mitochondria, and RNA.^{18,103} In oligodendrocytes, tau likely plays a role in the microtubule- and kinesin-dependent translocations of myelin basic protein mRNA, a crucial component for axon myelination,¹⁰⁴ and perturbations in this translocation might thus contribute to the myelination abnormalities seen in oligodendrocytic tau transgenic mice.⁷⁰ Impaired intracellular transport is associated with neuronal dysfunction and believed to contribute to neurodegeneration,⁷¹ and this evidence suggests that tau-mediated cytoskeletal disruption in glial cells may lead to similar impairments of a range of vital cellular processes.

Altered gene transcription. A novel mechanism of tau toxicity has recently been identified, whereby tau promotes toxicity in neurons via oxidative stress-induced chromatin relaxation, which results in the aberrant expression of normally silenced genes.¹⁰⁵ An analogous effect of tau on glial chromatin relaxation was not investigated, but transcriptional alterations in glia have been observed in tauopathy brains and glial transgenic flies. Splicing factor proline/glutamine rich (SFPQ), a nuclear splicing factor and transcriptional regulator, was found to be dramatically depleted from nuclei of astrocytes (and neurons) in AD-affected brain areas,¹⁰⁶



suggesting that SFPQ activity is reduced in diseased astrocytes. In the *Drosophila* model of glial tauopathy, the overexpression of tau in glial cells results in the reduction of another transcription factor, the signal transducer and activator of transcription.⁷⁴ The specific genes that are affected by both these transcriptional alterations remain to be established. Tau-induced chromatin relaxation in neurons is mediated by oxidative stress, and oxidative stress-related markers have been identified in tauopathy glial cells. Inducible nitric oxide synthase is an enzyme that synthesizes nitric oxide, a signaling molecule that can be scavenged by superoxide to form the highly reactive peroxynitrite, a promoter of oxidative stress.¹⁰⁷ Both PSP and AD glial cells display elevated levels of inducible nitric oxide synthase,^{108,109} suggesting the presence of peroxynitrite¹⁰⁹ and oxidative stress-related dysfunction in glial cells.

Summary

A number of glial tau transgenic model systems in cell culture, mouse, and *Drosophila* have shown that the overexpression of human tau in glial cells results in the formation of hyperphosphorylated and aggregated tau moieties that immunohistochemically and ultrastructurally resemble the glial tau pathology found in human tauopathies. Investigations into the pathological significance of these tau species have revealed that the overexpression of human tau has deleterious effects on a variety of glial cell functions such as glutamate transport, BBB and myelin maintenance, and neuronal and glial cell survival. These functional consequences appear to be associated, in part, with tau-induced cytoskeletal perturbations, altered transcription factor activity, and improper management of aggregated tau, but specific links between these mechanisms and glial cell dysfunction remain to be determined. There is still much to learn about how tau may be exerting toxicity in glial cells and, specifically, to what extent glial tau-mediated mechanisms of toxicity are similar to those in neurons, or if there are glial-specific pathways. Mechanistic inquiries into how glial tau accumulation adversely affects brain physiology are therefore warranted, as the pathological significance of glial tau pathology continues to be characterized in tauopathy disease progression.

Acknowledgments

We would like to thank Dr. Mel Feany for her comments and Bryan Miller for assistance in creating Figure 1.

Author Contributions

Conceived the concepts: MAK and KJC. Analyzed the data: MAK and KJC. Wrote the first draft of the manuscript: MAK and KJC. Contributed to the writing of the manuscript: MAK and KJC. Agree with manuscript results and conclusions: MAK and KJC. Jointly developed the structure and arguments for the paper: MAK and KJC. Made critical revisions and approved final version: MAK

and KJC. Both author reviewed and approved of the final manuscript.

REFERENCES

- Ballatore C, Lee VM, Trojanowski JQ. Tau-mediated neurodegeneration in Alzheimer's disease and related disorders. *Nat Rev Neurosci*. 2007;8(9):663–672.
- Chin SS, Goldman JE. Glial inclusions in CNS degenerative diseases. *J Neuropathol Exp Neurol*. 1996;55(5):499–508.
- Feany MB, Dickson DW. Neurodegenerative disorders with extensive tau pathology: a comparative study and review. *Ann Neurol*. 1996;40(2):139–148.
- Komorí T. Tau-positive glial inclusions in progressive supranuclear palsy, corticobasal degeneration and Pick's disease. *Brain Pathol*. 1999;9(4):663–679.
- Williams DR. Tauopathies: classification and clinical update on neurodegenerative diseases associated with microtubule-associated protein tau. *Intern Med J*. 2006;36(10):652–660.
- Weingarten MD, Lockwood AH, Hwo SY, Kirschner MW. A protein factor essential for microtubule assembly. *Proc Natl Acad Sci U S A*. 1975;72(5):1858–1862.
- Goedert M, Spillantini MG, Davies SW. Filamentous nerve cell inclusions in neurodegenerative diseases. *Curr Opin Neurobiol*. 1998;8(5):619–632.
- Iqbal K, Liu F, Gong CX, Alonso Adel C, Grundke-Iqbal I. Mechanisms of tau-induced neurodegeneration. *Acta Neuropathol*. 2009;118(1):53–69.
- Richter-Landsberg C, Bauer NG. Tau-inclusion body formation in oligodendroglia: the role of stress proteins and proteasome inhibition. *Int J Dev Neurosci*. 2004;22(7):443–451.
- Hutton M, Lendon CL, Rizzu P, et al. Association of missense and 5'-splice-site mutations in tau with the inherited dementia FTDP-17. *Nature*. 1998;393(6686):702–705.
- Poorakaj P, Bird TD, Wijsman E, et al. Tau is a candidate gene for chromosome 17 frontotemporal dementia. *Ann Neurol*. 1998;43(6):815–825.
- Bronner IF, ter Meulen BC, Azmani A, et al. Hereditary Pick's disease with the G272V tau mutation shows predominant three-repeat tau pathology. *Brain*. 2005;128(pt 11):2645–2653.
- Hogg M, Grujic ZM, Baker M, et al. The L266V tau mutation is associated with frontotemporal dementia and Pick-like 3R and 4R tauopathy. *Acta Neuropathol*. 2003;106(4):323–336.
- Murrell JR, Spillantini MG, Zolo P, et al. Tau gene mutation G389R causes a tauopathy with abundant pick body-like inclusions and axonal deposits. *J Neuropathol Exp Neurol*. 1999;58(12):1207–1226.
- Tacik P, DeTure M, Lin WL, et al. A novel tau mutation, p.K317N, causes globular glial tauopathy. *Acta Neuropathol*. 2015;130(2):199–214.
- Binder LI, Frankfurter A, Rebhun LI. The distribution of tau in the mammalian central nervous system. *J Cell Biol*. 1985;101(4):1371–1378.
- Ittner LM, Ke YD, Delerue F, et al. Dendritic function of tau mediates amyloid-beta toxicity in Alzheimer's disease mouse models. *Cell*. 2010;142(3):387–397.
- Gorath M, Stahnke T, Mronga T, Goldbaum O, Richter-Landsberg C. Developmental changes of tau protein and mRNA in cultured rat brain oligodendrocytes. *Glia*. 2001;36(1):89–101.
- Klein C, Kramer EM, Cardine AM, Schraven B, Brandt R, Trotter J. Process outgrowth of oligodendrocytes is promoted by interaction of fyn kinase with the cytoskeletal protein tau. *J Neurosci*. 2002;22(3):698–707.
- LoPresti P, Zsuzhet S, Papasozomenos SC, Zinkowski RP, Binder LI. Functional implications for the microtubule-associated protein tau: localization in oligodendrocytes. *Proc Natl Acad Sci U S A*. 1995;92(22):10369–10373.
- Muller R, Heinrich M, Heck S, Blohm D, Richter-Landsberg C. Expression of microtubule-associated proteins MAP2 and tau in cultured rat brain oligodendrocytes. *Cell Tissue Res*. 1997;288(2):239–249.
- Seiberlich V, Bauer NG, Schwarz L, Ffrench-Constant C, Goldbaum O, Richter-Landsberg C. Downregulation of the microtubule associated protein Tau impairs process outgrowth and myelin basic protein mRNA transport in oligodendrocytes. *Glia*. 2015;63(9):1621–1635.
- Papasozomenos SC, Binder LI. Phosphorylation determines two distinct species of Tau in the central nervous system. *Cell Motil Cytoskeleton*. 1987;8(3):210–226.
- Ilshner S, Brandt R. The transition of microglia to a ramified phenotype is associated with the formation of stable acetylated and detyrosinated microtubules. *Glia*. 1996;18(2):129–140.
- Ferrer I, Legati A, Garcia-Monco JC, et al. Familial behavioral variant frontotemporal dementia associated with astrocyte-predominant tauopathy. *J Neuropathol Exp Neurol*. 2015;74(4):370–379.
- Ferrer I, Lopez-Gonzalez I, Carmona M, et al. Glial and neuronal tau pathology in tauopathies: characterization of disease-specific phenotypes and tau pathology progression. *J Neuropathol Exp Neurol*. 2014;73(1):81–97.
- Odawara T, Iseki E, Kosaka K, Akiyama H, Ikeda K, Yamamoto T. Investigation of tau-2 positive microglia-like cells in the subcortical nuclei of human neurodegenerative disorders. *Neurosci Lett*. 1995;192(3):145–148.

28. Ghoshal N, Garcia-Sierra F, Fu Y, et al. Tau-66: evidence for a novel tau conformation in Alzheimer's disease. *J Neurochem*. 2001;77(5):1372–1385.
29. Arima K. Ultrastructural characteristics of tau filaments in tauopathies: immuno-electron microscopic demonstration of tau filaments in tauopathies. *Neuropathology*. 2006;26(5):475–483.
30. Ahmed Z, Bigio EH, Budka H, et al. Globular glial tauopathies (GGT): consensus recommendations. *Acta Neuropathol*. 2013;126(4):537–544.
31. Kovacs GG, Majtenyi K, Spina S, et al. White matter tauopathy with globular glial inclusions: a distinct sporadic frontotemporal lobar degeneration. *J Neuropathol Exp Neurol*. 2008;67(10):963–975.
32. Ikeda K, Akiyama H, Kondo H, et al. Thorn-shaped astrocytes: possibly secondarily induced tau-positive glial fibrillary tangles. *Acta Neuropathol*. 1995;90(6):620–625.
33. Schultz C, Ghebremedhin E, Del Tredici K, Rub U, Braak H. High prevalence of thorn-shaped astrocytes in the aged human medial temporal lobe. *Neurobiol Aging*. 2004;25(3):397–405.
34. Tolnay M, Sergeant N, Ghestem A, et al. Argyrophilic grain disease and Alzheimer's disease are distinguished by their different distribution of tau protein isoforms. *Acta Neuropathol*. 2002;104(4):425–434.
35. Feany MB, Dickson DW. Widespread cytoskeletal pathology characterizes corticobasal degeneration. *Am J Pathol*. 1995;146(6):1388–1396.
36. Hattori M, Hashizume Y, Yoshida M, et al. Distribution of astrocytic plaques in the corticobasal degeneration brain and comparison with tuft-shaped astrocytes in the progressive supranuclear palsy brain. *Acta Neuropathol*. 2003;106(2):143–149.
37. Dickson DW, Ahmed Z, Algom AA, Tsuboi Y, Josephs KA. Neuropathology of variants of progressive supranuclear palsy. *Curr Opin Neurol*. 2010;23(4):394–400.
38. Iwasaki Y, Yoshida M, Hattori M, et al. Distribution of tuft-shaped astrocytes in the cerebral cortex in progressive supranuclear palsy. *Acta Neuropathol*. 2004;108(5):399–405.
39. Kovacs GG. Invited review: Neuropathology of tauopathies: principles and practice. *Neuropathol Appl Neurobiol*. 2015;41(1):3–23.
40. Tabata H. Diverse subtypes of astrocytes and their development during corticogenesis. *Front Neurosci*. 2015;9:114.
41. Yoshida M. Cellular tau pathology and immunohistochemical study of tau isoforms in sporadic tauopathies. *Neuropathology*. 2006;26(5):457–470.
42. Dickson DW, Kouri N, Murray ME, Josephs KA. Neuropathology of frontotemporal lobar degeneration-tau (FTLD-tau). *J Mol Neurosci*. 2011;45(3):384–389.
43. de Silva R, Lashley T, Strand C, et al. An immunohistochemical study of cases of sporadic and inherited frontotemporal lobar degeneration using 3R- and 4R-specific tau monoclonal antibodies. *Acta Neuropathol*. 2006;111(4):329–340.
44. Feany MB, Ksiezak-Reding H, Liu WK, Vincent I, Yen SH, Dickson DW. Epitope expression and hyperphosphorylation of tau protein in corticobasal degeneration: differentiation from progressive supranuclear palsy. *Acta Neuropathol*. 1995;90(1):37–43.
45. Miller DW, Cookson MR, Dickson DW. Glial cell inclusions and the pathogenesis of neurodegenerative diseases. *Neuron Glia Biol*. 2004;1(1):13–21.
46. Nishimura T, Ikeda K, Akiyama H, et al. Glial tau-positive structures lack the sequence encoded by exon 3 of the tau protein gene. *Neurosci Lett*. 1997;224(3):169–172.
47. Gao Z, Zhu Q, Zhang Y, et al. Reciprocal modulation between microglia and astrocyte in reactive gliosis following the CNS injury. *Mol Neurobiol*. 2013;48(3):690–701.
48. Pekny M, Pekna M. Astrocyte reactivity and reactive astrogliosis: costs and benefits. *Physiol Rev*. 2014;94(4):1077–1098.
49. Wyss-Coray T. Inflammation in Alzheimer disease: driving force, bystander or beneficial response? *Nat Med*. 2006;12(9):1005–1015.
50. Bieri LM, Hof PR, Purohit DP, et al. Neocortical neurofibrillary tangles correlate with dementia severity in Alzheimer's disease. *Arch Neurol*. 1995;52(1):81–88.
51. Togo T, Dickson DW. Tau accumulation in astrocytes in progressive supranuclear palsy is a degenerative rather than a reactive process. *Acta Neuropathol*. 2002;104(4):398–402.
52. Feany MB, Mattiace LA, Dickson DW. Neuropathologic overlap of progressive supranuclear palsy, Pick's disease and corticobasal degeneration. *J Neuropathol Exp Neurol*. 1996;55(1):53–67.
53. Wang L, Jiang Q, Chu J, et al. Expression of Tau40 induces activation of cultured rat microglial cells. *PLoS One*. 2013;8(10):e76057.
54. Maphis N, Xu G, Kokiko-Cochran ON, et al. Reactive microglia drive tau pathology and contribute to the spreading of pathological tau in the brain. *Brain*. 2015;138(pt 6):1738–1755.
55. Asai H, Ikezu S, Tsunoda S, et al. Depletion of microglia and inhibition of exosome synthesis halt tau propagation. *Nat Neurosci*. 2015;18(11):1584–1593.
56. Barres BA. The mystery and magic of glia: a perspective on their roles in health and disease. *Neuron*. 2008;60(3):430–440.
57. Ransom B, Behar T, Nedergaard M. New roles for astrocytes (stars at last). *Trends Neurosci*. 2003;26(10):520–522.
58. Bartels AL, Kortekaas R, Bart J, et al. Blood-brain barrier P-glycoprotein function decreases in specific brain regions with aging: a possible role in progressive neurodegeneration. *Neurobiol Aging*. 2009;30(11):1818–1824.
59. Zlokovic BV. The blood-brain barrier in health and chronic neurodegenerative disorders. *Neuron*. 2008;57(2):178–201.
60. Blair LJ, Frauen HD, Zhang B, et al. Tau depletion prevents progressive blood-brain barrier damage in a mouse model of tauopathy. *Acta Neuropathol Commun*. 2015;3:8.
61. Haydon PG. GLIA: listening and talking to the synapse. *Nat Rev Neurosci*. 2001;2(3):185–193.
62. Maragakis NJ, Rothstein JD. Glutamate transporters in neurologic disease. *Arch Neurol*. 2001;58(3):365–370.
63. Rothstein JD, Dykes-Hoberg M, Pardo CA, et al. Knockout of glutamate transporters reveals a major role for astroglial transport in excitotoxicity and clearance of glutamate. *Neuron*. 1996;16(3):675–686.
64. Tanaka K, Watase K, Manabe T, et al. Epilepsy and exacerbation of brain injury in mice lacking the glutamate transporter GLT-1. *Science*. 1997;276(5319):1699–1702.
65. Pita-Almenar JD, Zou S, Colbert CM, Eskin A. Relationship between increase in astrocytic GLT-1 glutamate transport and late-LTP. *Learn Mem*. 2012;19(12):615–626.
66. Dabir DV, Robinson MB, Swanson E, et al. Impaired glutamate transport in a mouse model of tau pathology in astrocytes. *J Neurosci*. 2006;26(2):644–654.
67. Yang W, Strong MJ. Widespread neuronal and glial hyperphosphorylated tau deposition in ALS with cognitive impairment. *Amyotroph Lateral Scler*. 2012;13(2):178–193.
68. Philips T, Rothstein JD. Glial cells in amyotrophic lateral sclerosis. *Exp Neurol*. 2014;262 Pt B:111–120.
69. Dickson DW, Feany MB, Yen SH, Mattiace LA, Davies P. Cytoskeletal pathology in non-Alzheimer degenerative dementia: new lesions in diffuse Lewy body disease, Pick's disease, and corticobasal degeneration. *J Neural Transm Suppl*. 1996;47:31–46.
70. Higuchi M, Zhang B, Forman MS, Yoshiyama Y, Trojanowski JQ, Lee VM. Axonal degeneration induced by targeted expression of mutant human tau in oligodendrocytes of transgenic mice that model glial tauopathies. *J Neurosci*. 2005;25(41):9434–9443.
71. Millicamps S, Julien JP. Axonal transport deficits and neurodegenerative diseases. *Nat Rev Neurosci*. 2013;14(3):161–176.
72. Forman MS, Lal D, Zhang B, et al. Transgenic mouse model of tau pathology in astrocytes leading to nervous system degeneration. *J Neurosci*. 2005;25(14):3539–3550.
73. Higuchi M, Ishihara T, Zhang B, et al. Transgenic mouse model of tauopathies with glial pathology and nervous system degeneration. *Neuron*. 2002;35(3):433–446.
74. Colodner KJ, Feany MB. Glial fibrillary tangles and JAK/STAT-mediated glial and neuronal cell death in a *Drosophila* model of glial tauopathy. *J Neurosci*. 2010;30(48):16102–16113.
75. Yoshiyama Y, Zhang B, Bruce J, Trojanowski JQ, Lee VM. Reduction of detyrosinated microtubules and Golgi fragmentation are linked to tau-induced degeneration in astrocytes. *J Neurosci*. 2003;23(33):10662–10671.
76. Richter-Landsberg C. The cytoskeleton in oligodendrocytes. Microtubule dynamics in health and disease. *J Mol Neurosci*. 2008;35(1):55–63.
77. Broe M, Kril J, Halliday GM. Astrocytic degeneration relates to the severity of disease in frontotemporal dementia. *Brain*. 2004;127(pt 10):2214–2220.
78. Kobayashi K, Hayashi M, Nakano H, Shimazaki M, Sugimori K, Koshino Y. Correlation between astrocyte apoptosis and Alzheimer changes in gray matter lesions in Alzheimer's disease. *J Alzheimers Dis*. 2004;6(6):623–632; discussion 673–681.
79. Su JH, Nichol KE, Sitch T, et al. DNA damage and activated caspase-3 expression in neurons and astrocytes: evidence for apoptosis in frontotemporal dementia. *Exp Neurol*. 2000;163(1):9–19.
80. Zehr C, Lewis J, McGowan E, et al. Apoptosis in oligodendrocytes is associated with axonal degeneration in P301L tau mice. *Neurobiol Dis*. 2004;15(3):553–562.
81. Wittmann CW, Wszolek MF, Shulman JM, et al. Tauopathy in *Drosophila*: neurodegeneration without neurofibrillary tangles. *Science*. 2001;293(5530):711–714.
82. Ahmed Z, Cooper J, Murray TK, et al. A novel in vivo model of tau propagation with rapid and progressive neurofibrillary tangle pathology: the pattern of spread is determined by connectivity, not proximity. *Acta Neuropathol*. 2014;127(5):667–683.
83. Clavaguera F, Bolmont T, Crowther RA, et al. Transmission and spreading of tauopathy in transgenic mouse brain. *Nat Cell Biol*. 2009;11(7):909–913.
84. de Calignon A, Polydoro M, Suarez-Calvet M, et al. Propagation of tau pathology in a model of early Alzheimer's disease. *Neuron*. 2012;73(4):685–697.
85. Frost B, Gotz J, Feany MB. Connecting the dots between tau dysfunction and neurodegeneration. *Trends Cell Biol*. 2015;25(1):46–53.
86. Cowan CM, Mudher A. Are tau aggregates toxic or protective in tauopathies? *Front Neurol*. 2013;4:114.



87. Mandelkow EM, Mandelkow E. Biochemistry and cell biology of tau protein in neurofibrillary degeneration. *Cold Spring Harb Perspect Med.* 2012;2(7):a006247.
88. Ding H, Johnson GV. The last tangle of tau. *J Alzheimers Dis.* 2008;14(4):441–447.
89. Santacruz K, Lewis J, Spires T, et al. Tau suppression in a neurodegenerative mouse model improves memory function. *Science.* 2005;309(5733):476–481.
90. Khurana V, Lu Y, Steinhilb ML, Oldham S, Shulman JM, Feany MB. TOR-mediated cell-cycle activation causes neurodegeneration in a *Drosophila* tauopathy model. *Curr Biol.* 2006;16(3):230–241.
91. Steinhilb ML, Dias-Santagata D, Mulkearns EE, et al. S/P and T/P phosphorylation is critical for tau neurotoxicity in *Drosophila*. *J Neurosci Res.* 2007;85(6):1271–1278.
92. Richter-Landsberg C. Protein aggregate formation in oligodendrocytes: tau and the cytoskeleton at the intersection of neuroprotection and neurodegeneration. *Biol Chem.* 2015.
93. Leyk J, Goldbaum O, Noack M, Richter-Landsberg C. Inhibition of HDAC6 modifies tau inclusion body formation and impairs autophagic clearance. *J Mol Neurosci.* 2015;55(4):1031–1046.
94. Noack M, Leyk J, Richter-Landsberg C. HDAC6 inhibition results in tau acetylation and modulates tau phosphorylation and degradation in oligodendrocytes. *Glia.* 2014;62(4):535–547.
95. Min SW, Cho SH, Zhou Y, et al. Acetylation of tau inhibits its degradation and contributes to tauopathy. *Neuron.* 2010;67(6):953–966.
96. Irwin DJ, Cohen TJ, Grossman M, et al. Acetylated tau neuropathology in sporadic and hereditary tauopathies. *Am J Pathol.* 2013;183(2):344–351.
97. Dickey CA, Kamal A, Lundgren K, et al. The high-affinity HSP90-CHIP complex recognizes and selectively degrades phosphorylated tau client proteins. *J Clin Invest.* 2007;117(3):648–658.
98. Schwarz L, Vollmer G, Richter-Landsberg C. The small heat shock protein HSP25/27 (HspB1) is abundant in cultured astrocytes and associated with astrocytic pathology in progressive supranuclear palsy and corticobasal degeneration. *Int J Cell Biol.* 2010;2010:717520.
99. Dabir DV, Trojanowski JQ, Richter-Landsberg C, Lee VM, Forman MS. Expression of the small heat-shock protein alphaB-crystallin in tauopathies with glial pathology. *Am J Pathol.* 2004;164(1):155–166.
100. Renkawek K, Bosman GJ, de Jong WW. Expression of small heat-shock protein hsp 27 in reactive gliosis in Alzheimer disease and other types of dementia. *Acta Neuropathol.* 1994;87(5):511–519.
101. Wilhelmus MM, Otte-Holler I, Wesseling P, de Waal RM, Boelens WC, Verbeek MM. Specific association of small heat shock proteins with the pathological hallmarks of Alzheimer's disease brains. *Neuropathol Appl Neurobiol.* 2006;32(2):119–130.
102. Filipcik P, Cente M, Zilka N, et al. Intraneuronal accumulation of misfolded tau protein induces overexpression of Hsp27 in activated astrocytes. *Biochim Biophys Acta.* 2015;1852(7):1219–1229.
103. Ebner A, Godemann R, Stamer K, Illenberger S, Trinczek B, Mandelkow E. Overexpression of tau protein inhibits kinesin-dependent trafficking of vesicles, mitochondria, and endoplasmic reticulum: implications for Alzheimer's disease. *J Cell Biol.* 1998;143(3):777–794.
104. Carson JH, Worboys K, Ainger K, Barbarese E. Translocation of myelin basic protein mRNA in oligodendrocytes requires microtubules and kinesin. *Cell Motil Cytoskeleton.* 1997;38(4):318–328.
105. Frost B, Hemberg M, Lewis J, Feany MB. Tau promotes neurodegeneration through global chromatin relaxation. *Nat Neurosci.* 2014;17(3):357–366.
106. Ke YD, Dramiga J, Schutz U, et al. Tau-mediated nuclear depletion and cytoplasmic accumulation of SFPQ in Alzheimer's and Pick's disease. *PLoS One.* 2012;7(4):e35678.
107. Malinski T. Nitric oxide and nitroxidative stress in Alzheimer's disease. *J Alzheimers Dis.* 2007;11(2):207–218.
108. Heneka MT, Wiesinger H, Dumitrescu-Ozimek L, Riederer P, Feinstein DL, Klockgether T. Neuronal and glial coexpression of argininosuccinate synthetase and inducible nitric oxide synthase in Alzheimer disease. *J Neuropathol Exp Neurol.* 2001;60(9):906–916.
109. Komori T, Shibata N, Kobayashi M, Sasaki S, Iwata M. Inducible nitric oxide synthase (iNOS)-like immunoreactivity in argyrophilic, tau-positive astrocytes in progressive supranuclear palsy. *Acta Neuropathol.* 1998;95(4):338–344.