

## LETTER TO THE EDITOR

**INFLAMMATION AND NEUROTRANSMISSION OF THE VESICICO-UTERINE SPACE  
IN CESAREAN SECTIONS**

A. MALVASI<sup>1</sup>, D. DELL'EDERA<sup>2</sup>, C. CAVALLOTTI<sup>3</sup>, A. CREANZA<sup>1</sup>, E. PACELLA<sup>4</sup>,  
G.C. DI RENZO<sup>5</sup>, O.A. MYNBAEV<sup>6</sup> and A. TINELLI<sup>7</sup>

<sup>1</sup>Department of Obstetric and Gynecology, Santa Maria Hospital, Bari, Italy; <sup>2</sup>Unit of Cytogenetic and Molecular Genetics, Madonna delle Grazie Hospital, Matera, Italy; <sup>3</sup>Department of Human Anatomy, University Sapienza, Rome, Italy; <sup>4</sup>Department of Ophthalmology, Sapienza University, Rome, Italy; <sup>5</sup>Department of Obstetrics and Gynecology, University of Perugia, Italy; <sup>6</sup>Experimental Researches and Modelling Division, Moscow State University of Medicine and Dentistry, Department of Obstetrics, Gynecology and Reproductive Medicine, Peoples' Friendship University of Russia, Moscow, Russia; <sup>7</sup>Department of Obstetrics and Gynecology, Division of Experimental Endoscopic Surgery, Imaging, Technology and Minimally Invasive Therapy, Lecce, Italy

*Received February 13, 2012 – Accepted October 30, 2012*

**Collagen IV and laminin play a key role in regulating stiffness, elasticity and flexibility of the vescico-uterine space (VUS) tissue. The neurotensin (NT), the neuropeptide tyrosine (NPY) and the protein gene product 9.5 (PGP 9.5) possessing vasorelaxation and tissue vascularization activities, play key roles in cervical ripening, scar innervations and pain control. We propose that the integrity of these substances in VUS tissue is compromised after Cesarean section (CS), since wound healing disturbances and pelvic pain, as well as pregnancy and delivery complications, are related with lower uterine segment dysfunctions after CS. Therefore, the contents of collagen IV, laminin, NT, NPY and PGP 9.5 nerve fibres from the VUS tissue samples obtained during the first CS and the repeated CS were comparatively studied. VUS specimens were collected from 104 patients during CS and evaluated by immunohistochemistry. Collagen IV and laminin were mostly found in the vascular membrane bounds and their images were quantitatively evaluated by Quantimet Leica analyzer software. Differences of collagen IV, laminin, NT, NPY and PGP 9.5 values in VUS tissue between the first CS and the repeat CS samples were calculated by Student's *t*-test. Reduced laminin and increased collagen IV values were observed in the VUS scar tissue after the repeated CS in comparison with those of VUS intact tissue obtained during the first CS. Significantly higher values of nerve fibres, containing NT, NPY and PGP 9.5 were registered in intact VUS tissue samples, respectively  $5 \pm 0.7$ ,  $7 \pm 0.6$  and  $5 \pm 0.9$  CU, than those of VUS scar tissue samples obtained during the repeated CS, respectively  $3 \pm 0.6$ ,  $2 \pm 0.4$  and  $3 \pm 0.7$  CU ( $p < 0.05$ ). The authors observed increased collagen IV and reduced laminin values after the repeated CS which might be the key signs of inflammatory damage of VUS scar tissue by CS. These findings were strengthened by the registration of decreased NT, NPY and PGP 9.5 values in the same samples, which are important neurotransmitters and are responsible for optimal wound healing, pain control and lower uterine segment functions.**

*Key words:* Cesarean section, inflammation, cervical ripening, collagen IV, laminin, Neurotensin (NT), Neuropeptide Tyrosine (NPY), Protein Gene Product 9.5 (PGP 9.5), Vescico-Uterine Space (VUS), lower uterine segment, labour, neurotransmitters, neuropeptides, VBAC

Mailing address: Dr Andrea Tinelli,  
Department of Obstetrics and Gynecology,  
Division of Experimental Endoscopic Surgery,  
Imaging, Technology and Minimally Invasive Therapy,  
Vito Fazzi Hospital, P.zza Muratore, 73100 Lecce, Italy  
Tel.: +39 339 2074078 Fax: +39 0832 661511  
e-mail: andreatinelli@gmail.com

1721-727X (2013)

Copyright © by BIOLIFE, s.a.s.

This publication and/or article is for individual use only and may not be further reproduced without written permission from the copyright holder.

Unauthorized reproduction may result in financial and other penalties  
**DISCLOSURE: ALL AUTHORS REPORT NO CONFLICTS OF  
INTEREST RELEVANT TO THIS ARTICLE.**

The corpus and the cervix of the uterus serve different functions during pregnancy: the corpus distends in order to host the growing fetus, while the cervix remains long and closed in spite of the increasing pressure, until final cervical ripening and onset of labour (1). Cervical ripening is a process that involves an important remodelling of the extracellular matrix and is a prerequisite for effective labour and delivery (2). Many hypotheses have been forwarded to explain cervical ripening mechanisms, such as its association with most increase in the local concentration of cytokines and an influx of inflammatory cells, as well as with changes in other inflammatory mediators, prostaglandins, nitric oxide and neuropeptides, including neurotensin (NT), neuropeptide tyrosine (NPY) and the protein gene product 9.5 (PGP 9.5) (3-6).

However, in spite of utilization of the state-of-the-art technologies, current studies have shown that cervical ripening is the knot set of multitude pathways and mainly misunderstood with disjoint events in experimental and clinical research (7).

We recently observed the presence of substance P (SP) and vasoactive intestinal polypeptide (VIP) and their related neurofibres in the intact and scarred tissue of the lower uterine segment (LUS) in the same women sampled during the first elective Cesarean sections (CS) and later when they delivered by a repeated CS. The SP level was found higher in scar tissue obtained during repeated CS, which is probably linked to an attempt to stimulate the pain by SP and to produce the cervical ripening in the poorly vascularized scarred LUS tissue. The VIP level, however, was found to be lower in scarred LUS tissue, and this is probably linked to a reduction of the micro-vascularization and to the decrease of the amount of the non-vascular and vascular smooth muscle cells. This process alters the relaxation of the uterine internal orifice, interfering with the scarred tissue in LUS formation and the cervical ripening (8).

Many studies have proved an inflammation of the cervical ripening with extravasations of immune competent cells (9), increased values of pro-inflammatory cytokines, and up regulation of IL6, IL8 and granulocyte colony-stimulating factor in the cervical connective tissue (10) with reduced collagen content and structure (11).

From this point of view, our previous findings

of comparative evaluation of active substances involved in cervical ripening in the intact and scarred tissue in the same women support studies proving the hypothesis that cervical ripening is a mainly neuroimmune-mediated inflammatory reaction (10-12), which could be activated through the neuropeptides according to our model (8).

These substances stimulate vascular changes directly or through the synthesis or activation of endothelial nitric oxide system. Further microvascular changes that could promote cervical ripening include: angiogenesis, vascular leakage, egress of leukocytes, and vasodilatation. The SP may control multiple processes by interfering with the vascular endothelial growth factor, estrogen receptors, nitric oxide, leukocytes and collagenase as well as controlling fluid vascular leakage and angiogenesis. Another important view is that sensory nerve fibres of VIP act on uterine isthmus area between the histological uterine internal orifice and the anatomical uterine internal orifice. VIP has been shown to stimulate adenylyl cyclase activity in human endometrial membranes and increase the cyclic AMP content in human myometrial smooth muscle cells. The VIP stimulates smooth cell relaxation and is an important regulator of the smooth muscle cell of the circular and longitudinal musculature, especially around blood vessels (8).

We presumed that our previous findings needed to be supplemented by evaluation of other neurotransmitters and peptides to clarify the insights of the cervical inflammation and ripening by using our unique model with the intact and scarred LUS tissue sampled from the same women with term pregnancy before the onset of labour during the first and repeated CSs.

Therefore the contents of Collagen IV, Laminin, NT, NPY and PGP 9.5 nerve fibres from the VUS tissue samples obtained during the first CS and the repeated CS were comparatively studied.

## MATERIALS AND METHODS

The study was conducted as a prolonged part of our previous research project (8) at the Santa Maria Hospital, Bari, Italy, and Vito Fazzi Hospital, Lecce, Italy, between January 2008 and December 2011. The study consisted of 2 parts: the first included enrolment of women planned to

undergo CS; the second included the sampling on the VUS of the same patients during repeated CS. The inclusion criteria/exclusion criteria, anaesthesia/CS protocols and tissue sampling methods were analogous with those of our previous study design (8).

One hundred and thirty-two women were suitable to be included in the study, but only 116 of these agreed to sign an informed consent and confirmed their participation. One hundred and four women subsequently became pregnant again and, based on their decision all underwent a repeated CS and were included in this research. During both the first and the repeated CSs, after the baby birth and before the uterine suturing, surgeons performed four consecutive serial full thickness biopsy sections with depth 10 mm into the LUS tissue using sterile scissors. Therefore, these samples contained pieces of myometrium from the LUS and adjoining fat or scar tissue from the vesico-uterine space (VUS), thus these samples were recognized as VUS tissue. Samples obtained during repeated CS included scar tissue with inflammatory reaction due to the bladder flap dissection during previous CS (13).

An examination of tissue samples included the following steps: 1) immunochemical staining for collagen IV; 2) immunohistochemical location of the vascular membrane-bound laminin; 3) quantitative analysis of images; 4) statistical analysis of data. The staining of collagen IV was as follows: the purified antibodies against human collagen type IV (catalogue number MCA 119) were from Serotec. The staining of laminin was as follows: monoclonal anti-Laminin antibodies from mouse were purchased from Sigma (catalogue number L 8271). This product is immunogenic for the human laminin, which is localized specifically in the basal membrane of blood vessels, epithelium, nerve and muscle fibres. Monoclonal anti-Laminin may be used for identification of laminin in various human tissues and fluids. Species with reactivity are: cats, pigs and humans. It does not react with basal membranes of other species. This product shows no cross-reaction with collagen type IV, fibronectin, vitronectin or chondroitin sulphates, using a dot blot immunoassay. This immunochemical staining can be performed also on formalin-fixed, paraffin embedded slides, using the primary antibody diluted 1:1000 in buffer substrate. The second antibody suitable for revealing the reaction was the biotinylated extra-avidin peroxidase reagent (3-amino-9-ethyl carbazole) (8).

In order to prepare tissue samples for immunochemical staining part of the specimens were cut with cryostat to obtain sections of approximately 40  $\mu$ m in thickness and part of the fresh sampled material was washed by immersion in a cold Krebs-Ringer's solution, and examined by immunochemical techniques for detection of NT, NPY and PGP 9.5 nerve fibres. Then the sections

subjected to the cryostat were placed on a slide and treated for the detection of each neurotransmitters.

The cover slides bearing the coloured samples were placed on glass microscope slides. Analysis of the samples was carried out with a fluorescence Leitz Ortoplan microscope equipped with an epi-illumination system. The light source was a mercury lamp (HB 100) in combination with selective Leitz filters.

The first section of each slide was processed for haematoxylin and eosin staining to obtain histopathologic visualization of the tissue. The second section of each slide group was stained using a well-used efficient method (14) used in staining all nerve fibres and neurofibrils in all organs and tissues. Nerve fibres and neurofibrils are stained black. The third section of each slide group was processed for the histofluorescence staining of adrenergic fibres (15), using the glyoxylic acid-induced fluorescence technique. The fourth section was treated for histofluorescence staining of aminergic nerve fibres (16). The fourth section was processed for histoenzymatic staining of AChE positive nerve fibres according to the protocol of the thyocoline methods (17). All sections were stained with histo-fluorescent methods and were analyzed on the same day to prevent diffusion and/or photodecomposition of fluorescence (18).

For the detection of each neurotransmitter we used the following phases. First blank: primary or secondary antiserum omitted or denatured or previously adsorbed with an excess of corresponding peptide; second blank: primary or secondary antiserum replaced by a non-immune serum; third blank: sample previously fixed by immersion in a 4% solution of formaldehyde in PBS that did not preserve the immune-reactive sites; fourth blank: sample denatured with formaldehyde before and after treatment with primary antiserum or before treatment with secondary antiserum.

Owing to the thickness of the sections (40  $\mu$ m), the samples were incubated for a 18-24 h at room temperature, so that the antibodies completely penetrated the sections, with the following polyclonal antisera: rabbit anti-NPY (RBI, Cambridge, UK), diluted in 1:600 PBS, rabbit anti-PGP 9.5 (RBI, Cambridge, UK), diluted in 1:600 PBS, and rabbit anti-NT (RBI, Cambridge, UK), diluted in 1:600 PBS.

The samples were then washed in PBS and incubated with fluorescing isothiocyanate-conjugated antiserum (goat anti-rabbit IgG, Nordic Immunological Reagents, Amersham, the Netherlands) diluted 1:100 in PBS for 18-24 h at room temperature allowing the complete penetration of the fluorescent IgG into the thick section. Further details on each type of immunoassay are reported for NPY (19), NT (20), and PGP 9.5 (20).

The fresh cryostatic sections were not mounted in

Entellan (non-autofluorescent) and were observed using a Zeiss III photomicroscope (Carl Zeiss, Oberkochen, Germany) equipped with epi-illumination and Neofluar objectives. Once the nerve fibres had been stained with specific markers (for NT, NPY and PGP 9.5), it was possible to identify under light microscopic examination the area of each of the types of nerve fibre stained by a specific fluorescent neurotransmitter.

Immunoreactivity was detected in intraepidermal and dermal nerve fibres and cells. The intraepidermal nerves were varicose or smooth with different diameters, running as single processes or branched, straight or bent, projecting in various fields.

The quantitative analysis of the images was as follows: for a detailed evaluation of the effects of aging on trabecular meshwork morphology, a quantitative analysis of images was performed on slides and on microphotographs using a Quantiment Analyzer (Leika), equipped with specific software. The density of NT, NPY and PGP 9.5 fibres was calculated by quantitative analysis using a Quantiment Leitz image analyzer that measures the following parameters: 1. detection of NT, NPY and PGP 9.5 nerve containing fibres counted in 10 fields randomly chosen; 2. percentage of the total area occupied by those fields; 3. number of observed varicosities; 4. number of crossings or intersections of the nerve fibres; and 5. total perimeter of NT, NPY and PGP 9.5 structures in proportion to an average value (100 for each field).

Morphometry nowadays is a valid method for quantification of cell density in different pathological and physiological conditions such as normal and abnormal placentas (22). Morphometrical quantification of the density of each type of nerve fibre was performed on photographs of stained samples using a Quantiment Leica 2000 image analyzer (Quantiment 500 Leica Microsystems Imaging Solutions Ltd, Cambridge, UK), used by a single pathologist. The software provided with the Quantiment Leica analyzer is able to count and express these fluorescent areas in "Conventional Units" (CU), i.e. as percentages of the area occupied by a single type of nerve fibre related to the total observed area. By adding these values (single type of nerve fibre) it is possible to evaluate the sum of the areas occupied by the different types of nerve fibres. The software also calculates the average values and translates them to a single value with standard deviation. Other details regarding the experimental procedures used in the morphometrical quantification by the Quantiment Leica are already reported in the Manual of Methods of Anon (8, 23).

The specificity of the immune-histochemical reaction to NT, NPY, PGP 9.5 was confirmed by the results of the control group. In samples denatured with formaldehyde, omission of the primary or secondary antiserum, pre-absorption of each antiserum with an excess of its

respective neuropeptide eliminated all the immune staining. All control procedures resulted in absence of any immune reaction. Positive immunoassays were detected only in the normally treated samples.

Statistical analysis of the data was based on the results obtained from measurements from each sample by the Quantiment Leica analyzer software; and the data were averaged to obtain a median value per case. Repeated immune-fluorescent controls were made and the differences were calculated by the student *t*-test. The results are expressed as conventional units and the standard error of the mean (SEM). P values <0.05 were considered to be statistically significant.

## RESULTS

A reduction in laminin and increased amount of collagen IV were registered in VUS scar tissue samples obtained during repeat CS. The immunohistochemical staining of collagen IV in the wall of normal vessel showed a substantial presence of collagen IV in all the layers of the vessels: the external tunica, the median tunica, the internal tunica and the lumen. The immunohistochemical staining of laminin in the peri-vascular tissues and in the endothelium of normal vessels showed a high amount of laminin in all the vessel layers.

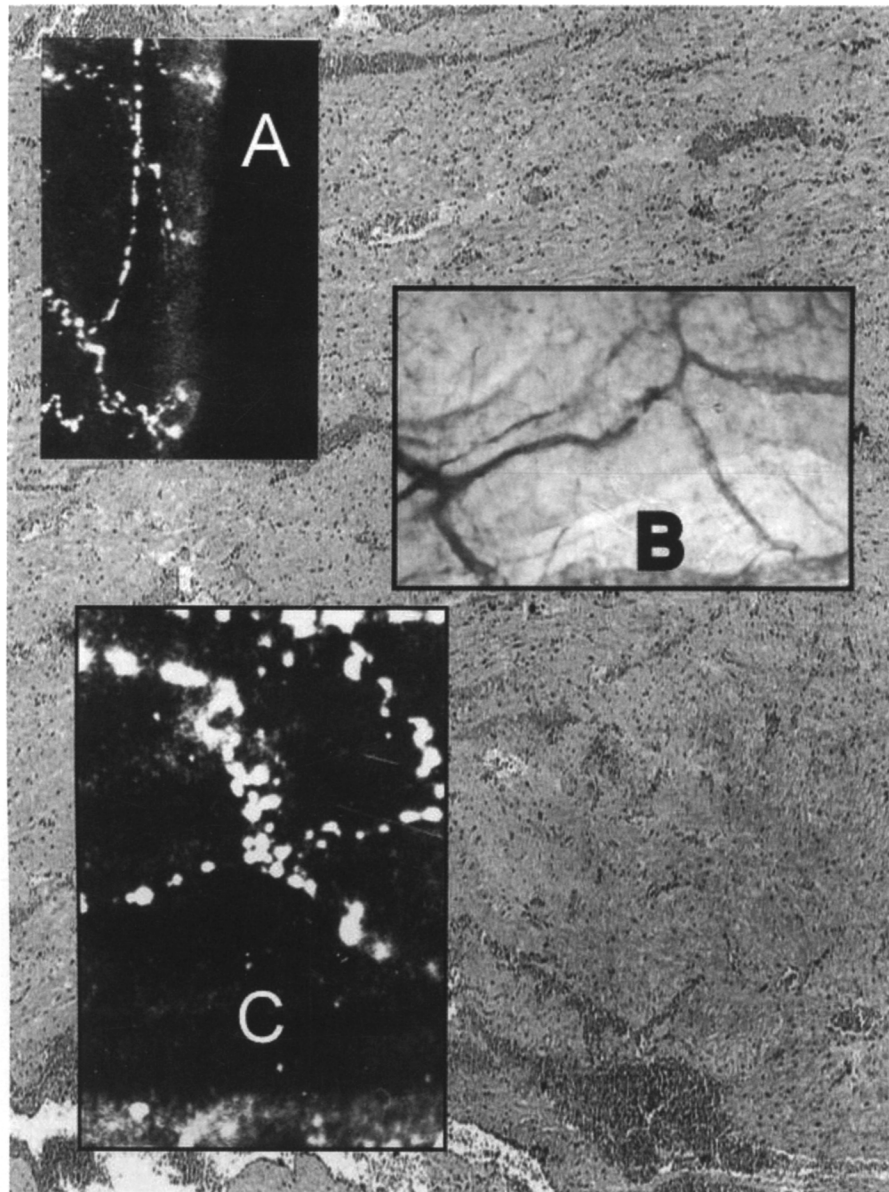
The increase in collagen IV is linked to the increase of amorphous substance, including the glycosaminoglycans and glycoproteins in the blood vessels of the samples. The reduced presence of laminin and the increased presence of collagen and glycoproteins, the two major constituents of basement membranes, indicates ageing of the studied tissues. Both these findings are related to the reduction of the basal membranes.

Nerve fibres containing NT, NPY and PGP 9.5 were frequently registered in the intact VUS tissue respectively up to  $5 \pm 0.7$ ;  $7 \pm 0.6$ ;  $5 \pm 0.9$  CU (Fig. 1), whereas these parameters of scarred VUS tissue were significantly decreased respectively  $3 \pm 0.6$ ;  $2 \pm 0.4$ ;  $3 \pm 0.7$  CU (Fig. 2).

Statistical analysis demonstrated significantly reduced content of nerve fibres containing the NT, NPY and PGP 9.5 in the scar VUS tissue in comparison with those of intact VUS tissue ( $p < 0.05$ ).

## DISCUSSION

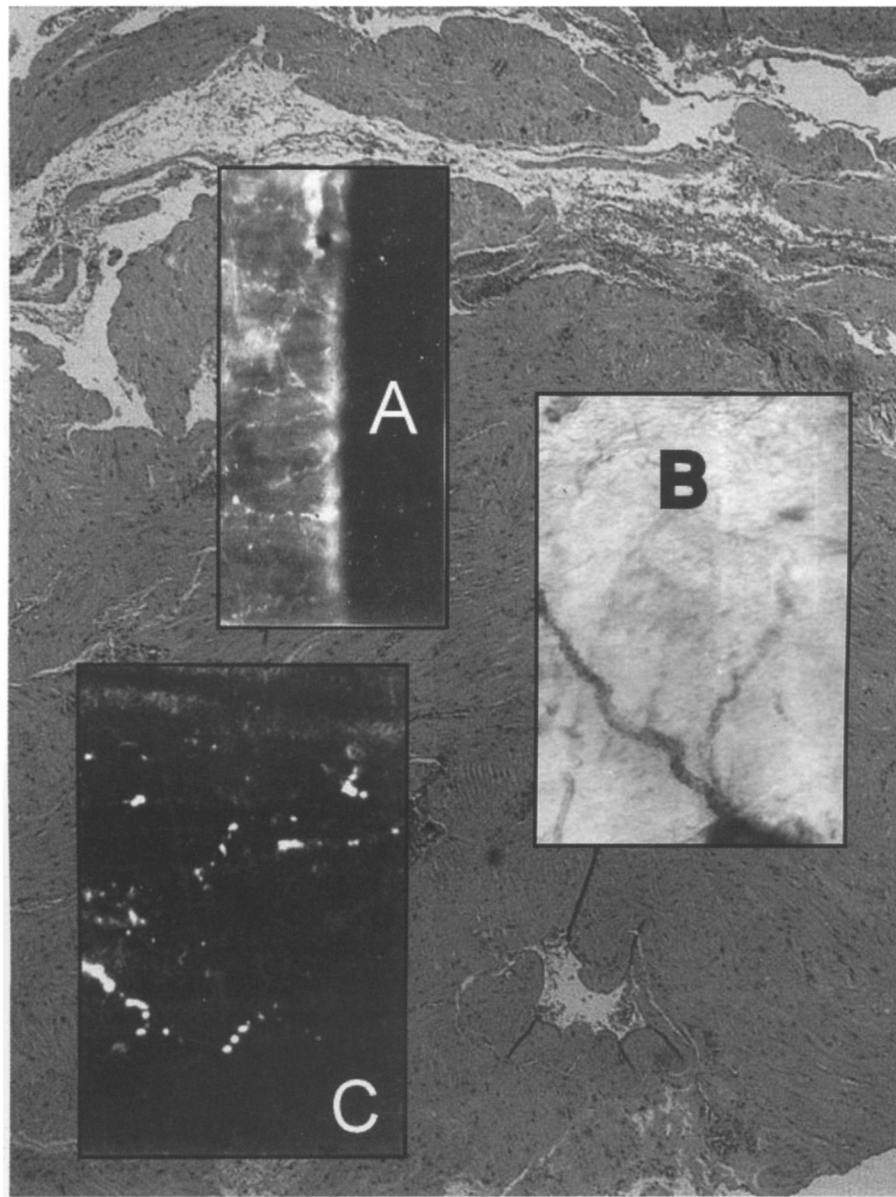
Generally, during pregnancy the uterus enables



**Fig. 1.** *Sagittal section through the human vesico-uterine space (VUS) and lower uterine segment (LUS) tissue samples obtained during first CS. Hematoxylin-Eosin stain (magnification 160x). A distribution of NT (A), NPY (B) and PGP 9.5 (C) neurofibres in the intact VUS/LUS tissue samples.*

an optimal environment for the growing fetus and the closed cervix ensures retention of the fetus in the uterus. The cervix at term undergoes tissue remodelling, the so-called cervical ripening, with a progressive dissociation and disorganization of its collagen fibres and bundles. The ripening of the cervix resulted in its softening and dilatation (24). During labour, the uterine cervix ripens, becoming soft and

pliable, and dilates, when the uterus starts to contract the cervix relaxes, and both of these alterations enable the passage of the fetus at parturition (25). A failure of these processes leads to complications, such as preterm or dystocic labour. The complexity of cervical ripening is evidenced by the multiplicity of neurogenic factors involved, especially in first and repeated CS, since the surgical incision increases the



**Fig. 2.** Sagittal section through the human vesico-uterine space (VUS) and lower uterine segment (LUS) tissue samples obtained during repeat CS. Hematoxylin-Eosin stain (magnification 160x). A distribution of NT (A), NPY (B) and PGP 9.5 (C) neurofibres in VUS/LUS scar tissue samples.

neurogenic inflammatory process concomitant with the cervical ripening.

In addition to our previous findings supporting a vice versa change of increased neuropeptide substance P and decreased vasoactive intestinal polypeptide values in scarred LUS tissue (8), in the current study we summarized that collagen IV

and laminin play key roles in regulating stiffness, elasticity and flexibility of the normal VUS tissue and they contribute to a variety of tissue functions such as incision healing. During repeated CS we detected increased collagen IV and reduced laminin contents in scarred VUS tissue in comparison with those of intact tissue, and changes with these

**Table I.** Evaluation of the sum of the areas occupied by various types of nerve fibres in conventional units (CU) in tissue of the vesico-uterine space (VUS) and the lower uterine segment (LUS) of first and repeated cesarean section; the neurotensin (NT), the neuropeptide tyrosine (NPY) and the protein gene product 9.5 (PGP 9.5) nerve fibre immune-reactivity were tested on fresh samples after staining with fluorescent monoclonal specific antibodies in the lower uterine segment.

*Nerve fibre density containing NT immune-reactivity, within specimens of human VUS and LUS*

Group 1	Group 2	P value
54 samples on LUS (first elective CS)	50 scar on LUS (repeated CS)	
5±0.7 immune-reactivity	2±0.4 immune-reactivity	< 0.05

*Nerve fibre density containing NPY immune-reactivity, within specimens of human VUS and LUS*

Group 1 (54 patients)	Group 2 (50 patients)	P value
54 samples on LUS (first elective CS)	50 scar on LUS (repeated CS)	
7±0.6 immune-reactivity	3±0.5 immune-reactivity	< 0.05

*Nerve fibre density containing PGP 9.5 immune-reactivity, within specimens of human VUS and LUS*

Group 1	Group 2	P value
54 samples on LUS (first elective CS)	50 scar on LUS (repeated CS)	
5±0.9 immune-reactivity	3±0.7 immune-reactivity	< 0.05

peptides could be recognized as biochemical signs of inflammatory damage. Furthermore, the reduction of neuropeptides content (NT, NPY and PGP 9.5) in these scarred tissue samples might be considered as a logical fall out of the normal onset of labour with cervical ripening and gradually increased uterine contractility. The relevance of our findings are evident if we take into account results of many studies proving the concept of cervical ripening as an inflammatory reaction.

Stjernholm et al. (26) found abundant dendritic

cells, positive for HLA-DR and protein S-100 in the cervix, especially at term, suggesting a general activation of the immune system at late pregnancy and at parturition. This team also studied distribution of PGP 9.5-immunoreactive nerve fibres and cells in cervical biopsies obtained from late pregnant, postpartal and non-pregnant women and presented that the total frequency of PGP 9.5-immunoreactive nerve fibres and cells was the highest in the late pregnant, slightly lower in the postpartal and the lowest in the non-pregnant women (12).



The birth process is then influenced by a combined action of neuropeptide activity and Kataoka et al. (27) synthesized a hypothalamic tridecapeptide, NT, and its C-terminal partial sequences down to the dipeptide and showed an impact of these peptides on contracting activity of rat stomach fundus, uterus and duodenum, guinea pig ileum and rabbit carotid artery isolates, whereas Lebrun et al. (28) presented the existence of NT receptors in the rat uterine isolates. Jovanovic et al. (29) showed several mechanisms of NPY impact on different guinea pig organs including its uterine horns: firstly, this neuropeptide induces contraction of guinea pig uterine arteries acting on receptors localized in smooth muscle; secondly, pregnancy alters the response of guinea pig uterine arteries to NPY in such a way as to promote vasorelaxation; thirdly it modulates the effect of neurotransmitters on guinea pig uterine arteries, but pregnancy is not associated with the changes at the level of NPY-neurotransmitter interaction. Alm and Lundberg (30) found the most abundant NPY-immunoreactive nerves (IRN) in the guinea pig uterus, whereas the distribution of SP-, neurokinin A and calcitonine gene-related peptide-IRN was less frequent and the peptide histidine isoleucine-IRN – the most sparse ones.

Thus, NT, NPY and PGP 9.5 join in the cervical ripening process and in scar innervations, acting on the vasorelaxation, tissue vascularization and on pain control. Their deficit probably has an impact on physiological phenomena of the LUS formation, as cervical ripening and LUS functionality in labour. NT acts directly on the smooth cells of uterine musculature, so that the smooth cell activity could be reduced in the LUS of women with a previous CS. Similarly, the NPY reduction in the VUS scar could produce an arterial vasorelaxation reduction, leading to an alteration of cervical ripening, which is a physiological process that determines a progressive dilatation of the cervix. The PGP 9.5 decreasing could be linked to an altered cervical vascularization, especially during cervical ripening, and the denervated scar could be linked to an alteration of pain control in pregnant women who had undergone a previous CS. The NPY and PGP 9.5 action is then similar to the VIP function. In conclusion, the inflammation and neurotransmission in VUS of women who had undergone repeated CS was investigated

by collagen IV, laminin, NT, NPY and PGP 9.5 analysis. Collagen IV and laminin have a key role in regulating stiffness, elasticity and flexibility of the normal VUS, as such neurotransmitters contribute to a variety of tissue functions: the reduction of NPY in the repeat CS scars could be related to a vaso-dilating effect, the NT decreasing reduces the smooth cell vessel contractility, the PGP 9.5 lowering alters the uterine innervation process, all affecting the physiological proceedings of uterine cervical ripening through labour timing. Our investigation showed an increase in collagen IV and a reduction of laminin, NT, NPY, PGP 9.5 in VUS, sign of inflammatory damage in VUS of repeat CS, that is an increase of the pseudoinflammatory phenomenon already determined by the cervical ripening, with a negative impact on LUS functionality in labour timing and onset. Based on these findings, it could be hypothesized a therapeutic and/or diagnostic application for these neuropeptides or their antagonist in cervical ripening and in labour onset.

Further studies will be needed to clarify the role of proteins and neurotransmitters in the VUS of repeat CSs during cervical ripening, as well as in pain sensation in women undergoing vaginal birth after CS.

## REFERENCES

1. Tingaker BK, Johansson O, Cluff AH, Ekman-Ordeberg G. Unaltered innervation of the human cervix uteri in contrast to the corpus during pregnancy and labour as revealed by PGP 9.5 immunohistochemistry. *Eur J Obstet Gynecol Reprod Biol* 2006; 125:66-71.
2. Boyd JW, Lechuga TJ, Ebner CA, Kirby MA, Yellon SM. Cervix remodeling and parturition in the rat: lack of a role for hypogastric innervation. *Reproduction* 2009; 137(4):739-48.
3. Collins JJ, Usip S, McCarson KE, Papka RE. Sensory nerves and neuropeptides in uterine cervical ripening. *Peptides* 2002; 23(1):167-83.
4. Chwalisz K, Garfield RE. Nitric oxide as the final metabolic mediator of cervical ripening. *Hum Reprod* 1998; 13(2):245-8.
5. Gibb W. The role of prostaglandins in human parturition. *Ann Med* 1998; 30(3):235-41.



6. Osman I, Young A, Ledingham MA, Thomson AJ, Jordan F, Greer IA, Norman JE. Leukocyte density and pro-inflammatory cytokine expression in human fetal membranes, decidua, cervix and myometrium before and during labour at term. *Mol Hum Reprod* 2003; 9(1):41-5.
7. Mahendroo M. Cervical remodeling in term and preterm birth: insights from an animal model. *Reproduction* 2012; 143(4):429-38.
8. Malvasi A, Tinelli A, Cavallotti C, Bettocchi S, Di Renzo GC, Stark M. Substance P (SP) and vasoactive intestinal polypeptide (VIP) in the lower uterine segment in first and repeated cesarean sections. *Peptides* 2010; 31(11):2052-9.
9. Osman I, Young A, Ledingham MA, Thomson AJ, Jordan F, Greer IA, Norman JE. Leukocyte density and pro-inflammatory cytokine expression in human fetal membranes, decidua, cervix and myometrium before and during labour at term. *Mol Hum Reprod* 2003; 9(1):41-5.
10. Sennström MB, Ekman G, Westergren-Thorsson G, et al. Human cervical ripening, an inflammatory process mediated by cytokines. *Mol Hum Reprod* 2000; 6(4):375-81.
11. Boyd NL, Robbins KR, Dhara SK, West FD, Stice SL. Human embryonic stem cell-derived mesoderm-like epithelium transitions to mesenchymal progenitor cells. *Tissue Eng Part A* 2009; 15(8):1897-907.
12. Stjernholm Y, Sennstrom N, Granstrom L, Ekman G, Johansson O. Protein gene product 9.5 – immunoreactive nerve fibres and cells in human cervix late pregnant, postpartal and non pregnant women. *Acta Obstet Gynecol Scand* 1999; 78(4):299-304.
13. Malvasi A, Tinelli A, Farine D, Rahimi S, Cavallotti C, Vergara D, Martignago R, Stark M. Effects of visceral peritoneal closure on scar formation at cesarean delivery. *Int J Gynaecol Obstet* 2009; 105(2):131-5.
14. Bodian D. A new method for staining nerve fibers and nerve endings in mounted paraffin sections. *Anat Rec* 1936; 65:89-97.
15. Quayyum MA, Fatani JA. Use of glyoxalic acid in the demonstration of autonomic nerve profiles. *Experientia* 1985; 41:1389-90.
16. Falck B, Hillarp NA, Thieme G, Torp A. Fluorescence of catecholamines and related compounds condensed with formaldehyde. *J Histochem Cytochem* 1962; 10:348-54.
17. Karnowsky MJ, Roots L. A direct colouring thiocholine method for cholinesterase. *J Hist Cytochem* 1964; 12:219-21.
18. Mazzi V. *Manuale di tecniche istologiche ed istochimiche*. Piccin Ed, Padova, Italy, 1977; 1-490.
19. Uddman R, Eklaab E, Edvinsson L, Hakanson M, Sundler F. Neuropeptide Y-like immunoreactivity in perivascular nerve fibers of the guinea pig. *Regulatory Peptides* 1985; 10:243-56.
20. Kohler C, Eriksson LG. An immunohistochemical study of somatostatin and neurotensin positive neurons in the septal nuclei of the rat brain. *Anat Embriol* 2004; 20:1-10.
21. Wang L, Hilliges M, Jernberg T, Wiegleb-Edstrom D, Johansson O. Protein gene product 9.5-immunoreactive nerve fibres and cells in human skin. *Cell Tissue Res* 2004; 3:25-33.
22. Maly A, Goshen G, Sela J, Pinelis A, Stark M, Maly B. Histomorphometric study of placental villi vascular volume in toxemia and diabetes. *Hum Pathol* 2005; 36:1074-9.
23. Malvasi A, Tinelli A, Guido M, et al. Effect of avoiding bladder flap formation in caesarean section on repeat caesarean delivery. *Eur J Obstet Gynecol Reprod Biol* 2011; 159(2):300-4.
24. Mowa CN, Jesmin S, Sakuma I, Usip S, Togashi H, Yoshioka M, Hattori Y, Papka R. Characterization of Vascular Endothelial Growth Factor (VEGF) in the uterine cervix over pregnancy: effects of denervation and implications for cervical ripening. *J. Histochem Cytochem* 2004; 52:1665-74.
25. Kelly RW. Inflammatory mediators and cervical ripening. *J. Reprod Immunol* 2002; 57:217-24.
26. Stjernholm Y, Sennström M, Granström L, Ekman G, Liang Y, Johansson O. Neurochemical and cellular markers in human cervix of late pregnant, postpartal and non-pregnant women. *Acta Obstet Gynecol Scand* 2000; 79(7):528-37.
27. Kataoka K, Taniguchi A, Shimizu H, Soda K, Okuno S, Yajima H, Kitagawa K. Biological activity of neurotensin and its C-Terminal partial sequence. *Brain Res Bull* 1978; 3(5):555-7.
28. Lebrun I, Camargo AC, Correa FM. Pharmacological effects and metabolism of neurotensin and bradykinin

- in the isolated rat uterus. *Eur J Pharmacol* 1988; 148(2):231-7.
29. Jovanovic S, Grbovic L, Jovanovic A. Pregnancy is associated with altered response to neuro peptide Y in uterine artery. *Molecular Hum Reprod* 2000; 6(4):352-60.
30. Alm P, Lundberg LM. Co-existence and origin of peptidergic and adrenergic nerves in the guinea pig uterus. Retrograde tracing and immunocytochemistry, effects of chemical sympathectomy, capsaicin treatment and pregnancy. *Cell Tissue Res* 1988; 254(3):517-30.