

A giant solid cystic inferior fourth ventricle subependymoma – Case report and literature review

A. Giovani, Narcisa Bucur, Ana Gheorghiu, Lena Papadopol, R.M. Gorgan

“Bagdasar-Arseni” Emergency Hospital, Bucharest, ROMANIA

Abstract: Subependymomas are a rare subtype of ependymomas, slow growing WHO grade I tumors that develop either intracranial from the subependymal glial precursor cells layer of the ventricles or intramedullary. These tumors originate in the undifferentiated Subependymal layer of cells that can become either ependymocytes or astrocytes. Most of the subependymomas are located inside the fourth ventricle (50-60%). We reviewed the case of a 40 years old woman with a giant solid cystic fourth ventricle ependymoma. The patient underwent total resection of the tumor through a suboccipital transvermian approach. We discussed the characteristics of these benign tumors and reviewed the literature on this subject and concluded that total resection is the treatment of choice for symptomatic Subependymomas localized in posterior fossa.

Key words: subependymoma, giant, solid cystic, fourth ventricle

Introduction

Subependymomas are a rare subtype of ependymomas, slow growing WHO grade I tumors that develop either intracranial from the subependymal glial precursor cells layer of the ventricles or intramedullary.[7,13] Ependymomas are more frequent in pediatric patients accounting for 6–12% of all intracranial tumours. The intramedullary location is the most frequent, these tumors accounting for 50-60% of all spinal cord lesions. The term of subependymomas was coined in 1945 and since then many authors published only case reports, reflecting the

rarity of this tumor, with an incidence between 0,2% and 0,7%. [8] Most of the subependymomas are located inside the fourth ventricle (50-60%) and become symptomatic when large enough to compress the cerebellum, the floor of the fourth ventricle or to obstruct the CSF flow with progressing secondary hydrocephalus [10]. These tumors originate in the undifferentiated Subependymal layer of cells that can become either ependymocytes or astrocytes [3]. A few reports documented the familial occurrence of subependymoma.

Case report

A 40 years old woman presented with an 8 months history of intense headache nausea and vomiting, signs of increased intracranial pressure, posture and gait ataxia, horizontal nystagmus walking fatigueability and paresthesia in both inferior limbs. Her eye exam showed a mild bilateral papilledema.

A brain MRI revealed a well-delimited tumor occupying the caudal part of the fourth ventricle with an associated cyst on the superior aspect compressing the vermis and cerebellar hemispheres. The solid portion was inhomogeneous on T1 showing moderate and irregular enhancement, a hypointense core and periphery and a hyperintense ring, sign of intratumoral bleeding in between. (Figure 1). The tumor also showed microcalcifications around the hypodense core on CT scan.

Surgery

The patient was placed in prone position with the head slightly elevated and flexed for a better opening of the space between the occiput and C1. Using a midline occiput C6 incision, a bilateral suboccipital craniotomy was performed including the posterior C1 arch. Opening the arachnoid over the cisterna magna relieved CSF under pressure and relaxed the cerebellum. The inferior pole of the tumor became visible in the cerebellomedullary fissure as it enlarged the foramen Magendie and displaced the cerebellar hemispheres laterally and the vermis superiorly.

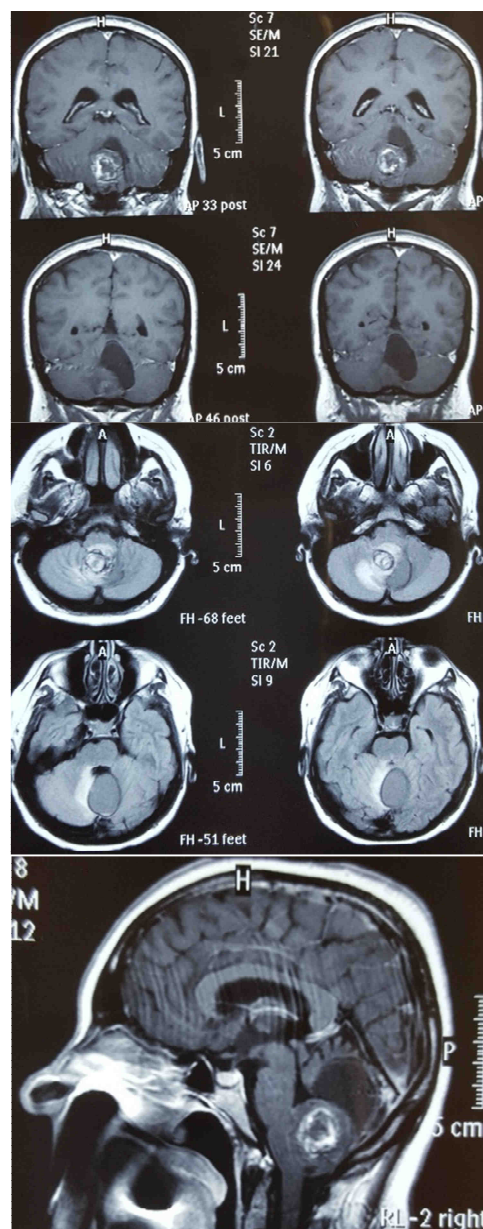


Figure 1 - Frontal, axial and sagittal Preop MRI showing a giant IV ventricular lesion, with solid and cystic component presenting some core hipo/hyperintensities. The lesion compresses the brainstem and the cystic component displaces the vermis reaching the tentorium

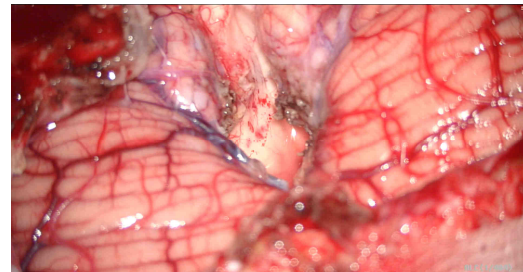
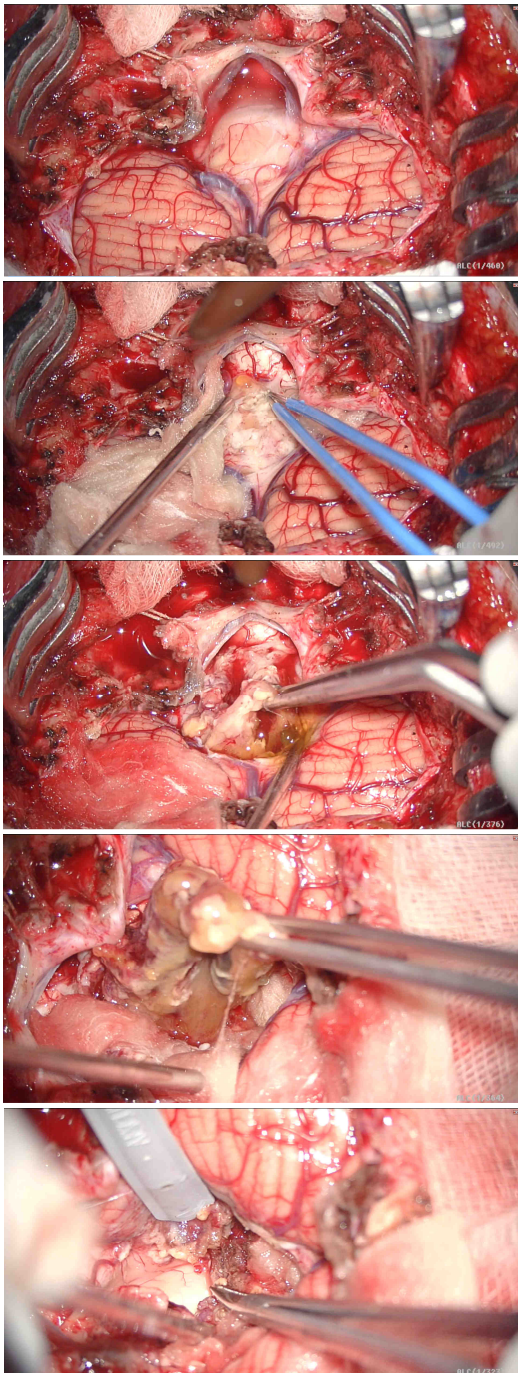


Figure 2 - a) the suboccipital approach was performed, and the arachnoid opened showing centrally a large tumor that displaces the cerebellar hemispheres laterally invading most of the cisterna magna. b,c) the tumor is internally debulked until the cystic portion is reached and a dark yellow viscous fluid is aspirated. d) the tumor is circumferentially dissected from the parenchima without traction , and resected piecemeal. E) the floor of the IV ventricle is visible between some tumor portions attached to the inferior vellum. F) final aspect, after gross total resection was achieved with the white floor of the IVth ventricle visible between the tonsils

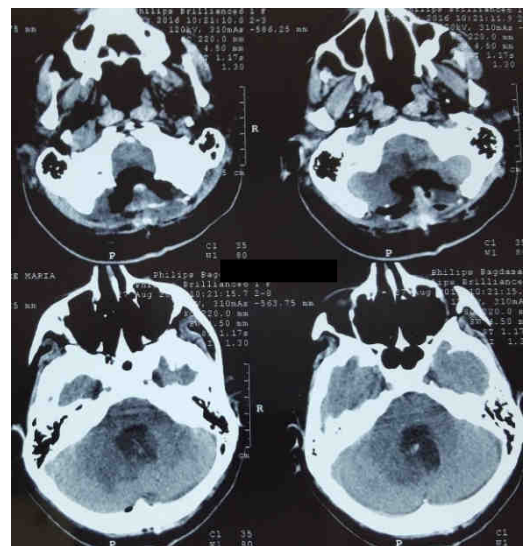


Figure 3 - the 2nd day postoperative CT scan showing no tumor remnant

A big portion of the tumor was bulging into the cisterna magna and the first step in approaching it was internal debulking and aspiration of the dark yellow cyst fluid. Incision of the vermis revealed a firm lobulated tumor that entirely occupied the cavity of the fourth ventricle. Step by step, the tumor capsule was detached from the surrounding tissue, with fine movements avoiding traction on the walls of the IVth ventricle. Using cotton pledges in the plane between the tumor and parenchyma eased the dissection. As the tumor was firm and not attached to the floor of the ventricle it could be removed piecemeal. Frozen-section examination of a tumor specimen revealed the typical histological picture of subependymoma. We did not encounter important bleeding from the tumor during resection.

Immediately postoperative the ataxia, nistagmus and the signs of increased intracranial pressure disappeared but she presented mild transitory dysphagia. Her sensibility improved to normal at 2 months follow up. The pathology result confirmed the diagnostic of subependymoma.

Discussion

These benign WHO Grade 1[15], soft tumors are asymptomatic until they reach an important size even when localized in IVth ventricle so many of them are autopsy reports, with an incidence of 0,4% [9] Scheithauer et al.[12] reported 21 cases of symptomatic large Subependymomas, 8.3% of a large series of ependymomas, 11 of which were located in the fourth ventricle. A 10 years span

retrospective study on Subependymomas performed at Beijing Tiantan Hospital analyzed 43 patients (0.07% of 60000 surgical), 7 of which were located in the fourth ventricle [2]. Most of the tumors in this study 90% were located in the ventricular system, and most of them presented a multicystic pattern on MRI.

P. Clarenbach et al. reported subependymomas of the fourth ventricle in identical twins suggesting that that not only histology and topology but also growth dynamics were prenatally determined. [5]

Both CT scan and MRI are useful in orienting the preoperative diagnosis towards subependymoma by comparison with medulloblastoma and low-grade astrocytoma, the other frequent fourth ventricle neoplasms, sometimes the resemblance of subependymomas with astrocytomas is so big in both T1 and T2 MRI sequences that only the presence of microcysts can make the difference. The MRI characteristics of subependymomas are nonspecific, but MRI spectroscopy showing normal Choline/Creatinine peaks and decreased NAA peak can help in directing the diagnosis. [4, 6]

Our patient had no cranial nerve deficits given by compression of forth ventricle floor because the tumor enlarged the foramen Magendie and was expressed in the cisterna magna displacing the vermis superiorly and the tonsils and cerebellar hemispheres laterally. The tumor was approached using a transvermian approach as we considered this better than telovelar approach, for large tumors that cross into the cisterna magna through the foramen of Magendie.

There are reports of transitory akinetic

mutism associated with the transvermian approach, yet we didn't encounter such cases in our experience [14]. We consider that in big tumors inside the IVth ventricle especially those attached to the roof, this approach is better than the telovelar approach. For most tumors involving the floor of the IVth ventricle we prefer the telovelar approach. Like most cases reviewed in literature, our case had a mixt cystic solid aspect that made the resection easier. Once the cyst was punctured, enough space was gained for the circumferential dissection of the tumor from the adjacent parenchima. The tumor did not infiltrate the floor of the fourth ventricle which explained the lack of cranial nerve deficits at presentation.

Gross total resection is the main treatment, assuring a Long-term survival. A study from Barrow institute compared gross total resection (GTR) with GTR followed by radiotherapy found a statistical superiority for the latter in terms of improving the long term local control [11]. Our treatment protocol for posterior fossa ependymomas also includes postoperative radiotherapy that is efficient in recurrences control and well tolerated by the patients, but we don't recommend it for subependymomas.

There were previous reports of using 5 ALA for a better identification of the tumor margins [1]. This technique was not available in our case but the tumor was well encapsulated and the gross total resection could be documented by simple inspection.

Conclusions

Total resection is the treatment of choice for symptomatic Subependymomas localized in posterior fossa. A meticulous surgical technique is the mainstay of a favorable outcome for the tumors located in the fourth ventricle. The choice of the approach should balance the extent of access to the tumor with the risk of damaging surrounding eloquent structures.

References

1. Bernal García LM, Cabezudo Artero JM, Marcelo Zamorano MB, Gilete Tejero I. ; Fluorescence-guided resection with 5-aminolevulinic Acid of subependymomas of the fourth ventricle: report of 2 cases: technical case report. ; Neurosurgery. 2015 Jun;11 Suppl 2:E364-71; discussion E371
2. Bi Z, Ren X, Zhang J, Jia W.; Clinical, radiological, and pathological features in 43 cases of intracranial subependymoma. J Neurosurg. 2015 Jan;122(1):49-60. Doi 10.3171/2014.9.JNS14155.
3. Brown DF, Rushing EJ: Subependymomas: Clinicopathologic study of 14 tumors. Arch Pathol Lab Med 123:873, 1999.
4. Chiechi MV, Smirniotopoulos JG, Jones RV: Intracranial subependymomas: CT and MR imaging features in 24 cases. AJR Am J Roentgenol 165:1245–1250, 1995.
5. Clarenbach P, Kleihues P, Metzel E, Dichgans J. Simultaneous clinical manifestation of subependymoma of the fourth ventricle in identical twins. Case report. J Neurosurg. 1979 May;50(5):655-9.
6. Hoeffel C, Boukobza M, Polivka M, Lot G, Guichard JP, Lafitte F, Reizine D, Merland JJ: MR manifestations of subependymomas. AJNR Am J Neuroradiol 16:2121–2129, 1995
7. Jooma R, Torrens MJ, Bradshaw J, Brownell B: Subependymomas of the fourth ventricle. Surgical treatment in 12 cases. J Neurosurg 62:508–512, 1985
8. Lobato RD, Sarabia M, Castro S, Esparza J, Cordobes F, Portillo JM, Rivas JJ: Symptomatic subependymoma: Report of four new cases studied with computed

tomography and review of the literature. *Neurosurgery* 19:594–598, 1986.

9. Matsumura A, Ahyai A, Hori A, Schaake T.; Intracerebral subependymomas. Clinical and neuropathological analyses with special reference to the possible existence of a less benign variant. *Acta Neurochir (Wien)*. 1989;96(1-2):15-25.

10. Ragel BT, Osborn AG, Whang K, Townsend JJ, Jensen RL, Couldwell WT. ; Subependymomas: an analysis of clinical and imaging features. *Neurosurgery*. 2006 May;58(5):881-90; discussion 881-90.

11. Rogers LJ, Puschel J, Spetzler R, Shapiro W, Coons S, Thomas T, Speiser B. Is gross-total resection sufficient treatment for posterior fossa ependymomas? *J Neurosurg*. 2005 Apr;102(4):629-36.

12. Scheithauer BW: Symptomatic subependymoma. Report of 21 cases with review of the literature. *J Neurosurg* 49:689–696, 1978.

13. Shuangshoti S, Rushing EJ, Mena H, Olsen C, Sandberg GD: Supratentorial extraventricular ependymal neoplasms: A clinicopathologic study of 32 patients. *Cancer* 103:2598–2605, 2005.

14. Tamburrini G, Frassanito P, Chieffo D, Massimi L, Caldarelli M, Di Rocco C. Cerebellar mutism. ; *Childs Nerv Syst*. 2015 Oct;31(10):1841-51. doi: 10.1007/s00381-015-2803-6. Epub 2015 Sep 9. Review.

15. Wiestler OD, Schiffer D: Subependymoma, in Kleihues P, Cavenee WK (eds): *Pathology and Genetics of Tumours of the Nervous System*. Lyon, International Agency for Research on Cancer (IARC) Press, 2000, pp 80–81.