



## NOTE

Surgery

# Liposarcoma of the spermatic cord in a Toy Poodle

Daji NOH<sup>1)</sup>, Wooson CHOI<sup>2)</sup>, Woochan SON<sup>3)</sup>, Manhee LEE<sup>1)</sup>, Seungchun PARK<sup>1)</sup> and Kija LEE<sup>1)\*</sup><sup>1)</sup>College of Veterinary Medicine, Kyungpook National University, Daegu 41566, Korea<sup>2)</sup>Two Man Veterinary Hospital, Daegu 42770, Korea<sup>3)</sup>Department of Pathology, Asan Medical Center, University of Ulsan College of Medicine, Seoul 05505, Korea*J. Vet. Med. Sci.*

79(12): 2026–2029, 2017

doi: 10.1292/jvms.17-0357

Received: 27 June 2017

Accepted: 16 October 2017

Published online in J-STAGE:  
14 November 2017

**ABSTRACT.** Liposarcoma of the spermatic cord is extremely rare in dogs and humans. This report describes the clinical signs, typical diagnostic imaging including ultrasound and computed tomography, and treatment of a liposarcoma of the spermatic cord of a Toy Poodle confirmed by histological examination after a surgical procedure. This case highlights the importance of preoperative diagnostic imaging and histopathological examination in dogs with an inguinal or scrotal mass.

**KEY WORDS:** computed tomography, dog, liposarcoma, scrotal mass, spermatic cord

Liposarcomas in dogs are uncommon soft tissue tumors that consist of lipoblasts and mesenchymal tissue. They can develop in any tissue that contains fat cells, including subcutaneous tissues, body cavities, and other extracutaneous tissues, and tend to be locally invasive [2, 4, 7, 8, 18]. To our knowledge, liposarcoma of the spermatic cord (LSC) is extremely rare in both dogs and humans, with approximately only 200 cases in humans being reported worldwide [5, 11, 14–16]. This report describes the first case of LSC in a dog and the associated clinical signs, characteristics of diagnostic imaging, and treatment.

A 10-year-old, intact male Poodle dog weighing 4.2 kg presented with a history of a painless and slowly growing palpable scrotal mass over a 3-week period; the patient had no other clinical problems. A physical examination revealed an elongated, ill-defined, non-mobile, tender mass in the left scrotum having a diameter of less than 1 cm; the patient had no pain reaction when the mass was palpated. No abnormalities were detected on the complete blood count, serum biochemical analysis, and electrolyte examination.

There were no significant findings on abdominal radiographs. Ultrasonography (Prosound F75, Hitachi Aloka Medical, Tokyo, Japan) was performed by an experienced sonographer. Transabdominal ultrasonography revealed a heterogeneous mass with hyperechogenicity in the left spermatic cord cranial to a normal left testis (Fig. 1).

Under general anesthesia, the dog was positioned in dorsal recumbency on the computed tomography (CT) table. CT scanning of the abdomen and thorax was performed using a 32-row multi-detector CT scanner (Alexion, Toshiba Medical Systems Corp., Otawara, Japan). The scanning parameters were a contiguous slice thickness of 3 mm, 120 mA, 200 kV, and craniocaudal scan direction. Contrast studies were performed after intravenous administration of 600 mg iodine/kg iohexol (Omnipaque, Nycomed Imaging, Oslo, Norway) injected for 20 sec using an autoinjector. The arterial, portal venous, and delayed phases were acquired 20, 35 and 90 sec after injection, respectively. The mass was elongated, fat-attenuating (–110 HU), and located on the left spermatic cord extending from the left scrotum to the left inguinal canal with a length of 6 cm. This mass contained partial hyper-attenuating to the fat tissue and mild contrast enhancement on post-contrast CT (Fig. 2). There was no evidence of regional lymph node metastasis on either ultrasonography or CT.

The dog underwent surgical resection of the spermatic cord mass with a wide margin, with bilateral orchiectomy. The histopathologic diagnosis of the spermatic cord mass was a well-differentiated liposarcoma (Fig. 3). The patient recovered well from surgery and was discharged without complications 2 days later. After 15 months of follow-up, the dog was in good condition with no evidence of recurrence.

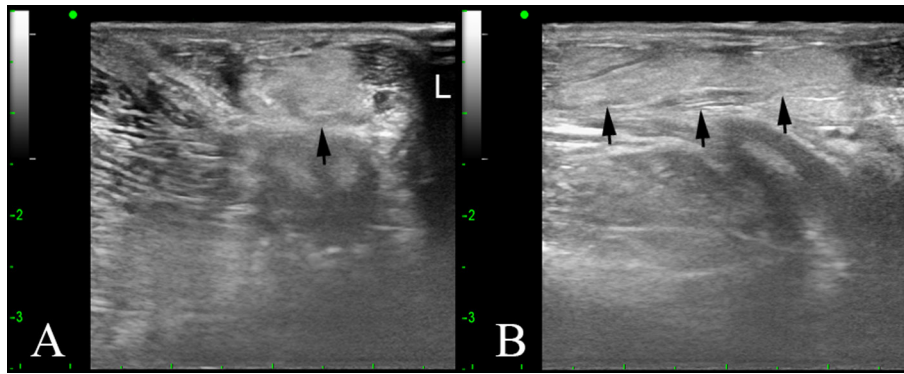
Male genital tract tumors in dogs have been previously reported, including penile, preputial, testicular, epididymal, scrotal, and prostate tumors [1]. However, there has been no study of a LSC in dogs.

In humans, LSCs usually present as a non-tender, painless, inguinal or scrotal mass of variable size with slow growth over a period ranging from a few months to years. Due to its typical presentation, an LSC must be differentiated from an inguinal hernia, funicular cysts, and lipoma of the cord [5, 11, 14–16]. In the present study, similar clinical signs presented as a slowly growing painless scrotal mass.

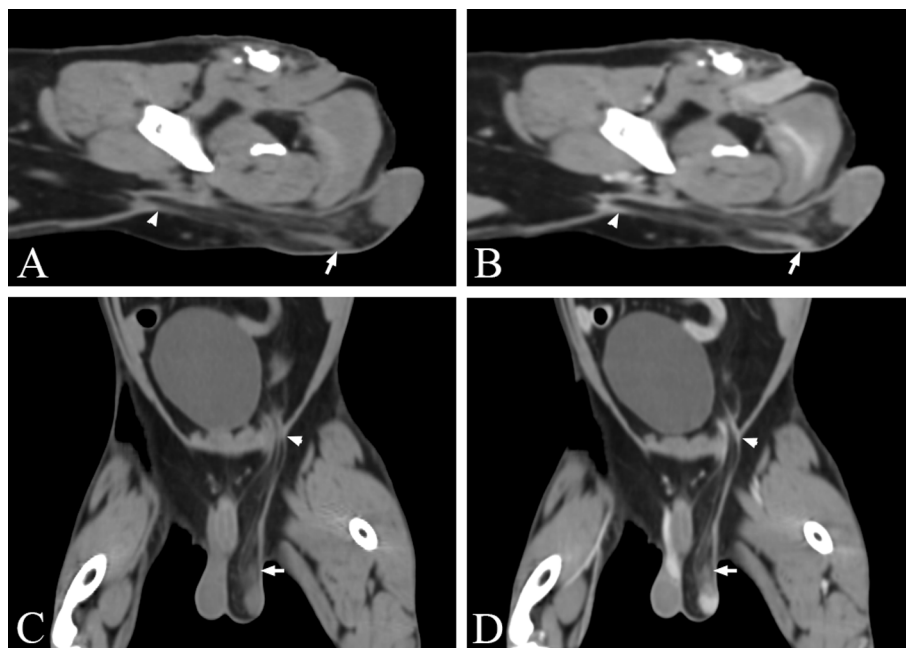
\*Correspondence to: Lee, K.: leekj@knu.ac.kr

©2017 The Japanese Society of Veterinary Science

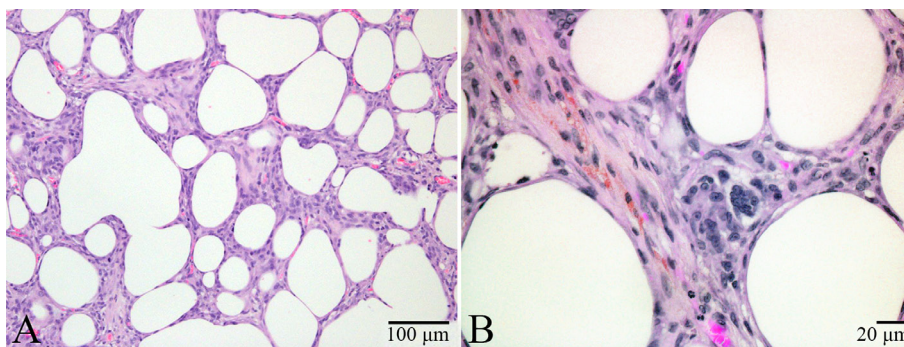
This is an open-access article distributed under the terms of the Creative Commons Attribution Non-Commercial No Derivatives (by-nc-nd) License. (CC-BY-NC-ND 4.0: <https://creativecommons.org/licenses/by-nc-nd/4.0/>)



**Fig. 1.** Ultrasonographic imaging of a spermatic cord mass. On the transverse image (A), a hyperechoic mass (arrow) is located in the left spermatic cord. On the longitudinal image (B), an elongated shaped mass (arrows) is cranial to the left testis.



**Fig. 2.** The sagittal (A, B) and dorsal plane CT (C, D) with contrast study (B, D). The left inguinal foramen is enlarged and filled with a fat-attenuating mass (arrowheads). This mass contains a partial soft-tissue attenuating lesion with contrast enhancement cranial to the left testis (arrows). This spermatic cord mass is elongated from the inguinal foramen to the left testis. There is no evidence of regional lymphatic metastasis.



**Fig. 3.** The histopathological section of the spermatic cord mass (A, B). The mass is composed of round to polygonal cells with little or no collagenous stroma. Most tumor cells resemble normal adipocytes, with a single fat vacuole and a peripheral nucleus. Other cells have variable- sized round to oval nuclei and abundant cytoplasm containing lipid droplets. Haematoxylin-eosin stain.

Preoperative diagnosis of LSCs in humans is uncommon, and a definitive diagnosis is made by histopathological or cytological examination [5, 11, 14–16]. On the basis of the World Health Organization classification, liposarcoma in humans is histologically categorized into five subtypes: well-differentiated, myxoid, round-cell, pleomorphic, and dedifferentiated. However, liposarcoma in dogs is categorized into three subtypes: well-differentiated, myxoid, and pleomorphic [6, 9, 19]. Well-differentiated liposarcomas are considered as less metastatic tumors [6]. Histologically, a well-differentiated liposarcoma can be subdivided into three subtypes: lipoma-like, sclerosing, and inflammatory. Many well-differentiated liposarcomas have areas of both lipoma-like and sclerosing subtypes. A typical lipoma-like liposarcoma is composed of adipocytes of variable sizes and a variable number of atypical stromal cells. These cells are more numerous in the fibrous septa and have multiple nuclei. The sclerosing subtype is generally observed in the retroperitoneum or paratesticular region, and there are scattered hyperchromatic stromal cells and multivacuolated lipoblasts in collagenous tissue [6]. In the present study, there was no metastasis, and the lesion consisted predominantly of adipocytes, with few or no atypical stromal cells, multinucleated giant cells, or multivacuolated lipoblasts, which was consistent with well-differentiated liposarcomas mainly lipoma-like or with sclerosing subtypes.

Diagnostic imaging such as ultrasound, CT or magnetic resonance imaging (MRI) has been used to diagnose LSCs in humans and provides useful information preoperatively, such as findings indicating a lipomatous nature of the mass and information regarding size and metastasis [3, 5, 10–12, 14–17]. Ultrasound examination could be helpful for confirming the margination and consistency of the mass and the status of the reproductive organ. In addition, it had several benefits, including cost-effectiveness and efficiency of the process. In humans, ultrasonography of LSC typically shows a solid, hyperechoic, heterogeneous mass separated from the testicle. This tendency was also observed in this case, with a hyperechoic spermatic cord mass cranial to a normal left testis.

Although definitive diagnosis of LSC is made by histopathological or cytological examination, there have been several attempts to identify liposarcoma subtypes in humans using diagnostic imaging modalities [3, 10, 12, 13, 17]. On CT and MRI, well-differentiated liposarcomas are mainly composed of fat tissue. Thick septa (>2 mm), soft-tissue nodules, or soft-tissue masses (<1 cm) could also be seen. Myxoid liposarcomas have a typical appearance on MRI. Multilobulated intramuscular masses are often seen as hypointense on T1-weighted and hyperintense on T2-weighted imaging with heterogeneous contrast enhancement. A round cell liposarcoma presents a non-specific, heterogeneous appearance on MRI that is often hard to distinguish from other high-graded soft-tissue sarcomas. Pleomorphic liposarcomas are observed as well-circumscribed masses that may contain little fat tissue on CT and MRI. Appearance on MRI is similar to that of other aggressive soft-tissue sarcomas. In the present case, the LSC showed as a fat-attenuating mass extending from the scrotum to the inguinal canal containing a soft-tissue attenuating lesion, which was consistent with the CT findings of a well-differentiated liposarcoma and its histological examination.

Due to local invasiveness of liposarcomas, wide excision of tumors is recommended. In a previous study of 56 dogs with liposarcomas, the median survival time was longer in dogs that underwent wide excision than in dogs that underwent marginal excision [2]. Similarly, in LSCs in humans, a radical orchiectomy with wide local excision and high ligation of the spermatic cord is recommended after diagnosis or preoperatively; retroperitoneal lymph node dissection is not indicated if there is no evidence of metastasis [5, 11, 14–16]. In the present case, the dog underwent a wide resection of the spermatic cord mass with a bilateral orchiectomy, and there was no evidence of metastasis. These conditions may suggest a good prognosis for this patient because of the early diagnosis and wide resection. Moreover, the patient has not had tumor recurrence or clinical problems over 15 months of follow-up.

To summarise, this study reported the first case of LSC in a dog. It should be noted that a liposarcoma could develop in the spermatic cord in dogs. Inguinal and scrotal masses should be preoperatively examined by diagnostic imaging to confirm the tumor margination and occurrence of metastasis. In addition, diagnostic imaging be performed to determine the liposarcoma subtype before surgery and histopathological examination. A wide excision of the LSC with orchiectomy is recommended for improved prognosis.

## REFERENCES

- Angew, D. W. and MacLachlan, N. J. 2017. Tumors of the genital systems. pp. 689–722. *In: Tumors in Domestic Animals*, 5th ed. (Meuten, D. J. ed), Wiley Blackwell, Iowa.
- Baez, J. L., Hendrick, M. J., Shofer, F. S., Goldkamp, C. and Sorenmo, K. U. 2004. Liposarcomas in dogs: 56 cases (1989–2000). *J. Am. Vet. Med. Assoc.* **224**: 887–891. [[Medline](#)] [[CrossRef](#)]
- Barile, A., Zugaro, L., Catalucci, A., Caulo, M., Di Cesare, E., Splendiani, A., Gallucci, M. and Masciocchi, C. 2002. Soft tissue liposarcoma: histological subtypes, MRI and CT findings. *Radiol. Med. (Torino)* **104**: 140–149. [[Medline](#)]
- Chang, S. C. and Liao, J. W. 2008. Mesojejunoileac liposarcoma with intrahepatic metastasis in a dog. *J. Vet. Med. Sci.* **70**: 637–640. [[Medline](#)] [[CrossRef](#)]
- Chintamani, T., Tandon, M., Khandelwal, R., Jain, S., Narayan, N., Kumar, Y. and Saxena, S. 2010. Liposarcoma of the spermatic cord: a diagnostic dilemma. *JRSM Short Rep.* **1**: 49. [[Medline](#)] [[CrossRef](#)]
- Dei Tos, A. P. 2000. Liposarcoma: new entities and evolving concepts. *Ann. Diagn. Pathol.* **4**: 252–266. [[Medline](#)] [[CrossRef](#)]
- Doster, A. R., Tomlinson, M. J., Mahaffey, E. A. and Jordan, C. W. 1986. Canine liposarcoma. *Vet. Pathol.* **23**: 84–87. [[Medline](#)] [[CrossRef](#)]
- Frase, R., Freytag, M., Baumgärtner, W. and Wohlsein, P. 2009. Metastasising liposarcoma of bone in a young dog. *Vet. Rec.* **164**: 372–373. [[Medline](#)] [[CrossRef](#)]
- Hendrick, M. J. 2017. Mesenchymal tumors of the skin and soft tissues of domestic animals. pp. 142–175. *In: Tumors in Domestic Animals*, 5th ed. (Meuten, D. J. ed), Wiley Blackwell, Iowa.
- Kim, T., Murakami, T., Oi, H., Tsuda, K., Matsushita, M., Tomoda, K., Fukuda, H. and Nakamura, H. 1996. CT and MR imaging of abdominal liposarcoma. *AJR Am. J. Roentgenol.* **166**: 829–833. [[Medline](#)] [[CrossRef](#)]

11. Li, F., Tian, R., Yin, C., Dai, X., Wang, H., Xu, N. and Guo, K. 2013. Liposarcoma of the spermatic cord mimicking a left inguinal hernia: a case report and literature review. *World J. Surg. Oncol.* **11**: 18. [[Medline](#)] [[CrossRef](#)]
12. Ohguri, T., Aoki, T., Hisaoka, M., Watanabe, H., Nakamura, K., Hashimoto, H., Nakamura, T. and Nakata, H. 2003. Differential diagnosis of benign peripheral lipoma from well-differentiated liposarcoma on MR imaging: is comparison of margins and internal characteristics useful? *AJR Am. J. Roentgenol.* **180**: 1689–1694. [[Medline](#)] [[CrossRef](#)]
13. O'Regan, K. N., Jagannathan, J., Krajewski, K., Zukotynski, K., Souza, F., Wagner, A. J. and Ramaiya, N. 2011. Imaging of liposarcoma: classification, patterns of tumor recurrence, and response to treatment. *AJR Am. J. Roentgenol.* **197**: W37–43. [[Medline](#)] [[CrossRef](#)]
14. Parray, F. Q., Dar, R. A., Chowdri, N. A., Hamid, A. and Malik, R. A. 2011. Liposarcoma of the spermatic cord: a rare entity. *Case Rep. Urol.* **2011**: 572973. [[Medline](#)]
15. Read, R. C. and Schaefer, R. F. 2000. Lipoma of the spermatic cord, fatty herniation, liposarcoma. *Hernia* **4**: 149–154. [[CrossRef](#)]
16. Schwartz, S. L., Swierzewski, S. J. 3rd., Sondak, V. K. and Grossman, H. B. 1995. Liposarcoma of the spermatic cord: report of 6 cases and review of the literature. *J. Urol.* **153**: 154–157. [[Medline](#)] [[CrossRef](#)]
17. Unal, B., Bilgili, Y. K., Batislam, E. and Erdogan, S. 2004. Giant dedifferentiated retroperitoneal liposarcoma: CT and MRI findings. *Eur. J. Radiol. Extra* **51**: 47–50. [[CrossRef](#)]
18. Wang, F. I., Liang, S. L., Eng, H. L., Jeng, C. R. and Pang, V. F. 2005. Disseminated liposarcoma in a dog. *J. Vet. Diagn. Invest.* **17**: 291–294. [[Medline](#)] [[CrossRef](#)]
19. Weiss, S. W. 1994. Lipomatous tumours. pp. 23–25. *In*: Histological Typing of Soft Tissue Tumours. World Health Organization International Histological Classification of Tumours, 2nd ed. (Weiss, S. W. ed.), Springer-Verlag, New York.