



## NOTE

Pathology

# Well-differentiated liposarcoma with chondroid metaplasia in the auricle of a dog

Nagi TOMITA<sup>1,2)</sup>, Yuji SUNDEN<sup>1)</sup>, Yoshiharu OKAMOTO<sup>3)</sup> and Takehito MORITA<sup>1)\*</sup>
<sup>1)</sup>Department of Veterinary Pathology, Tottori University, Tottori, Tottori 680-8553, Japan

<sup>2)</sup>The United Graduate School of Veterinary Science, Yamaguchi University, Yamaguchi, Yamaguchi 753-8511, Japan

<sup>3)</sup>Department of Veterinary Surgery, Tottori University, Tottori, Tottori 680-8553, Japan

*J. Vet. Med. Sci.*

79(7): 1236–1239, 2017

doi: 10.1292/jvms.17-0168

Received: 30 March 2017

Accepted: 24 May 2017

Published online in J-STAGE:  
11 June 2017

**ABSTRACT.** A 13-year-old spayed female dog had a mass in the left auricle. Grossly, connection between the mass and original auricular cartilage was not recognized. The mass was unencapsulated and contained multiple islands of mature hyaline cartilage and neoplastic adipocytes. The neoplastic cells comprised predominant mature adipocytes, scattered lipoblasts and irregular round to spindle cells with moderate atypia. The atypical cells occasionally had lipid droplets. A diagnosis of well-differentiated liposarcoma (WDL) with chondroid metaplasia was made. This is the first report for liposarcoma with chondroid metaplasia in the auricle of domestic animals.

**KEY WORDS:** auricle, chondroid metaplasia, well-differentiated liposarcoma

Liposarcoma is a malignant tumor of adipocytes that is rare in domestic animals. In dogs, most liposarcomas occur in the subcutaneous tissue, especially in the shoulder region, thorax, axilla, tail base, hip region or extremities; however, there have been no reports on its occurrence in the auricle [2]. Histologically, liposarcomas in domestic animals can be classified into three subtypes: well-differentiated, pleomorphic and myxoid liposarcomas [5]. Well-differentiated liposarcomas (WDL) are characterized by predominant mature adipocytes and varying numbers of lipoblasts and atypical adipocytes, intersected by fibrous or myxoid tissue [3, 6, 8]. To our knowledge, liposarcoma with chondroid metaplasia has not been reported in domestic animals, while there have been some reports of cases of lipoma with chondroid metaplasia [1, 9–11]. In this report, we document a canine case of WDL with chondroid metaplasia in the auricle.

A 13-year-old spayed female Labrador Retriever was presented to the Animal Hospital of Tottori University for a clinical examination of a mass of the left auricle. The mass had not cured completely, despite prior operations. Upon clinical examination, the mass (4 × 3 × 3 cm) was located in the lateral region of the left auricle, and the surface skin showed alopecia (Fig. 1). In addition to the auricle, multiple masses (maximum: about 10 cm in diameter) were detected in another part of the systemic subcutaneous tissue. One of the masses was diagnosed as lipoma by cytodiagnosis. Computed tomography (CT) confirmed scattered nodules in the lung and a large mass in the liver. Some nodules in the lung showed calcification. Ultrasonography revealed that the echogenicity of the hepatic mass was equal to that of the normal hepatic parenchyma. The blood test revealed a mild increase in the rate of neutrophils (Seg: 80%, Stab: 8%) and a decrease in the rate of lymphocytes (7%). Serum biochemical analysis revealed an increase in the level of ALP (411 U/l). An excision of the auricle mass was performed, which revealed that the mass was grossly well-demarcated from the auricular cartilage. The mass was completely excised. There was no recurrence in subsequent 4 months.

The auricular mass was fixed in 10% neutral buffered formalin, immersed in xylene and ethanol, and then embedded in paraffin. Paraffin sections were made from the tissue, and stained with hematoxylin and eosin (HE), Masson trichrome, toluidine blue and immunohistochemical staining. For immunohistochemical staining, the following antibodies were used: anti-vimentin (1/100, YLEM, Rome, Italy), anti-S100 (1/500, Dako, Kyoto, Japan), anti-cytokeratin (AE1/AE3, 1/100, Dako) and anti-Ki 67 (MIB-1, 1/100, Dako). Antibody staining was visualized using 3-3'-diaminobenzidine (Dako) on hematoxylin-counterstained sections.

Grossly, the cut surface of the mass was yellow-white and multilobulated. Histopathologically, the mass was located at the subcutaneous tissue and unencapsulated. It was composed of multiple islands of mature hyaline cartilage and neoplastic adipocytes with fibrous septa (Fig. 2). The majority of the neoplastic cells were mature adipocytes with single large lipid vacuoles and peripheral nuclei, occasionally showing mild atypia. There were multivacuolated cells among the mature adipocytes. Some of them

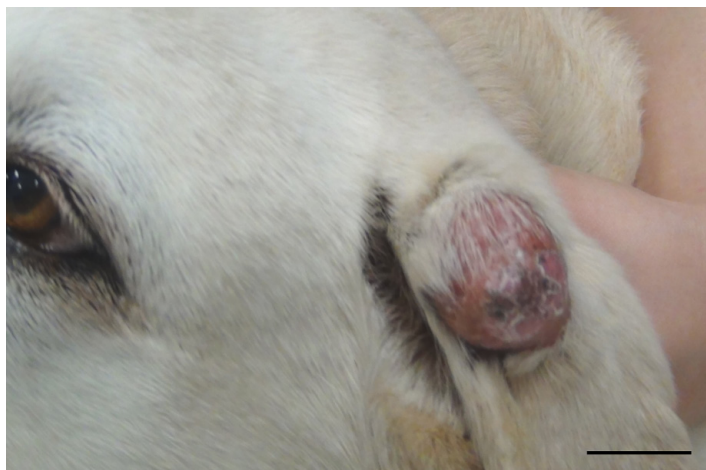\*Correspondence to: Morita, T., Department of Veterinary Pathology, Tottori University, Tottori, Tottori 680-8553, Japan.

e-mail: morita@muses.tottori-u.ac.jp

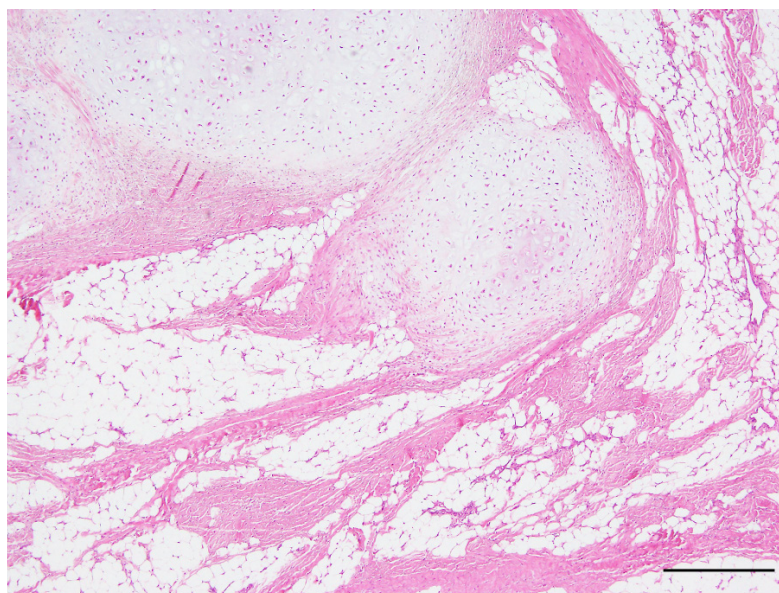
©2017 The Japanese Society of Veterinary Science



This is an open-access article distributed under the terms of the Creative Commons Attribution Non-Commercial No Derivatives (by-nc-nd) License. (CC-BY-NC-ND 4.0: <https://creativecommons.org/licenses/by-nc-nd/4.0/>)



**Fig. 1.** The mass is located in the lateral and proximal part of the left auricle. The surface skin is alopecic, reddened and escharotic. Bar=3 cm.

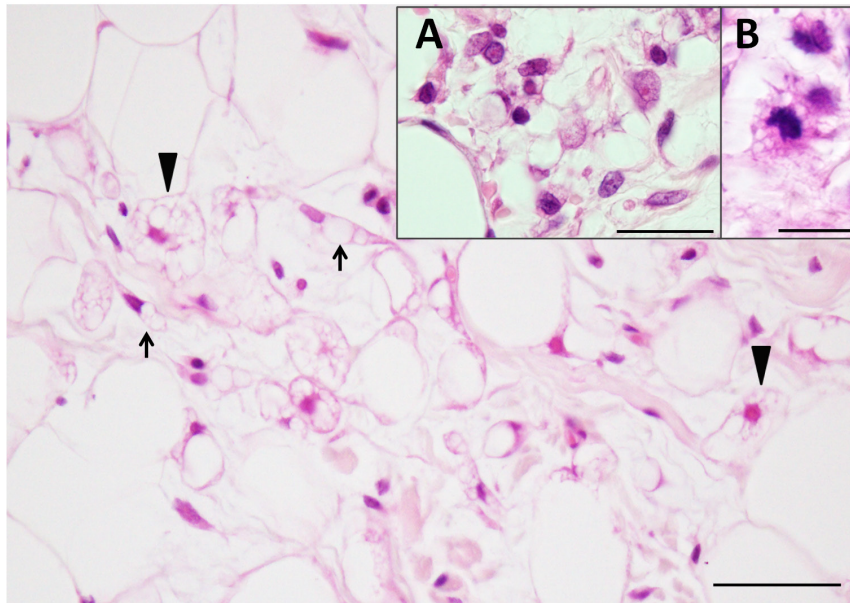


**Fig. 2.** The mass is composed of multiple islands of mature hyaline cartilage and predominant mature adipocytes separated by collagenous septa. Bar=500  $\mu$ m.

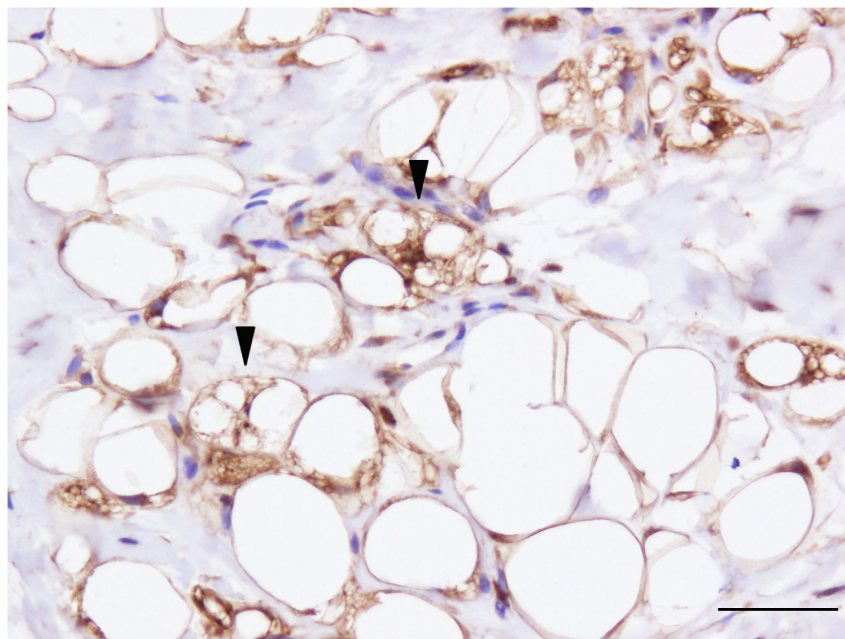
were typical lipoblasts showing a round shape and central nuclei. Others presented an irregular-round to spindle shape and round, oval or spindle-shaped nuclei, showing moderate atypia. These cells occasionally showed anisokaryosis and mitotic figures (Fig. 3). The neoplastic cells showed mild infiltrative proliferation to the marginal subcutaneous tissue. Mild and focal hemorrhage and necrosis of the adipose tissue were observed. The auricular cartilage was not recognized in the mass and the marginal tissue. The multiple islands of mature cartilage showed metachromasy with toluidine blue stain. The fibrous septa stained blue with Masson trichrome stain, which indicated that they were composed of collagenous tissue. Immunohistochemically, positive signals for vimentin and S100 were detected in the mature adipocytes, lipoblasts, atypical cells and chondrocytes (Fig. 4), whereas these cells were negative for cytokeratin. Ki-67 immunolabeling was also detected in the nuclei of some atypical cells.

WDL is characterized by predominant mature adipocytes, varying numbers of lipoblasts, atypical adipocytes and spindle cells in human and animals [3, 6, 8]. Immunohistochemically, adipocytes and lipoblasts are positive for vimentin, S100 and occasionally positive for Ki-67 and negative for cytokeratin in human cases of WDL [4, 7]. The histopathological and immunohistochemical findings of the present case correspond to those in WDLs.

The differential diagnosis for this case includes lipoma, infiltrative lipoma, chondrolipoma and chondroid lipoma. The histopathology of WDLs resembles that of lipoma and infiltrative lipoma: however, in these tumors, lipoblasts and atypical adipocytes are not seen [7, 8]. Based on these findings, the diagnosis of lipoma and infiltrative lipoma can be excluded for the present case.



**Fig. 3.** Lipoblasts (arrowheads) and spindle cells which contain lipid droplets in the cytoplasm (arrows) are recognized. Bar=50 $\mu$ m. Insertion figure A: Cells have round, oval or spindle-shape nuclei and show anisokaryosis. Bar=20  $\mu$ m. Insertion figure B: Minimal lipid droplets are seen in the mitotic cell. Bar=10  $\mu$ m.



**Fig. 4.** Immunohistochemical analysis for S100. Mature adipocytes and lipoblasts (arrowheads) are positive for S100. Bar=50 $\mu$ m.

In the present case, the cartilage components were arranged in multiple islands, which differed from that of the auricular cartilage. Additionally, they showed limited atypia and did not invade the auricular cartilage. Based on these findings, the cartilage component of the tumor may have derived from chondroid metaplasia of the neoplastic adipose tissue rather than from neoplastic chondrocytes or the auricular cartilage. In dogs, some lipoma cases showed chondroid metaplasia, which were described as chondrolipoma [1, 9–11]. Chondrolipomas do not contain lipoblasts and atypical cells, in contrast to this case. To our knowledge, there have been no reports on liposarcoma with chondroid metaplasia in animals [3].

Chondroid lipoma in human is a rare fatty tumor that is composed of multivacuolated cells resembling lipoblasts, abundant adipocytes and myxochondroid matrix [12]. Chondroid lipoma showed extensive myxochondroid matrix without chondrocytes among the neoplastic adipocytes and lacked mature cartilage, whereas this case showed multiple islands of mature cartilage tissue



among the neoplastic adipose tissue [12]. On the basis of these findings, this case cannot be diagnosed as chondroid lipoma.

In the present case, WDL in the auricle coexisted with systemic masses, one of which was diagnosed as a lipoma. Because WDLs rarely metastasize [2] and the systemic masses in this case might be benign, it seems that these masses occurred multifocally rather than metastatically. A previous study demonstrated that the rate of coexistence of lipoma with WDL cases was significantly higher than in other liposarcoma subtypes and that identical genetic backgrounds were involved in the tumorigenesis of lipomas and WDLs in humans [4]. Therefore, it seems that the genetic background may be responsible for the pathogenesis of the present case.

## REFERENCES

1. Asproni, P., Millanta, F. and Poli, A. 2012. A mammary gland chondrolipoma in the dog. *J. Vet. Diagn. Invest.* **24**: 1017–1020. [[Medline](#)] [[CrossRef](#)]
2. Baez, J. L., Hendrick, M. J., Shofer, F. S., Goldkamp, C. and Sorenmo, K. U. 2004. Liposarcomas in dogs: 56 cases (1989–2000). *J. Am. Vet. Med. Assoc.* **224**: 887–891. [[Medline](#)] [[CrossRef](#)]
3. Evans, H. L. 1979. Liposarcoma: a study of 55 cases with a reassessment of its classification. *Am. J. Surg. Pathol.* **3**: 507–523. [[Medline](#)] [[CrossRef](#)]
4. Hatano, H., Morita, T., Ogose, A., Hotta, T., Kobayashi, H. and Honma, K. 2004. Well-differentiated liposarcoma associated with benign lipoma. *Anticancer Res.* **24** 2C: 1039–1044. [[Medline](#)]
5. Hendric, M. J., Mahaffey, E. A., Moore, F. M., Vos, J. H. and Walder, E. J. 1998. Histological classification of mesenchymal tumors of skin and soft tissues of domestic animals, second series volume 2, the Armed Forces Institute of Pathology, Washington, D. C.
6. Kooby, D. A., Antonescu, C. R., Brennan, M. F. and Singer, S. 2004. Atypical lipomatous tumor/well-differentiated liposarcoma of the extremity and trunk wall: importance of histological subtype with treatment recommendations. *Ann. Surg. Oncol.* **11**: 78–84. [[Medline](#)] [[CrossRef](#)]
7. Mentzel, T. and Fletcher, C. D. 1995. Lipomatous tumours of soft tissues: an update. *Virchows Arch.* **427**: 353–363. [[Medline](#)] [[CrossRef](#)]
8. Meuten, D. J. 2002. Tumors in Domestic Animals, 4th ed., Iowa State Press, Ames.
9. Mutinelli, F., Vascellari, M., Melchioti, E., Bigolaro, M. and Bozzato, E. 2007. Intra-pelvic chondrolipoma in a dog. *J. Comp. Pathol.* **137**: 160–164. [[Medline](#)] [[CrossRef](#)]
10. Ramirez, G. A., Altimira, J., García, B. and Vilafranca, M. 2010. Chondro-osteoblastic metaplasia in canine benign cutaneous lipomas. *J. Comp. Pathol.* **142**: 89–93. [[Medline](#)] [[CrossRef](#)]
11. Tanabe, S., Yamada, K., Kobayashi, Y., Suzuki, K., Yamaguchi, M., Uzuka, Y., Sarashina, T. and Inoue, M. 2005. Extra-abdominal chondrolipoma in a dog. *Vet. Radiol. Ultrasound* **46**: 306–308. [[Medline](#)] [[CrossRef](#)]
12. Thway, K., Flora, R. S. and Fisher, C. 2012. Chondroid lipoma: an update and review. *Ann. Diagn. Pathol.* **16**: 230–234. [[Medline](#)] [[CrossRef](#)]