

Article

Spontaneous regression of extruded lumbar disc herniation: case report and its pathogenesis

Prajapati Hanuman Prasad, Singh Deepak Kumar, Singh Rakesh Kumar, Ahmed Faran
INDIA



DE GRUYTER
OPEN

Spontaneous regression of extruded lumbar disc herniation: case report and its pathogenesis

Prajapati Hanuman Prasad, Singh Deepak Kumar, Singh Rakesh Kumar, Ahmed Faran

Department of Neurosurgery, DR RML IMS, Lucknow, UP, INDIA

Abstract: Lumbar disc herniation is a common disease that present with back pain and radicular pain. The most efficient method for the treatment of lumbar disc herniation is still controversial. Spontaneous regression of lumbar disc herniation has been recognized with the advancement of radiological diagnostic tools and can explain the reason of spontaneous relief of symptoms without treatment. The proposed hypothesis are; dehydration, retraction of the disc herniation in the annulus fibrosus, enzymatic catabolism and phagocytosis. In this study we present a case with large lumbar disc herniation regressing by itself and the potential mechanisms of disc regression have been discussed.

Key words: intervertebral disc herniation, spontaneous regression, pathogenesis

Introduction

Lumbar disc herniation is a common disease presenting with low back pain and radiculopathy. Some cases require surgical treatment due to persistent severe pain however in other cases pain relieved with conservative treatment. This occurs as the result of decrease in pressure exerted from the herniated disc on neighbouring neuro structures and a gradual regression of inflammation. Recently with advances in magnetic resonance imaging many reports have demonstrated that the herniated disc has the potential for spontaneous regression. Regression coincided with the improvement of

associated symptoms. However the exact mechanism for regression is remains unclear.

Here, we present a cases of lumbar disc herniation with spontaneous regression. We review the literature and discuss the possible mechanisms, the precipitating factors of spontaneous disc regression and the proper timing of surgical intervention.

Case report

A 52 years old female patient presented with 5month history of back pain radiating in the left lower extremity. Neurological examination showed no abnormality except a positive left straight leg raising test. MRI

lumbosacral spine revealed a left posterolateral disc extrusion at L5-S1 level (figures 1A and 1B). Patient was advised for surgery but she refused. Conservative treatment including bed rest, physiotherapy, nonsteroidal anti-inflammatory drugs, and analgesics was advised. Patient was on regular follow up on OPD basis. Gradually patient improved within 5-6 months and after 6month repeat MRI of lumbosacral spine was done. It showed regression of previously extruded disc at L5-S1 level (figures 2A and 2B).

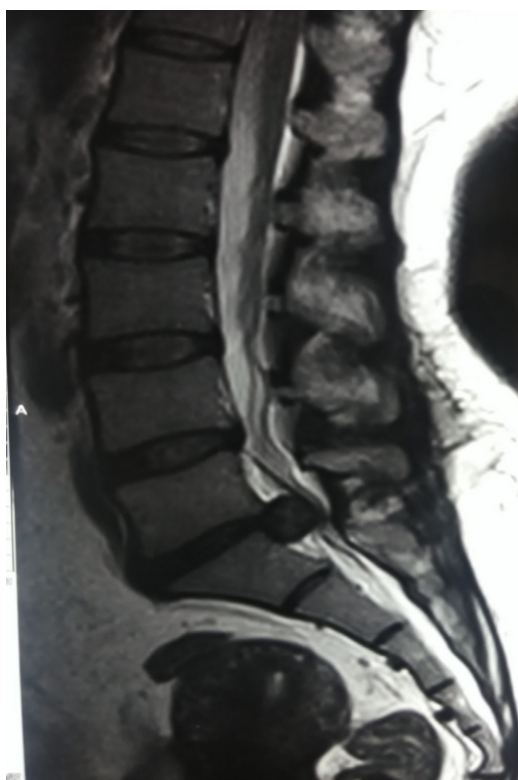

Figure 1A - MRI lumbosacral spine sagittal section showing extruded disc at L5-S1 level

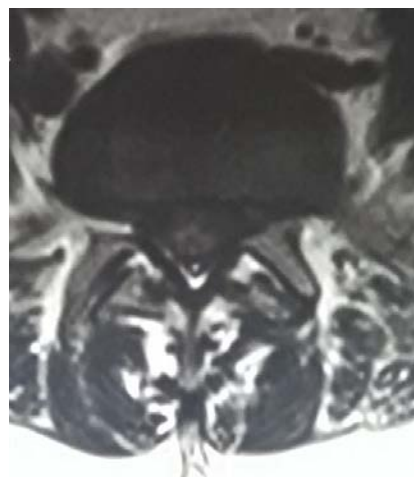


Figure 1B - MRI lumbosacral spine axial section showing left paracentral disc herniation at L5-S1 level

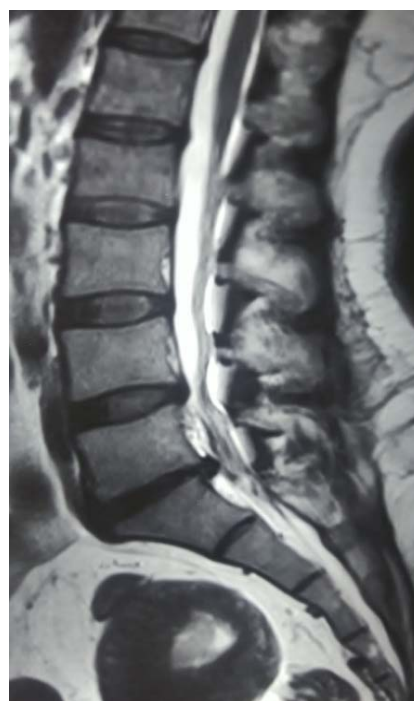

Figure 2A - Repeat MRI lumbosacral spine sagittal section showing regression of previously extruded disc at L5-S1 level

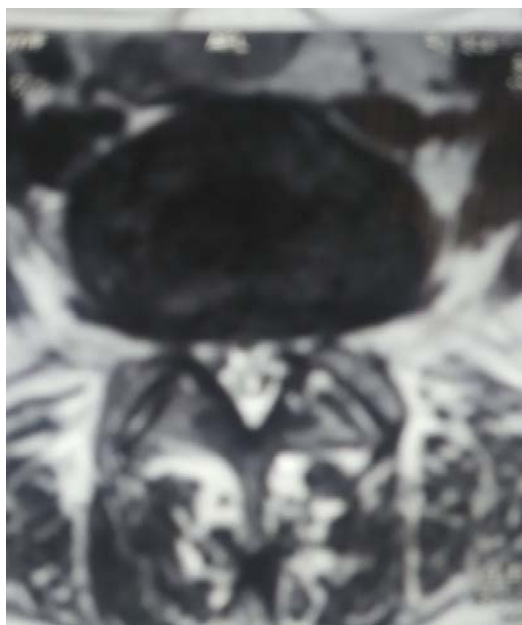


Figure 2B - MRI lumbar spine axial section showing regression of previous left paracentral disc herniation at L5-S1 level

Discussion

Lumbar disc herniation is one of the common cause of low back pain. Conservative management including bed rest, oral anti-inflammatory drugs, analgesics and physiotherapy is recommended for treatment of lumbar disc herniations [1]. Surgical intervention is advised in the absence of resolution of symptom in two months or presence of cauda equina syndrome, motor weakness or progressive deficit while being medically managed [2]. The potential for regression of disc herniation had been occasionally reported and it leads to questioning of the choosing the treatment modality. Although extensive documentations are found in the literature, the mechanisms proposed for regression of disc herniation are

still incomplete.

Dehydration within the nucleus pulposus and shrinkage, a mechanical retraction of herniated disc material back into the annulus fibrosus, and enzymatic degradation and phagocytic reduction via immunohistologic mediators are three popular mechanisms assumed in the literature. The second mechanism mechanical retraction of the herniated disc is a theoretical assumption expected to occur when the disc herniation protrudes through the annulus fibrosus by preserving anatomical relation. Third mechanism which has been studied by many authors depends on a series of inflammatory responses of autoimmune system, including neovascularization, production of matrix proteinases, increasing of cytokines levels, enzymatic degradation, and macrophage phagocytosis [3].

Pathogenesis

Histological studies had shown an inflammatory reaction around the herniated nucleus pulposus. Local production of TNF alpha by schwann cells, endothelial cells, fibroblasts and mast cells attracts macrophages to the site of injury [4]. Neovascularisation had also been reported at the edge of herniated nucleus pulposus. Both inflammation and neovascularisation are thought to be required for phagocytosis. Macrophage infiltration seems to be prominent in large disc herniations, as sequestrations have 2-3 times more inflammatory cells than extrusion type herniations[5]. Neovascularisation is also most abundant in extrusions and sequestrations and is hindered by ligaments and/or annulus fibrosus. Therefore it is seen

that both generalized and localized bulges have the poorest potential to regress. In other type of patients, in addition to mechanical compression, biochemical substances released by the disc, such as phospholipase A2 and nitric oxide, have been thought to play a role in nerve inflammation and pain which may persist after the resolution of disc herniation [6].

Neovascularization in the outermost areas of herniated nucleus pulposus (HNP) presenting an enhancing rim in MR images, is thought to be a major determinant of spontaneous regression of HNP. At MR image, the neovascularization is easily detected by contrast enhancement. However the degree of neovascularization is varied. Newly developed vessels in and around HNP play an important role in the wound healing process and resorption of HNP. Neovascularization was observed at the periphery of the sequestered discs. Enhanced lesion at periphery of herniated disc is considered to represent inflammatory granulation. Inflammatory cells are most commonly seen in the sequestered type HNP. There was prominent infiltration of the inflammatory cells in the periphery of the extruded or sequestered discs and most of them are macrophages. Macrophages are observed only in the periphery of the disc fragments [7]. Tumor necrosis factor (TNF)- α was the initiator of the inflammation, following contact between the macrophages and disc tissue. TNF- α could also act to accelerate the cascade of both angiogenesis and matrix degradation [8].

On reviewing the literature we found that thickness of rim enhancement is a more

important factor to spontaneous regression than the extent of rim enhancement. When rim enhancement is present on enhanced MR images, there is a possibility of spontaneous regression even though the herniated mass may be located within the intradural space [9]. The ratio of reduction in size of enhancing lesions is even higher in T2 hyperintense herniations. The relatively-high water content can be the expression of soft, well-hydrated disc material or even an edema related to neovascularization and inflammatory reaction [10]. MR images are considered as a useful tool to predict the spontaneous regressive potential of HNP.

Spontaneous regression of disc is seen occasionally. Therefore, non-surgical treatment can be another therapeutic option to treat HNP, when the patients did not want surgical treatment or if there is no neurological deficit. The presenting patient refuse surgical treatment and regression of disc is seen after conservative treatment.

Conclusion

Spontaneous regression of HNP is rare condition. Conservative treatment may be an option if the patient did not wants surgical treatment and have no motor weakness, bladder symptoms and tolerable pain, even though the size of herniated disc is large.

Correspondence

Dr. Hanuman Prasad Prajapati

Address: Department of Neurosurgery, DR RML

IMS, Lucknow, UP (India)

Mobile No.: 07727934104

Email: pushpa84.dhp@gmail.com

References

1. Macki M., Hernandez-Hermann M., Bydon M., Gokaslan A., McGovern K., Bydon A. Spontaneous regression of sequestered lumbar disc herniations: literature review. *Clinical Neurology and Neurosurgery*. 2014;120:136–141. doi: 10.1016/j.clineuro.2014.02.013. [PubMed] [Cross Ref]
2. Rahmathulla G., Kamian K. Lumbar disc herniations ‘to operate or not’ patient selection and timing of surgery. *Korean Journal of Spine*. 2014;11(4):255–257. doi: 10.14245/kjs.2014.11.4.255. [PMC free article][PubMed] [Cross Ref]
3. Guinto F. C., Jr., Hashim H., Stumer M. CT demonstration of disk regression after conservative therapy. *American Journal of Neuroradiology*. 1984;5(5):632–633. [PubMed]
4. Olmarker K & Larsson K. Tumor necrosis factor alpha and nucleus-pulposus- induced nerve root injury. *Spine* 1998;23:2538–44.
5. Ozaki S, Muro T, Ito S & Mizushima M. Neovascularisation of the outermost area of herniated lumbar intervertebral discs. *J Orthop Sci* 1999;4:286–92.
6. Virri J, Gronblad M, Seitsalo S, Habtemariam A, Kappa E & Karaharju E. Comparison of the prevalence of inflammatory cells in subtypes of disc herniations and associations with straight leg raising. *Spine* 2001;26:2311–5.
7. Autio RA, Karppinen J, Niinimäki J, Ojala R, Kurunlahti M, Haapea M, et al. Determinants of spontaneous resorption of intervertebral disc herniations. *Spine (Phila Pa 1976)* 2006;31(11):1247–1252. [PubMed]
8. Ikeda T, Nakamura T, Kikuchi T, Umeda S, Senda H, Takagi K. Pathomechanism of spontaneous regression of the herniated lumbar disc: histologic and immunohistochemical study. *J Spinal Disord*. 1996;9(2):136–140. [PubMed]
9. Kato T, Haro H, Komori H, Shinomiya K. Sequential dynamics of inflammatory cytokine, angiogenesis inducing factor and matrix degrading enzymes during spontaneous resorption of the herniated disc. *J Orthop Res*. 2004;22:895–900. [PubMed]
10. Splendiani A, Puglielli E, De Amicis R, Barile A, Masciocchi C, Gallucci M. Spontaneous resolution of lumbar disk herniation: predictive signs for prognostic evaluation. *Neuroradiology*. 2004;46:916–922. [PubMed]