



NOTE

Surgery

Computed tomography angiography reveals stenosis and aneurysmal dilation of an aberrant right subclavian artery causing systemic blood pressure misreading in an old Pekinese dog

Jaehwan KIM¹⁾, Kidong EOM¹⁾ and Hakyoung YOON^{1)*}

¹⁾Department of Veterinary Medical Imaging, College of Veterinary Medicine, Konkuk University, 120, Neungdong-ro, Gwangjin-gu, Seoul 05029, Korea

J. Vet. Med. Sci.
79(6): 1052–1055, 2017
doi: 10.1292/jvms.17-0031

Received: 24 January 2017
Accepted: 4 April 2017
Published online in J-STAGE:
11 May 2017

ABSTRACT. A 14-year-old dog weighing 4 kg presented with hypotension only in the right forelimb. Thoracic radiography revealed a round soft tissue opacity near the aortic arch and below the second thoracic vertebra on a lateral view. Three-dimensional computed tomography angiography clearly revealed stenosis and aneurysmal dilation of an aberrant right subclavian artery. Stenosis and aneurysm of an aberrant subclavian artery should be included as a differential diagnosis in dogs showing a round soft tissue opacity near the aortic arch and below the thoracic vertebra on the lateral thoracic radiograph.

KEY WORDS: aneurysm, CT angiography, hypotension, subclavian artery stenosis, vascular ring anomaly

Aberrant right subclavian arteries can cause regurgitation and consecutive aspiration pneumonia [14]. Aberrant right subclavian arteries are rare and to date, only 11 cases have been reported [1–3, 5, 8, 11, 13, 14]. Only two cases of aberrant right subclavian artery with clinical signs and with late-onset regurgitation in 2- and 10-year aged dogs have been reported [8, 14]. In addition, there has been only 1 case [14] with an abrupt bending region among the cases reported to date [1–3, 5, 8, 11, 13, 14]. However, there have been no cases that reported a hypotension of the right forelimb due to the abrupt bending region of the aberrant right subclavian artery.

This report describes the radiographic and computed tomographic features in a dog with stenosis and aneurysm of an aberrant right subclavian artery which caused hypotension only in the right forelimb among the four extremities.

A 14-year-old spayed female Pekinese dog weighing 4 kg presented with systemic hypotension with a peak systolic pressure of approximately 58–63 mmHg only in the right forelimb among the four extremities. Blood pressure was measured times in quintuplicate, 3 times a day, and weekly for 4 weeks at the heart level in the sitting posture. Three extremities except for the right forelimb showed normotension for systolic blood pressure (90–120 mmHg; reference range 90–140 mmHg) on blood pressure estimation using Doppler ultrasonography. None of the extremities presented a cold feeling. There were no clinical signs of depression, anorexia, or exercise intolerance. There were no abnormal findings on other physical examinations and auscultation of the heart and lungs. Aspartate aminotransferase findings were abnormal (165 mg/dl; reference range 0–50 mg/dl). A complete blood count revealed neutrophilia (20,620/ μ l; reference range 2,950–11,640/ μ l) and monocytosis (1,230/ μ l; reference range 160–1,120/ μ l), reflecting stress leukogram. The D-dimer was normal (0.09 μ g/ml; reference range 0.08–0.39 μ g/ml).

Thoracic radiographs were obtained in a routine manner (Titan 2000M; ComedMedical Systems Co., Ltd., Seoul, Korea). Thoracic radiography revealed a bulge on the craniodorsal aspect of the cardiac silhouette on a lateral view (Fig. 1A). In addition, a round soft tissue opacity of approximately 7–8 mm was reproducibly detected just below the second thoracic vertebra on repeatedly acquired lateral radiographs. A widening of the precardiac mediastinum and a protruded soft tissue opacity at the cranial and left aspect of the cardiac silhouette was identified on a ventrodorsal view (Fig. 1B). Echocardiography revealed no remarkable findings.

Computed tomography (CT) angiography was performed with a 4-multi-detector-row system (LightSpeed; GE Medical Systems, Milwaukee, WI, U.S.A.). Imaging protocols were 120 kVp, 200 mAs, 512 \times 512 matrix, and a 0.6 rotation time with

*Correspondence to: Yoon, H., Department of Veterinary Medical Imaging, College of Veterinary Medicine, Konkuk University, 120, Neungdong-ro, Gwangjin-gu, Seoul, Korea. e-mail: knighttt7240@gmail.com

©2017 The Japanese Society of Veterinary Science



This is an open-access article distributed under the terms of the Creative Commons Attribution Non-Commercial No Derivatives (by-nc-nd) License. (CC-BY-NC-ND 4.0: <https://creativecommons.org/licenses/by-nc-nd/4.0/>)

a 1.25-mm slice thickness. For contrast examination, iohexol (Omnihexol 300; Korea United Pharmaceutical, Seoul, Korea) at 600 mg of iodine/kg was injected manually into the cephalic vein with a 60 sec delay. All images were imported and reviewed by two radiologists using free software (Osirix DICOM viewer; Pixmeo, Los Angeles, CA, U.S.A.). Images using a resample slice thickness of 0.3125 mm were acquired. Maximal intensity projection and three-dimensional (3D) volume rendered images were acquired to estimate vascular abnormalities.

On a CT angiography, a vascular deformity with an abnormal origin was detected at the second to third thoracic vertebrae (Fig. 2). A brachiocephalic trunk was the first vessel that originated from the normal left aortic arch and the left subclavian artery was the second. The third vessel from the aorta was an aberrant right subclavian artery that directly originated from a normal aortic arch. The origin of the aberrant artery was located on the dorsomedial surface of the aortic arch and adjacent to the left subclavian artery (approximately 1.25 mm). The aberrant artery curved and traveled in a left lateral and dorsal direction, passing the left lateral surface of the esophagus. The artery then bent abruptly toward the cranium on the right, making two bending points at locations of 17 and 19.82 mm from its origin. Afterwards, the artery obliquely traveled toward the right forelimb, passing over the dorsal surface of the trachea and esophagus. A complete vascular ring wrapping the esophagus was not formed.

The maximal intensity projection and 3D volume rendering images revealed anatomical characteristics of an aberrant right subclavian artery with 2 bending points and an aneurysmal dilation (Fig. 3). The aberrant artery's bending points showed stenotic appearances with smaller short axis diameters (2–2.5 mm) than the left subclavian artery (4–4.5 mm) and the aberrant artery's non-bending region (4–5 mm). The esophagus was compressed by the aneurysmal dilation between the origin of the artery and the first bending point. Although a mild dilation was identified between the first and second bending point, the vessel distal to the second bending point had a similar diameter to the normal left subclavian artery. The diameter of the right subclavian artery was smaller in the distal region than that of the left subclavian artery. Any thrombi that could have caused the hypotension of the right forelimb were not detected within the aberrant artery. A collateral circulation of the aberrant right subclavian artery was also not identified. Based on these radiography and CT findings, diagnosis of an aberrant right subclavian artery with stenosis and an aneurysmal dilation was made in the dog.

The dog's owner did not agree with a decision to perform a surgical bypass of the aberrant artery, and thus dietary habit correction was recommended to prevent a possible regurgitation. At a 6-month follow-up after the diagnosis, there was no regurgitation and the hypotension of the right forelimb was still present; however, clinical signs that are typically associated with hypotension of the right forelimb had not developed.

Compared to a previous study that described a bending region of the aberrant right subclavian artery [14], this study presented more severe stenotic regions due to a more abrupt bending angle and two bending points, resulting in hypotension by circulatory disorder. A human study introduced a hypotension case due to subclavian artery stenosis [12]. The hypotension in this study may have been influenced by the stenotic appearance due to the bending region. The cause of the bending region was unclear. However, the bending region might be acquired because the hypotension due to the stenotic region was identified for the first time recently. Long-term bending force by the abnormal running course of the aberrant artery might have caused the structural deformations [14].

The aneurysmal dilation at the root of the aberrant right subclavian artery might be congenital or acquired. If the aneurysm is congenital, it might be Kommerell diverticulum, which is an embryologic remnant of the right aortic arch, as mentioned in human studies [7, 9]. If the aneurysm is acquired, it might be due to the bending root of the aberrant right subclavian artery [14]. Although

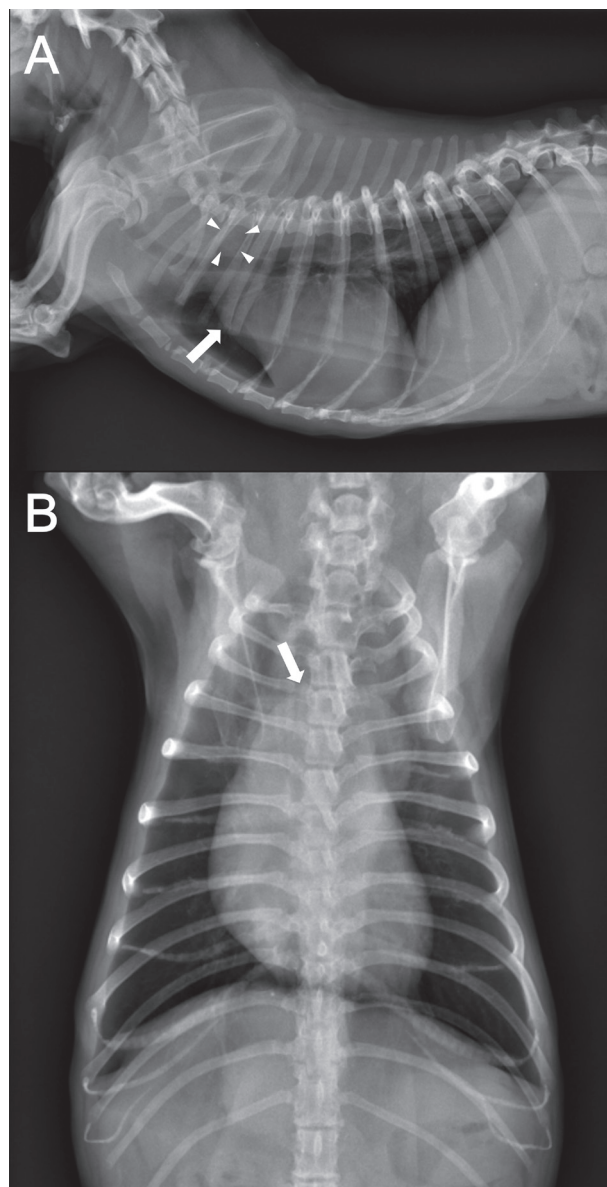


Fig. 1. Right lateral and ventrodorsal view on a radiograph. (A) Right lateral radiograph showing a round soft tissue opacity (arrowheads) below the second thoracic vertebra and a bulge (arrow) on the craniodorsal aspect of the cardiac silhouette. (B) Ventrodorsal radiograph showing a widening of the precardiac mediastinum and a protruded soft tissue opacity (arrow) at the cranial and left aspect of the cardiac silhouette.

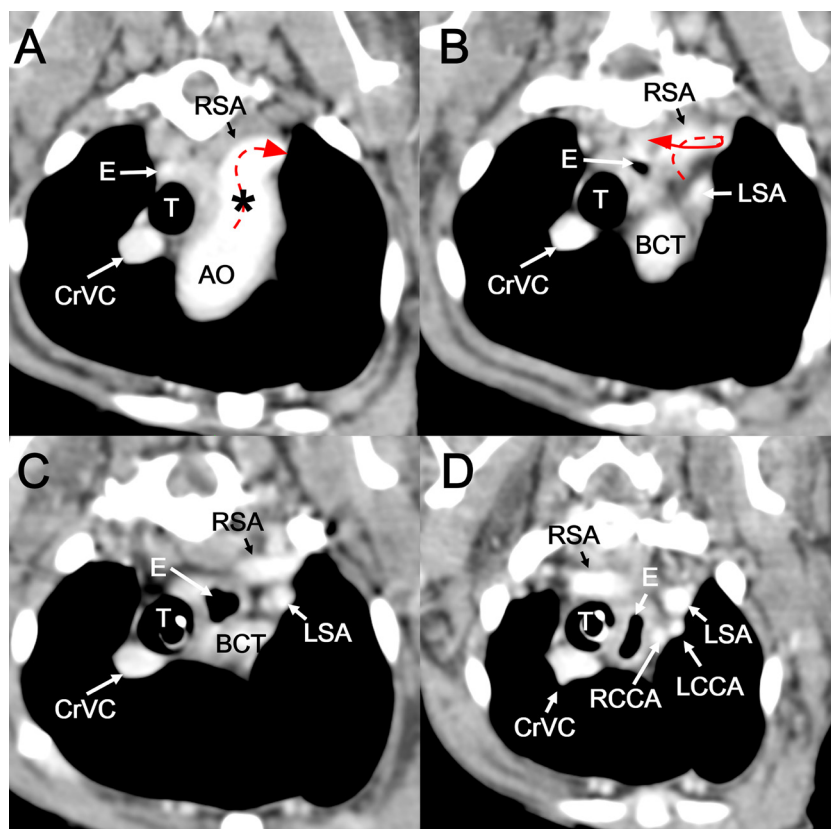


Fig. 2. Two-dimensional transverse computed tomography images representing the course of an aberrant right subclavian artery (1.25-mm thickness). (A) At the caudal level of the second thoracic vertebra (T2), the aberrant artery courses in a dorsal direction, curving toward the left side. At the level between the first (C) and second (B) thoracic vertebrae (T1-2), the aberrant artery suddenly turns toward the right and travels further. (D) At the level of the first thoracic vertebra (T1), the aberrant artery courses toward the right forelimb, passing over the dorsal surface the esophagus and trachea. The atypical course of the aberrant artery makes an incomplete vascular ring that does not completely wrap the esophagus. An asterisk indicates an aneurysmal dilation of the aberrant artery.

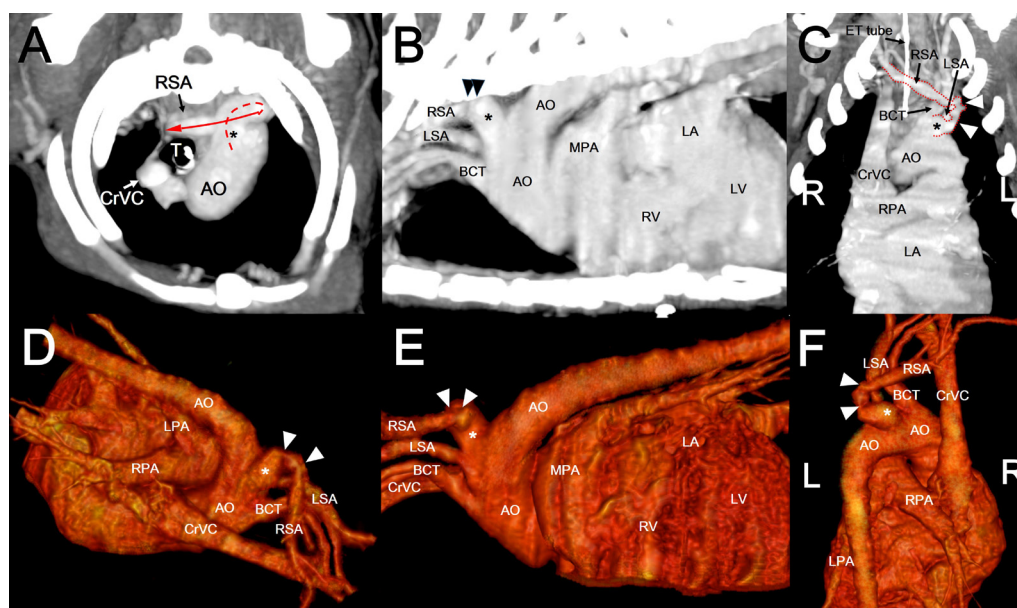


Fig. 3. Maximal intensity projection (40-mm thickness) and three-dimensional volume rendered images of the aberrant right subclavian artery. Transverse (A), sagittal (B), and dorsal (C) views of maximal intensity projection images that present the atypical course of the aberrant right subclavian artery (red dot and full line). Three-dimensional volume rendered images showing dorsal-cranial-right to ventral-caudal-left (D), left to right (E), and dorsoventral projection views (F). White and black arrow heads indicate bending and stenotic regions of the aberrant artery. White and black asterisks indicate an aneurysmal dilation.

aneurysmal site rupture was not identified, aneurysmal dilation could cause arterial rupture and thrombus formation [6, 10]. The cause of the aortic arch dilation is also unclear, but human studies suggest aortic dissection due to the aberrant subclavian artery [7], aortic arteritis, atherosclerosis, and trauma as the causes [4].

Thrombi, which can cause decreased blood pressure, were not identified in the aberrant artery. Moreover, no collateral arteries to compensate for the reduced blood circulation were detected. The reason for this might be that the partial stenotic region and the position of the forelimb near the heart affected the minimal circulation, to prevent the complete ischemia. However, the continued bending force has the potential to cause ischemic injury due to more severe stenotic deformation.

This case did not present a regurgitation unlike previous aberrant right subclavian artery cases with late-onset regurgitation [8, 14]. The previous cases showed the typical vascular rings consisting of an aberrant right subclavian artery and the trachea compressing the esophagus from every direction [8, 14]. However, the present case showed that the aberrant artery did not wrap the esophagus immediately after leaving the origin. In contrast, the aberrant artery roamed toward the left lateral and dorsal side, passing over the esophagus at the more cranial region. As a result, the incomplete vascular ring that did not completely wrap the esophagus did not cause clinically significant regurgitation. Nevertheless, the aneurysmal dilation of the root of the aberrant artery with the bending point could still pose a risk of progressive esophageal compression and late-onset regurgitation, as mentioned in a previous study [7, 9, 14].

Hypotension of the right forelimb due to subclavian artery stenosis can cause a misreading of systemic blood pressure [12]. This misreading can lead to the inappropriate treatment of heart and renal emergencies and conditions of shock, and thus poses a great risk. Consequently, routine blood pressure evaluation of the four extremities should be performed [12]. In the present study, blood pressure was estimated using non-invasive Doppler ultrasonography. Although direct blood pressure estimation within an artery is more accurate than a non-invasive method, the non-invasive method will be more helpful in frequent follow-ups.

A differential diagnosis of an aberrant right subclavian artery was made for a round soft tissue opacity just below the second thoracic vertebra and near the aortic arch. Although esophagography was not performed in this study, a CT angiography was able to clearly diagnose the aberrant right subclavian artery. However, accurate representations of the bending and stenotic regions of the aberrant artery were difficult to identify using only 2D transverse CT images. However, maximal intensity projection and 3D volume rendered images could clearly describe the complicated course and bending and stenotic regions of the aberrant artery.

In conclusion, this case is the first report of clinically significant stenosis and aneurysmal dilation of an aberrant right subclavian artery that caused a misreading of systemic blood pressure in a senior Pekinese dog. In addition, the structural features causing a misreading were described in detail using CT angiography, maximal intensity projection, and 3D volume rendered images. Stenosis and aneurysmal dilation of aberrant subclavian arteries should be included as differential diagnoses in dogs with a round soft tissue opacity near the aortic arch and below the thoracic vertebrae on a lateral thoracic radiograph. In addition, systemic blood pressure should be routinely evaluated for the four extremities and a differential diagnosis of a vascular ring anomaly should be included in dogs with a different blood pressure between the cranial extremities.

REFERENCES

- Bezuidenhout, A. J. 1989. Anomalous origins of the right subclavian and common carotid arteries in the dog. *J. S. Afr. Vet. Assoc.* **60**: 215–218. [Medline]
- DeKleer, V. S. 1971. An anomalous origin of the right subclavian artery in the dog. *Br. Vet. J.* **127**: 76–82. [Medline]
- Griffiths, D. 1989. Three cases of aberrant right subclavian artery in the dog. *Acta Vet. Scand.* **30**: 355–357. [Medline]
- Isselbacher, E. M. 2005. Thoracic and abdominal aortic aneurysms. *Circulation* **111**: 816–828. [Medline] [CrossRef]
- Jung, J., Cho, Y., Jung, Y., Jeong, J. and Lee, K. 2014. Diagnosis and treatment of an aberrant right subclavian artery with persistent right ligamentum in a kitten. *Pak. Vet. J.* **35**: 119–122.
- Juvela, S., Porras, M. and Poussa, K. 2000. Natural history of unruptured intracranial aneurysms: probability of and risk factors for aneurysm rupture. *J. Neurosurg.* **93**: 379–387. [Medline] [CrossRef]
- Kieffer, E., Bahnini, A. and Koskas, F. 1994. Aberrant subclavian artery: surgical treatment in thirty-three adult patients. *J. Vasc. Surg.* **19**: 100–109, discussion 110–111. [Medline] [CrossRef]
- Miller, R., Wilson, C., Wray, J., Jakovljevic, S. and Tappin, S. 2016. Adult-onset regurgitation in a dog with an aberrant right subclavian artery: a CT angiographic study. *Vet. Rec. Case Reports* **3**: e000138 [CrossRef].
- Polgaj, M., Chrzanowski, L., Kasprzak, J. D., Stefańczyk, L., Topol, M. and Majos, A. 2014. The aberrant right subclavian artery (arteria lusoria): The morphological and clinical aspects of one of the most important variations – A systematic study of 141 reports. *Sci. World J.* article ID 292734,6, <http://dx.doi.org/10.1155/2014/292734>.
- Stenbaek, J., Kalin, B. and Swedenborg, J. 2000. Growth of thrombus may be a better predictor of rupture than diameter in patients with abdominal aortic aneurysms. *Eur. J. Vasc. Endovasc. Surg.* **20**: 466–469. [Medline] [CrossRef]
- Tsukise, A., Sugawa, Y. and Okano, M. 1972. Two anomalous cases of the right subclavian artery arising directly from the aortic arch in dogs. *Nippon Juigaku Zasshi* **34**: 11–15. [Medline] [CrossRef]
- Wood, R. J. and Walmsley, A. J. 2006. Subclavian artery stenosis and blood pressure control. *Anaesthesia* **61**: 409–410. [Medline] [CrossRef]
- Yoon, H. Y. and Jeong, S. W. 2011. Surgical correction of an aberrant right subclavian artery in a dog. *Can. Vet. J.* **52**: 1115–1118. [Medline]
- Yoon, H., Kim, J., Kwon, G. B., Lim, J. H. and Eom, K. 2017. Computed tomography angiography characteristics of multiple vascular anomalies in a senior dog with late-onset regurgitation. *Vet. Radiol. Ultrasound* [CrossRef].