

Angiography procedure and endovascular treatment Retrospective analysis in Neurosurgery Department of “Prof. Dr. N. Oblu” Clinic Emergency Hospital Iasi

Georgiana Ion¹, A. Chiriac, N. Dobrin¹, I. Poeată

“Grigore T. Popa” University of Medicine and Pharmacy, Iasi

¹“Prof. Dr. N. Oblu” Clinic Emergency Hospital, Iasi

Abstract: A retrospective analysis of the cases admitted, investigated and treated in “Prof. Dr. N. Oblu” Clinic Emergency Hospital from the beginning of activity in the angiography laboratory from 2008 to June 2017.

Key words: angiography, aneurysm, fistula, tumor, procedure, treatment

Introduction

Cerebral and spinal angiography is a procedure of diagnosis for patients with a neurologic disease that can be completed by a treatment maneuver.

Pathology that can be explored and treated through neuroangiography is extensive: spinal AVM or fistula, extracranial carotid or vertebral stenosis or dissection, cerebral tumors, cerebral AVM or fistula, aneurysms, SAH, nontraumatic parenchymal cerebral hemorrhage, carotid-cavernous fistula, cerebral spasm, stroke, cerebral vasculitis, cerebral venous thrombosis, etc. Regarding the treatment procedure, in this department the situation is at the level of international specialized centers.

In neurosurgery department of “Prof. Dr. Nicolae Oblu” Emergency Hospital the angiography procedure through Seldinger

catheterization it started in 2007, when it was a learning period for the neurosurgeons dedicated for this pathology (dr. Faiyad Ziyad, dr. Chiriac Alexandru, dr. Dobrin Nicolae with the support of Prof. Dr. Poeata Ion). After the introduction of angiography in the neuroradiological diagnosis, soon after it was used also in Neurosurgery Hospital from Iasi by senior neurosurgeons.

Direct puncture of the carotid artery or vertebral artery with a trocar and direct injection of contrast substance has been heavily used with the purpose of diagnostic for tumors, intracerebral haemorrhage or vascular abnormalities, when the computer tomography or MRI were not available.

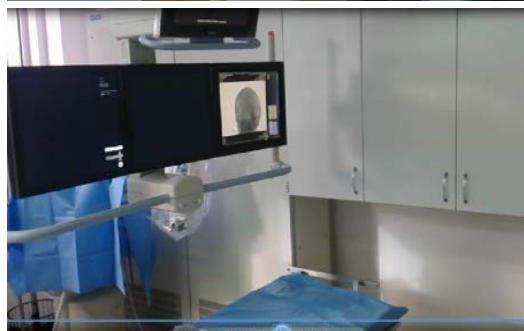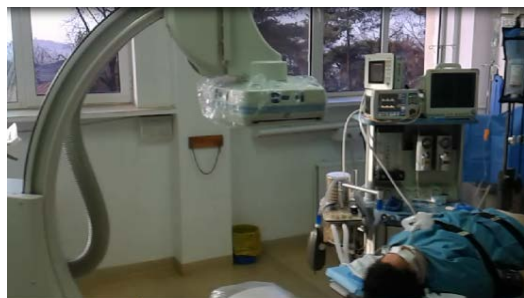Materials and Methods

Starting the year 2008 the main procedures which were conducted in the laboratory of

angiography were: diagnostic angiography, endovascular treatment of aneurysms, AV fistula, AVMs, percutaneous angioplasty with stent or balloon and more recently, intraarterial injection of nimotop or thrombolysis and tumor embolization. It must be noted that carotid-cavernous fistulas were included in the category of AVM/AVF.

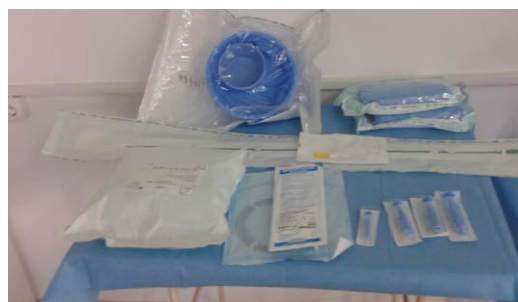In the lower table are represented the main procedures conducted from January 2008 to June 2017.

Total	2041	259	146	118	17
DSA	Aneurysm	AVM/DAVF	stentation	tumor embolization	
2008	30	9	2	0	0
2009	152	10	4	0	0
2010	109	9	2	1	0
2011	166	13	5	9	0
2012	256	20	15	26	1
2013	282	40	22	26	3
2014	274	27	37	23	2
2015	252	44	18	4	2
2016	294	45	20	14	4
2017	226	42	21	15	5



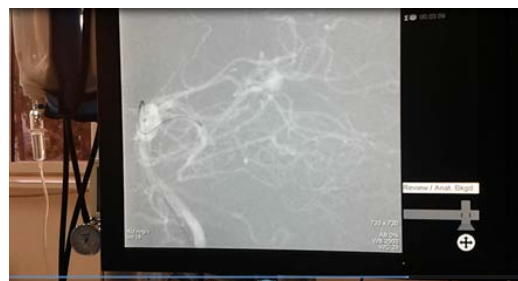Procedure

First of all, a patient's preparation must be carried out with some blood tests (urea, creatinine, blood cell count, coagulation) an electrocardiogram, a neurologic examination and a review of available imaging. If the patient is following treatment with antiplatelet or anticoagulants, medication in continue on the day of the procedure. Regarding the patient preparation, this should not eat or drink for 12 hours before the procedure, the inghinal region should be sterilely prepared and at least one peripheral access catheter. The family and the patient are advised about the stages and also the risks and benefits of the procedure and they must sign the consent.



The patient is brought in the angiography room in an disposable costume with a saline solution 0,90% NaCl perfusion and is positioned on the angiography table in supine.

The inguinal region is discovered and sterilized with betadine. Monitoring of the patient during the procedure is made through heart rate, blood pressure and electrocardiographic. Sedation and general anesthesia are used for the cases when treatment is required or in patients who are unable to cooperate. Otherwise, they are advised of the possible heat sensation that may occur when injecting the contrast substance and the need not to move during the procedure. After the positioning, the patient is covered with sterile disposable fields over which the necessary tools are placed (disposable). Local anesthesia with lidocaine 1% is performed at the puncture site and a standard 18 G needle is used for the access for a 5F sheath (in case of diagnostic angiography), a 6F or an 8F sheath (in case of treatment). All the instruments are washed with heparinized saline solution before use. In general, the right common femoral artery is the main access path. The catheterization is made with a catheter of varying sizes and shapes, depending of aortic arch anatomy and the tortuosity of the vessels, the most common being an 5F angled catheter of 90-cm length. During the advancement, a guidewire (hydrophilic 0.035-inch wire) is advanced into the catheter under fluoroscopic monitoring. The catheter should be handled with care, especially in the case of very tortuous vessels, when sufficient forward guidewire can straighten them. A stopcock is used for contrast injection or for continuous saline flush. Contrast injection into the selective internal carotid artery, external carotid artery or vertebral artery highlights the cerebral vascular tree.



In cases when is needed the catheterization of the smaller vessels (from Vertebral artery, distal ECA) or supratentorial segment of the internal carotid artery, a microcatheter and microwire are used under the protection of a continuous heparinized saline infusion. The basic positions purchased are lateral, anteroposterior and oblique (45 degree) or three-dimensional rotation and 3D reconstruction of the vascular tree. After the procedure patients rest in dorsal decubitus for at least 8 hours under careful supervision in neurosurgery department or in neurointensive care units.

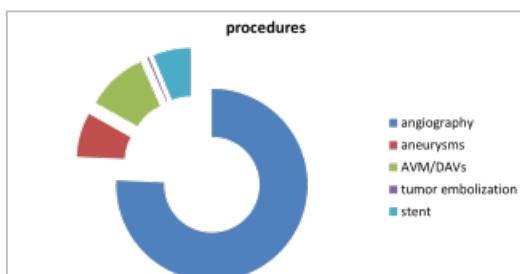
Among contraindications of this procedure are counting coagulopathy, iodine contrast allergy or renal insufficiency, all of which being relative contraindications. Among the complications of the vascular catheterization are to be retained the dissection, spasm of the artery or embolus with distal occlusion.

Results

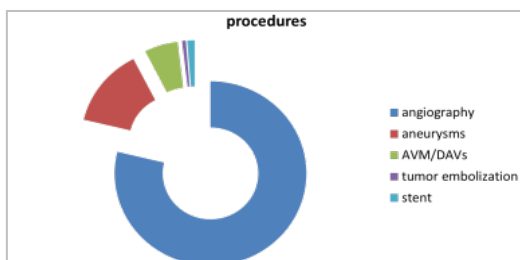
Starting in 2008 endovascular procedures were more limited to diagnostic procedure, 2 cerebral AVMs treated and 9 ruptured aneurysms embolization. In the next year were made 152 angiographies, 4 AVMs treated and

10 aneurysms. In 2010 the number of diagnostic procedure decreased to 109, with 9 aneurysms treated, 2 AVMs and 1 percutaneous angioplasty with stent. Regarding the year 2011, the activity was more intense, with 166 diagnosis, 13 aneurysms treated, 5 AVMs and 9 carotid artery stenosis treated. In the following year it was the first tumor embolization (pedicle from ECA with glue and coils), 256 diagnostic procedures, 20 aneurysms treated, 15 AVMs and 26 stent procedure. Regarding the year 2013, the procedures were similar (282 diagnosis angiography, 40 aneurysms treated, 22 AVMs, 3 tumors and 26 stent procedures).

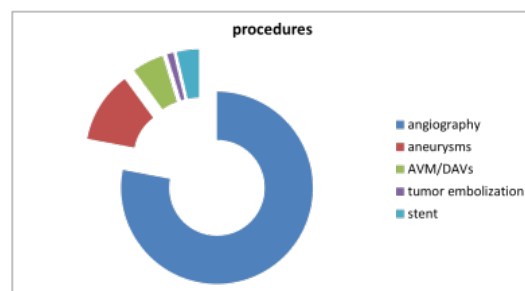
In 2014, the main procedures are represented in the chart below (274 diagnosis, 23 stent, 27 aneurysms, 37 AVMs and 2 tumor embolization).



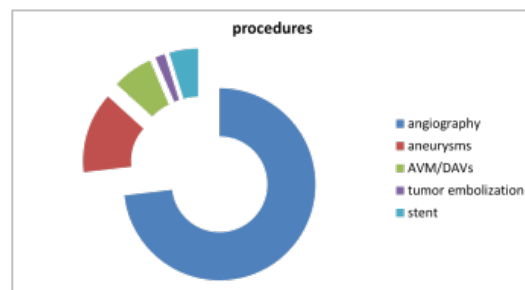
A similar trend is observed in 2015, with 252 diagnostic angiography, 44 aneurysms treated endovascular, 18 AVMs, 2 tumors and 4 percutaneous angioplasty with stent.



Regarding 2016, the number of percutaneous endovascular explorations were 294, 14 stent procedures, 45 aneurysms treated, 20 AVMs and 4 tumor pedicle closure.



From January 2017 to June 2017 were made 226 procedures of diagnostic, 42 aneurysms, 15 stent application (of which 4 percutaneous angioplasty with balloon), 21 AVMs and 5 tumor embolization.



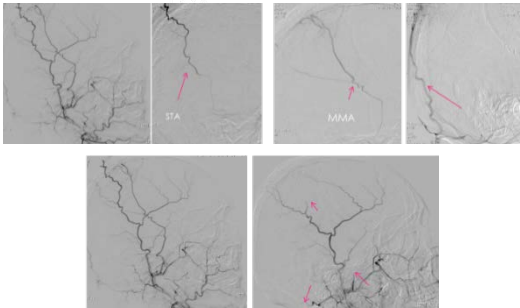
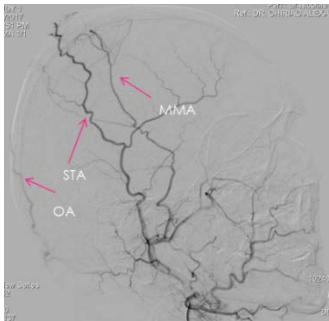
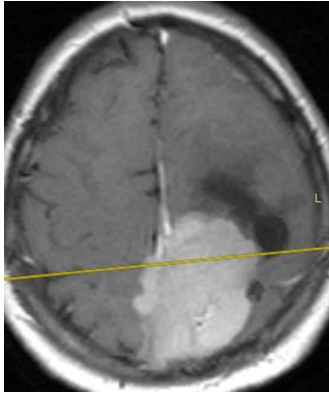
It must be noted that the mean age of patients investigated and treated endovascular was 56 years old (varies between 12 and 83 years), with a slight predominance of the male gender.

Representative cases

Endovascular embolization of tumors

Case1

M. 57Y epicranian formation vertex and right hemiparesis (crural predominant).



Pre/post STA, MMA, OA closure with glue

Case 2: F, 12Y, 1 year progressive visual field disorder; bilateral papillary edema.

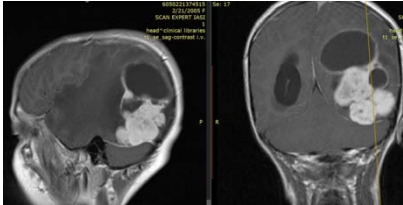
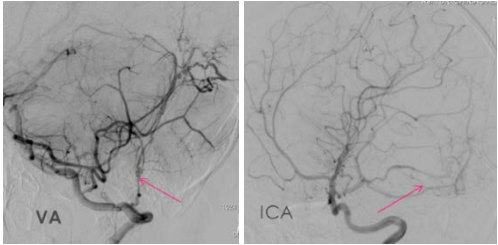


Figure 2.1. Cerebral MRI with contrast



Figures 2.2. & 2.3. A. of Tentorium Cerebelli

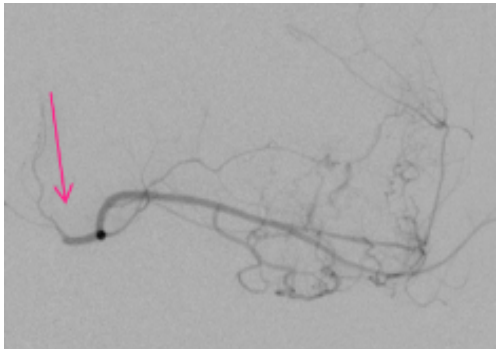
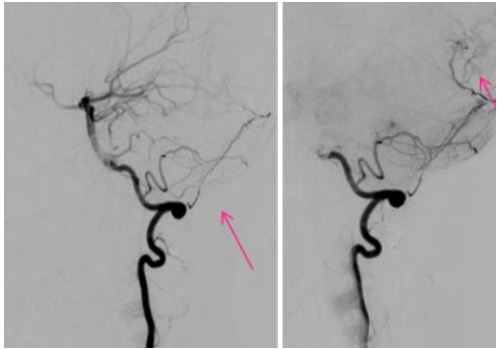
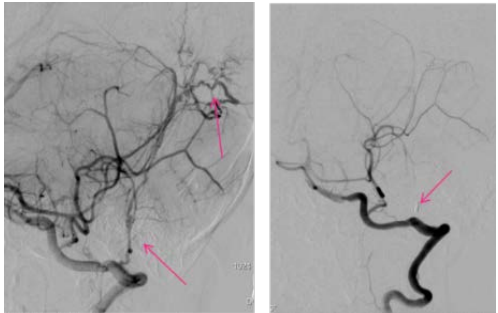


Figure 2.4. Pedicular injection of PComA and PCA



Precocious and tardive contrast injection



Pre/post coils closure of the tentorial branch of vertebral

Case 3

F, 16Y. Right cervicobrahialgia followed by progressive tetraparesis (4/5).

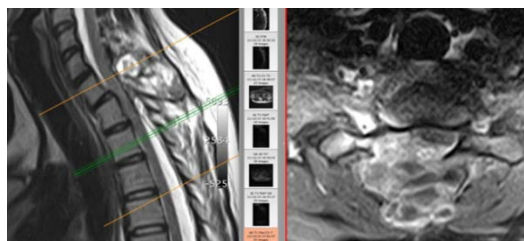
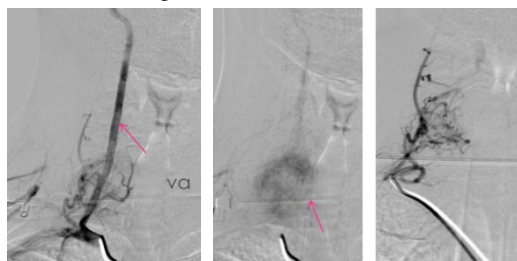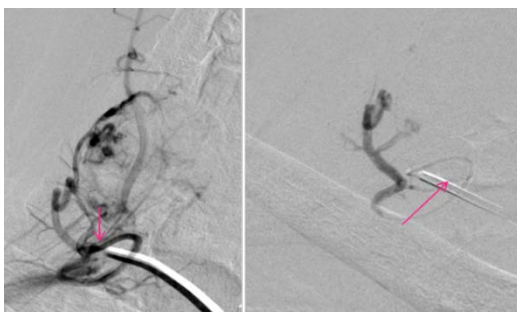


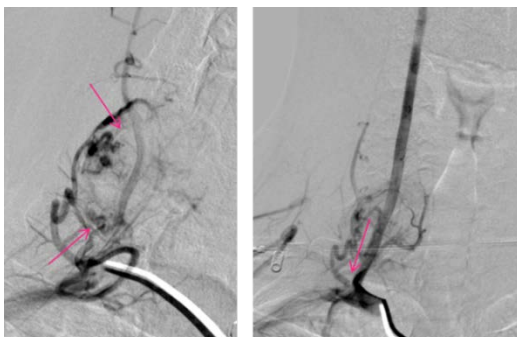
Figure 3.1. Cervical MRI



Figures 3.2., 3.3. & 3.4. Tumoral blush injected from thyrocervical trunk



Figures 3.5 & 3.6. Thyrocervical trunk closure with glue



Figures 3.7. & 3.8. Pre-post glue injection

Aneurysms

Case 4: F, 54Y, SAH, H&H=3, day 1, ruptured PComA and AChoA aneurysms.

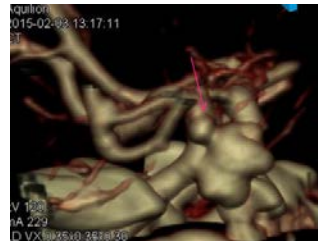

Figure 4.1. Angio-CT 3D reconstruction

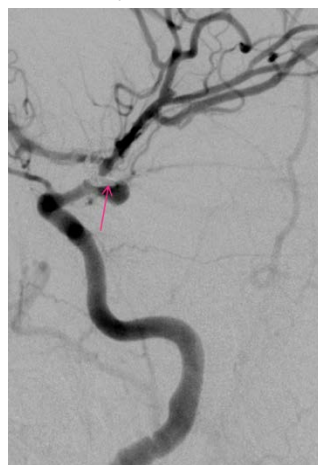

Figure 4.2. DSA after clipping the 2nd rupture

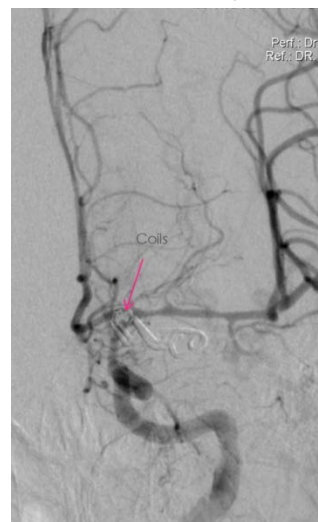
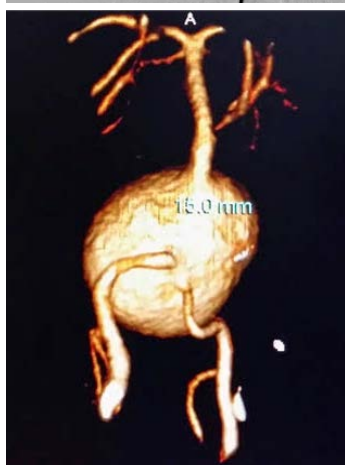
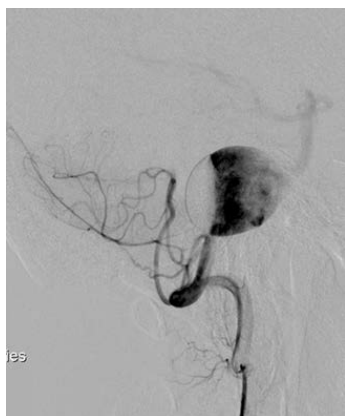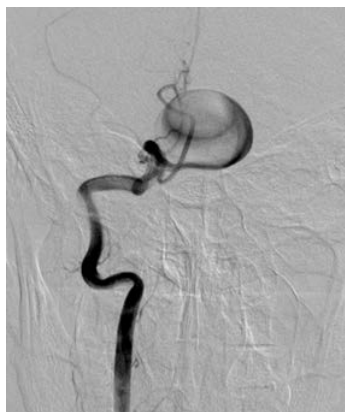Figure 4.3. Coils partial occlusion

Case 5

M, 34Y, right hemiparesis, dysphagia for 3 months.



Figures 5.1., 5.2. & 5.3. Basilar trunk aneurysm

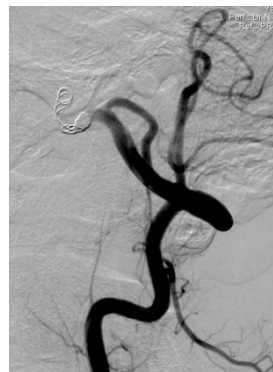


Figure 5.4. Left vertebral artery closure with coils

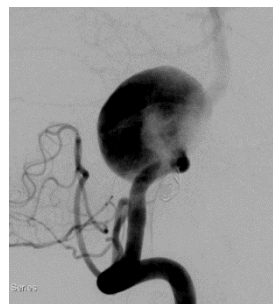

Figure 5.5. Right VA

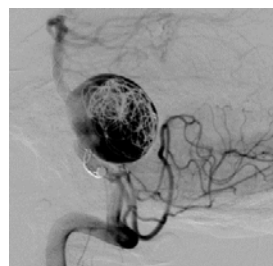


Figure 5.6. Stent assisted coiling

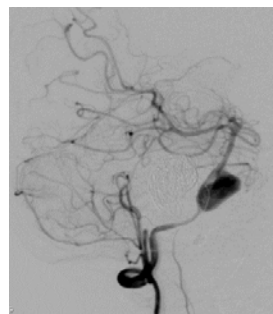
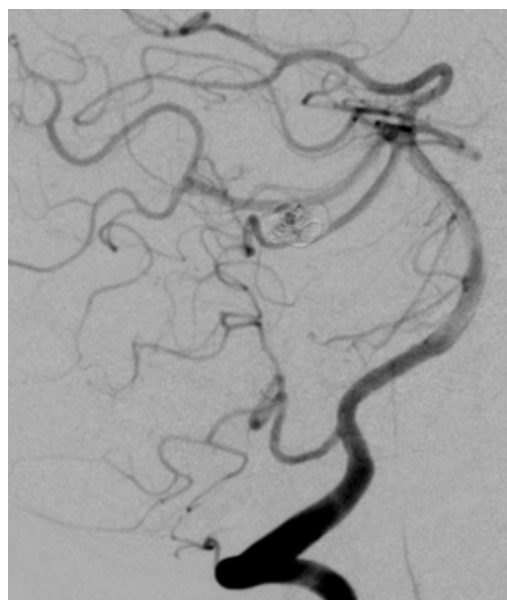
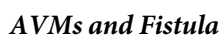

Figure 5.7. DSA after 3 months

F, 34Y, SAH, H&H=3



Figures 6.1. & 6.2. Diagnosis angio CT

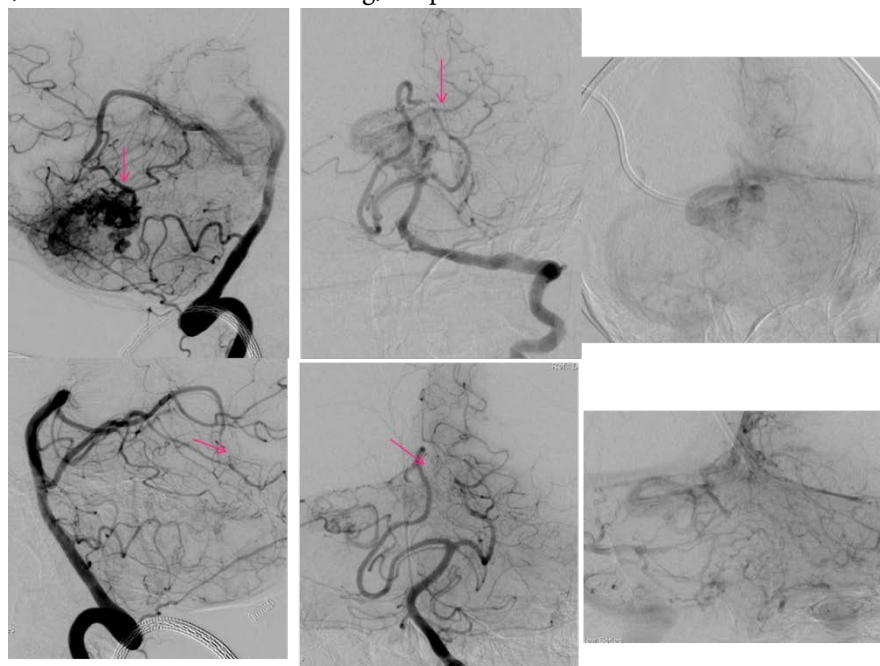


Case 7

Onyx closure 2 pedicle left ACA

Case 8

F, 53Y, sudden headache and vomiting, sleepiness.



Pre/post closure one pedicle –distal right PCA with glue

Case 9

F, 40Y, chemosis, right exophthalmia, severe cranial trauma 5 months ago

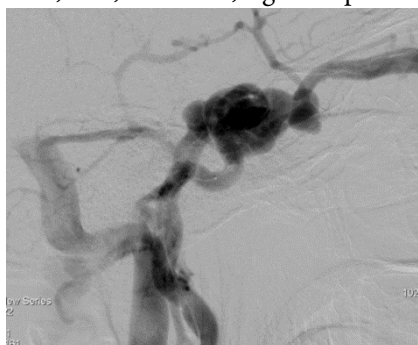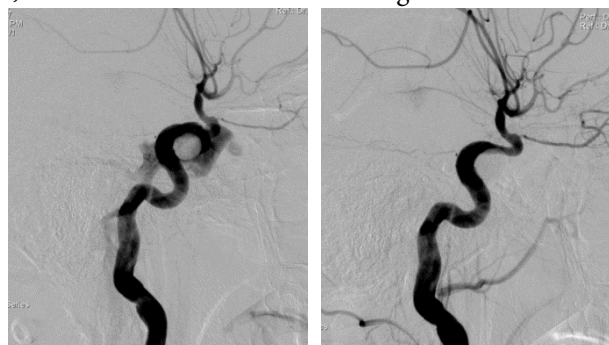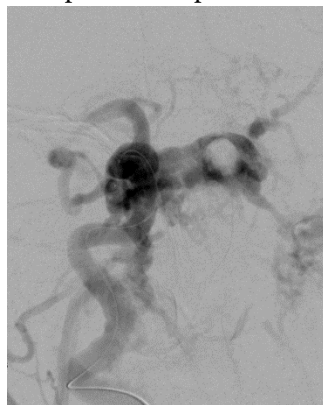
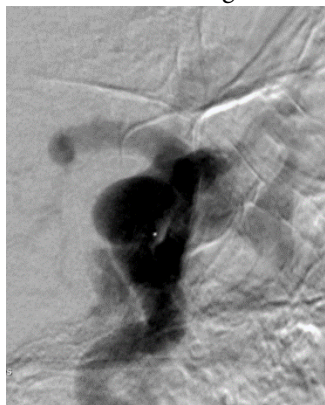


Figure 9.1. Right carotid-cavernous fistula



Figures 9.2. & 9.3. Pre/post balloon inflation

Case 10 - F, 85Y, right third nerve paresis, exophthalmia



Figures 10.1. & 10.2. Right ICA catheterization

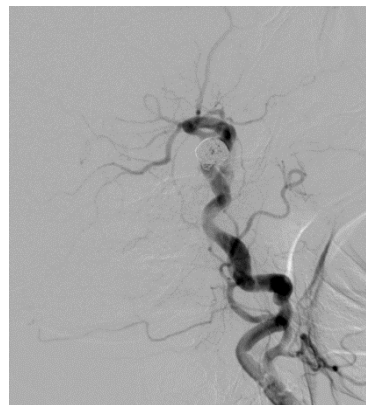

Figure 10.3. GDC closure of the CC fistula

Case 11 - M.13, GTC seizures

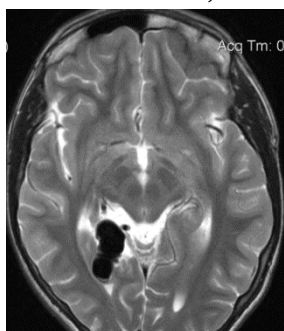


Figure 11.1.
MRI venous ectasia

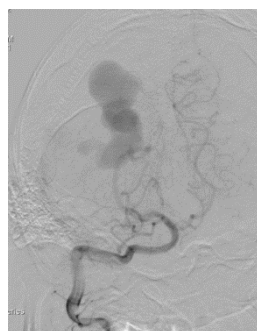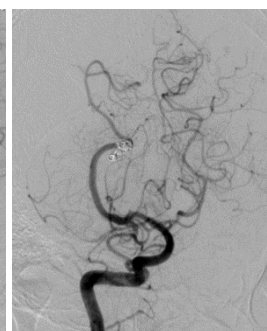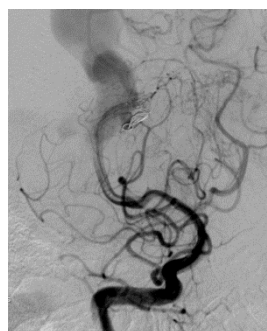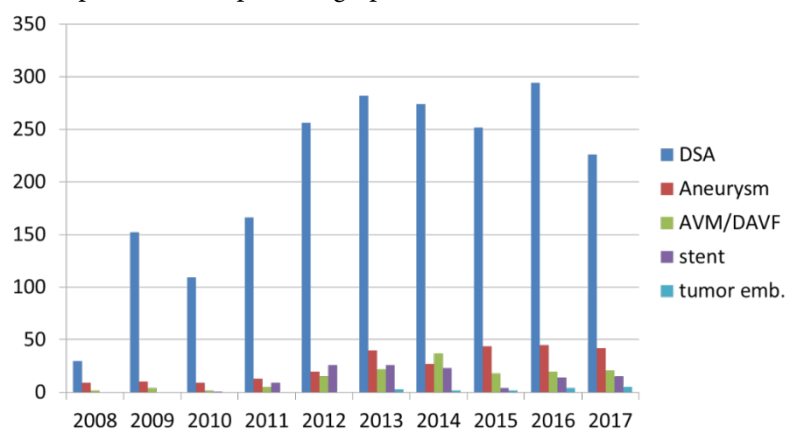


Figure 11.2.
Right VA



Figures 11.3. & 11.4
Closure of the fistula with coils

A complete and comparative graph is shown below, from 2008 to 2017.



Discussion

AngioCT scan and AngioIRM are useful tools in the diagnosis of neurological and neurosurgical pathology, but with a lower sensitivity and specificity than angiography.

Is observed that, after less than 3 years of practice, the number of proceedings made in Iasi angiography laboratory has increased significantly. After the year 2012 the diagnostic angiographies made remain relatively constant, but the number of aneurysms treated endovascular (coiling, stent assisted coiling or flow diverter) has increased, as well as the number of tumors combined treated (presurgical closure of pedicles from ECA, ICA or vertebral artery with glue or coils). The number of stent or balloon angioplasties is relative constant during the almost 10 years of activity.

In the last year protocols for stroke and endovascular treatment have been established, and the first trombaspersion was experienced in a case of carotid dissection.

In case when vascular spasm is present during or after the embolization, nimodipine injection (5ml dissolved in 15 ml of saline solution) is often effective, even in segmental vasospasm. It was observed that, patients who benefit from intraarterial injection of Nimotop have a better evolution during the first 21 days.

Conclusions

Diagnosis and endovascular treatment is indispensable to any neurosurgical center,

because the pathology involved is more and more diverse and numerous. Every few year's new devices and substances are being developed that increase the efficiency of this procedure.

During this years an increasing efficiency was observed both as procedure, duration, results and impact on the patient.

But, the most important, is that this team is complete (regarding the possibility of treating both surgically and endovascular) and is made up of neurosurgeons with a vast experience of over 10 years.

References

1. Sun Ho Ahn, MD; Ethan A. Prince, MD; Gregory J. Dubel, MD; Basic Neuroangiography: Review of Technique and Perioperative Patient Care; *Semin Intervent Radiol* 2013;30:225-233
2. *Tratat de chirurgie vol. VI - Neurochirurgie*, Ioan St. Florian, Ion Poeata, Academiei Romane 2015
3. <http://neuroangio.org/neuroangio-topics/introductory-brain-angiography/>
4. Masaaki Shojima, MD; Marie Oshima, PhD; Kiyoshi Takagi, MD, PhD; Ryo Torii, PhD; Motoharu Hayakawa, MD, PhD; Kazuhiro Katada, MD, PhD; Akio Morita, MD, PhD; Takaaki Kirino, MD, PhD; Magnitude and Role of Wall Shear Stress on Cerebral Aneurysm Computational Fluid Dynamic Study of 20 Middle Cerebral Artery Aneurysms; *Stroke*. 2004;35:2500-2505
5. Timothy J. Kaufmann, MD, John Huston, III, MD, Jay N. Mandrekar, PhD, Cathy D. Schleck, BS, Kent R. Thielen, MD, and David F. Kallmes, MD; Complications of Diagnostic Cerebral Angiography: Evaluation of 19 826 Consecutive Patients; *Radiology*; June 2007, Volume 243, Issue 3
6. Richard E. Latchaw; Guidelines for Diagnostic Neuroangiography: A Model to Emulate from Neuroradiologist's Perspective; *American Journal of Neuroradiology* January 2000, 21 (1) 44-45.
7. Neil M. Borden, MD, 3d angiographic atlas of neurovascular anatomy and pathology, Cambridge University Press, 2006