

## Odontoid process fracture in 2 year old child: a rare case report

**Prajapati Hanuman Prasad, Singh Deepak Kumar, Singh Rakesh Kumar, Yadav Kuldeep**

Department of Neurosurgery, Dr RML IMS Lucknow Uttar Pradesh, INDIA

**Abstract:** In small childrens spine injuries are rare. In this age group upper cervical spine is commonly affected. Odontoid process fracture involve only a subset of cervical spine fractures. In small childrens, this fracture typically involves the cartilaginousplate that separates the odontoid process from the body of the axis. Odontoid processfracture is rare in children less than 7 years of age.

**Key words:** odontoid process, fracture, 2 years of age, management

### Introduction

Cervical spine injuries in small children are rare with a reported incidence of 0.2 to 0.5% of all fractures or dislocations and 1.5 to 3% of all lesions in the spine [1]. In younger children upper cervical spine is commonly affected, with over 50% of spinal injuries in small children affecting this region. This relates to the child's greater head-to body ratio, and horizontal orientation of the facet joints where more forces are centered around the junction between the large head and the smaller body[2]. In small children, dens fracture typically involves the cartilaginous plate that separates the odontoid process from the body of the axis. The cartilaginous end plate between the dens and the body of C2 does not ossify until the child is 5 to 7 years old[3].

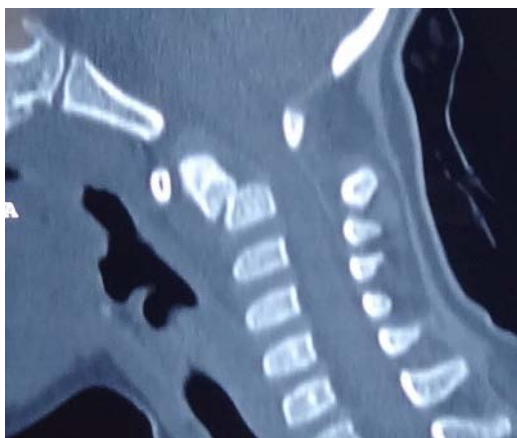
Therefore, odontoid synchondrosis fractures are common in young children less than 7 years of age [4,5]. Odontoid process fracture are rare in small children only few cases are reported in the literature.

The current literature reports that these fractures can be successfully treated with nonoperative management including cervical spine immobilization as well as operative interventions ranging from closed reduction and external fixation to posterior fixation or fusion of C1/C2 [6]. We present a case of odontoid process fracture in a 2-year-old patient managed by surgery.

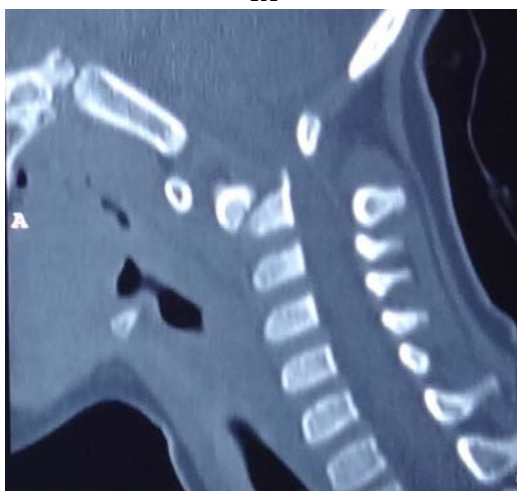### Case report

A 2 year-old female child was brought with history of road traffic accident followed by quadriplegia and inability to hold the neck.

Examination revealed a conscious child with a GCS score of 15/15. The tone was increased in all four extremities with child moving all 4 limbs but was not able to stand. Plain CT cervical spine (figure 1A and 1B) and Plain X-Ray cervical spine (figure 2B) revealed fracture of the odontoid process with anterior subluxation of C1 over C2. Patient was immobilized with a Philadelphia collar.



1A



1B

Figure 1A and 1B - Odontoid process fracture

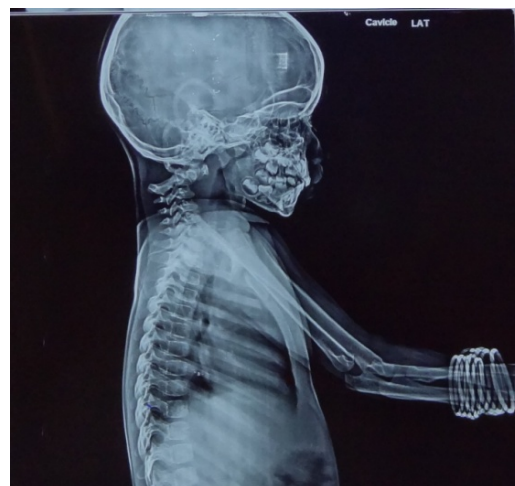


Figure 2A - Preoperative X-Ray shows anterior subluxation of C1 over C2

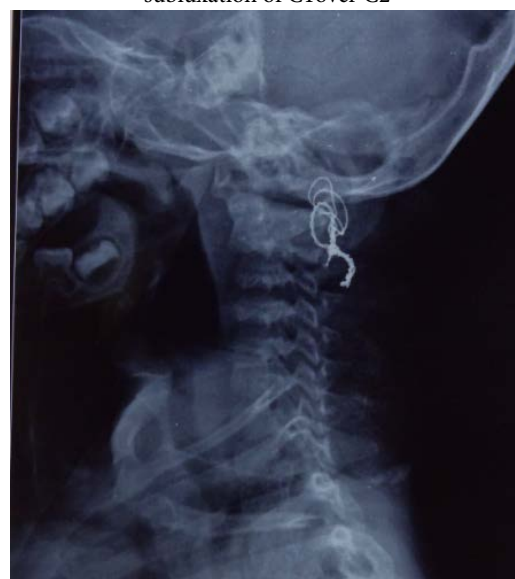

Figure 2B - Postoperative X-Ray

In view of the presence of significant neurological deficits and the posterior displacement of the fractured odontoid fragment, it was felt that conservative treatment with external immobilization might not be helpful. Hence, C1, C2 posterior

fixation (Sontag method) done. After posterior wire fixation good reduction achieved (Figure 2B). In postoperative period patient was kept on Philadelphia collar. Postoperative period was uneventful. Three months after surgery, patient was able to walk and hold the neck.

## Discussion

In small children, c2 vertebral body is divided by the paired neurocentral synchondrosis between the neural arches and the body of axis and the subdental synchondrosis between the dens and the body of axis [7]. Fusion of this synchondrosis usually takes place by 7 years of age. Most cases of odontoid fractures in children less than 7 years of age are odontoid synchondrosis fracture. Odontoid process fracture in children below 7 years of age are rare, only few cases are reported in literature.

Management of such fractures in the pediatric population remains unclear. After reviewing the literature, we found only one other case report describing the management of a displaced type 2 odontoid process fracture in a small children. In this publication, Bhagat and coauthors described operative intervention of a displaced type 2 odontoid process fracture in a 2-year-old girl [8]. Although they did not describe when union occurred, they noted marked remodeling of the fracture over a 30-month period. With such paucity of literature on this topic, it is unknown whether operative intervention aids fracture union and functional outcome in the small children.

There are various options available for management of odontoid process fracture.(1)

External immobilisation (2) Posterior c1-c2 sublamina wiring(3)c1-c2 transarticular screw(4) Odontoid screw fixation.Odontoid screw fixation is controversial in small children. In small children most odontoid synchondrosis fractures are often treated by external immobilization. Approximately 96% fusion rate is expected with external immobilization alone [9]. However, surgery does have a role in selected patients with odontoid fractures [10]. Generally, surgery is an option in patients who fail conservative treatment. Recent literature shows that certain characteristics of odontoid fractures are associated with high failure rate with external immobilization alone[10].Fulkerson et al.[10] reported that a significant displacement of the odontoid of 11% to 100%, angulation greater than 30 degrees, clinical evidence of upper cervical spinal cord injury were indications for surgical intervention.

In our patient, there was posterior displacement of the odontoid more than 11% with clinical as well as clinical evidence of upper cervical cord injury and hence our patient had the necessary indications for surgical fixation. The fact that our patient showed significant improvement with surgical treatment indicates that in selected patients with odontoid fractures surgical fixation is a viable option. In our patient, posterior wire fixation was chosen because the fracture fragments were displaced posteriorly and causing compression over cord. Post operatively patient was placed on Philadelphia collar and patient condition gradually improved.

Our case illustrates that certain Odontoid process fractures in small children can be successfully managed with C1-C2 posterior wire fixation and postoperatively Philadelphia collar.

## Conclusion

Most of the Odontoid fracture in small children is Odontoid synchondrotic fracture but odontoid process fracture is a rare event. Most patients with odontoid fracture can be treated by external immobilization alone. However, selected patients with this condition will benefit from surgical fixation as illustrated in this case report.

## Correspondence

*Dr. Hanuman Prasad Prajapati*

*Address: Department of Neurosurgery, Dr RML*

*IMS Lucknow Uttar Pradesh (India)*

*Mobile No.: 07727934104*

*Email: pushpa84.dhp@gmail.com*

## References

1. Patel J C, Tepas J J III, Mollitt D L, Pieper P. Pediatric cervical spine injuries: defining the disease. *J Pediatr Surg.* 2001;36(2):373–376. [PubMed]

2. Fesmire F M, Luten R C. The pediatric cervical spine: developmental anatomy and clinical aspects. *J Emerg Med.* 1989;7(2):133–142. [PubMed]

3. Sherk HH, Nicholson JT, Chung SM. Fractures of the odontoid process in young children. *J Bone Joint Surg Am.* 1978;60:921–924. [PubMed]

4. Blauth M, Schmidt U, Otte D, Krettek C. Fractures of the odontoid process in small children : biomechanical analysis and report of three cases. *Eur Spine J.* 1996;5:63–70. [PubMed]

5. Odent T, Langlais J, Glorion C, Kassis B, Bataille J, Poulouen JC. Fractures of the odontoid process : a report of 15 cases in children younger than 6 years. *J Pediatr Orthop.* 1999;19:51–54. [PubMed]

6. Mueller O M, Gasser T, Hellwig A, Dohna-Schwake C, Sure U. Instable cervical spine injury in a toddler: technical note. *Childs Nerv Syst.* 2010;26(11):1625–1631. [PubMed]

7. Garton HJ, Park P, Papadopoulos SM. Fracture dislocation of the neurocentralsynchondroses of the axis. Case illustration. *J Neurosurg.* 2002;96(3 Suppl):350. [PubMed]

8. Bhagat S, Brown J, Johnston R. Remodelling potential of paediatric cervical spine after type II odontoid peg fracture. *Br J Neurosurg.* 2006;20(6):426–428. [PubMed]

9. Fassett DR, McCall T, Brockmeyer DL. Odontoid synchondrosis fractures in children. *Neurosurg Focus.* 2006;20:E7. [PubMed]

10. Fulkerson DH, Hwang SW, Patel AJ, Jea A. Open reduction and internal fixation for angulated, unstable odontoid synchondrosis fractures in children : a safe alternative to halo fixation? *J NeurosurgPediatr.* 2012;9:35–41. [PubMed]