

## Large subgaleal hematoma producing turban head in 10 year boy with cerebral palsy: rare case report with review of literature

**Praveen Kumar Tripathi, Vardan Kulshreshtha, Gaurav Jaiswal, Tarun Kumar Gupta**

Departments of Neurosurgery, RNT Medical College, Udaipur, Rajasthan, INDIA

**Abstract:** Subgaleal hematomas (SGHs) are not uncommon. Because the subgaleal space has no anatomical boundaries, SGHs usually involve a large space and are typically limited to the parietal region. Cases of SGHs involving whole of head are relatively rare. In this study we report a rare case of massive enlargement of head after SGH causing severe pain and giving an appearance of turban. A 10 year old, male patient with cerebral palsy presented with progressive enlargement of head attaining a size of turban due to habitual head banging and self-punching overhead. SGH drainage and hematoma aspiration were performed and the patient's head size was restored.

**Key words:** Subgaleal hematoma (SGH), cerebral palsy (CP)

### Introduction

Subgaleal hematoma is a potentially life-threatening extracranial bleed that occurs most commonly in neonates after difficult instrumental deliveries (1). Its occurrence beyond the neonatal period is rare and is often associated with head trauma involving tangential or radial forces applied to the scalp causing emissary veins traversing the subgaleal space to be ruptured (2). Subgaleal hematoma (SGH) is a common clinical disease, largely because the subgaleal space is relatively loosely defined. The vast majority of SGHs are gradually absorbed. For cases exhibiting difficulties in absorption, puncture with

aspiration or incision followed by drainage can achieve satisfactory outcomes (3). Large subgaleal hematoma due to trivial head trauma in a cerebral palsy patient habitual of head banging and self-punching with no reported literature is interesting to describe.

### Case report

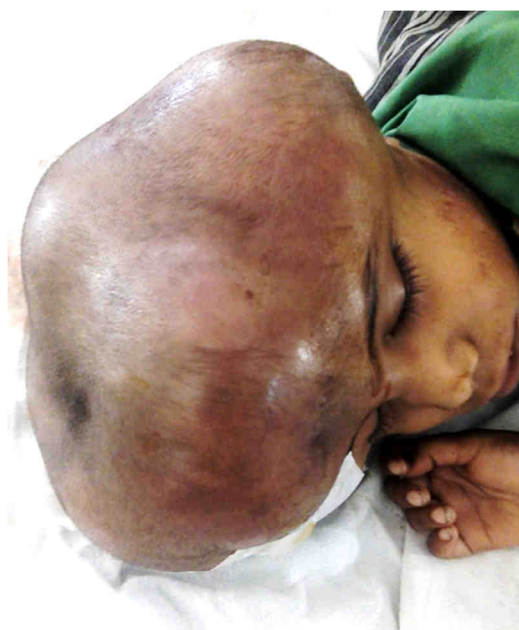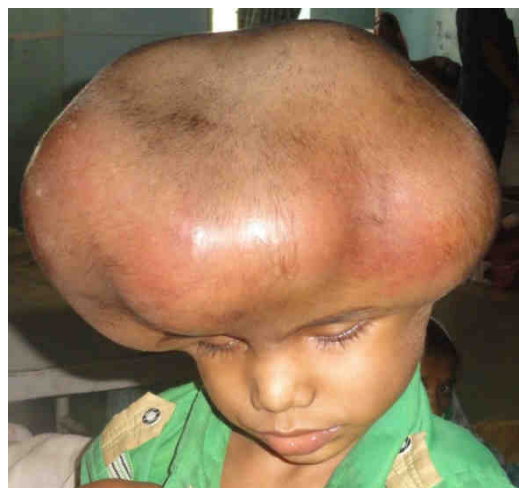
A 10 year old boy was admitted in our ward with chief complaint of progressive enlargement of head for 20 days. History was suggestive of initial swelling over frontal and parietal region which later involved whole of head. There was history of habitual head banging and self-punching overhead. Patient

was a diagnosed case of cerebral palsy with paraparesis. Perinatal history was suggestive of vaginal delivery with meconium aspiration syndrome. On examination patient was mentally retarded with spastic paraparesis with speech abnormality and inability to hold head. Head was enlarged with head circumference 134 cm with multiple soft, fluctuant, transilluminant, tender boggy swellings over frontal, bilateral parietal and occipital region of scalp. Pallor was present without lymph node enlargements or other manifestations of bleeding tendency such as purpura or ecchymosis.

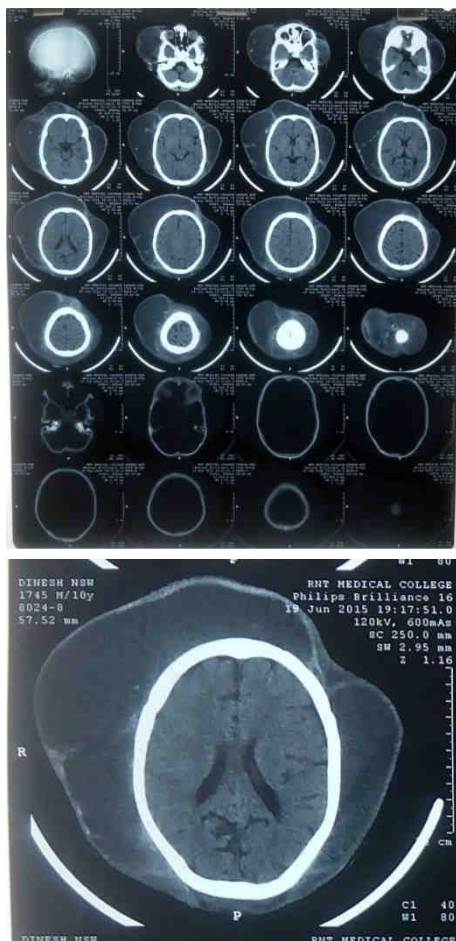
NCCT brain revealed multiple pockets of extracalvarial fluid collection with internal septations in subgaleal region of scalp suggestive of Subgaleal hematoma involving both sides without any intracranial hemorrhage, midline shift or skull fractures.

The screening coagulation tests revealed normal coagulation profile with decreased haemoglobin (7.0 gm/dl).

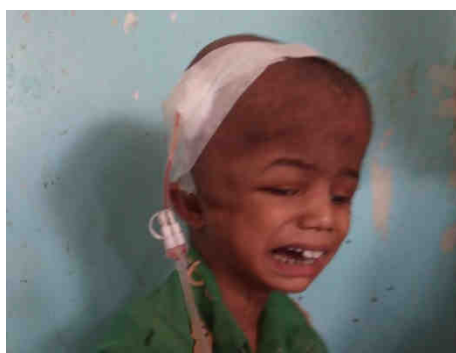
Since it was a huge collection with multiple septations, aspiration of SGH in multiple stages was done with application of pressure bandage. A closed suction drain kept in right parietal region which had largest pocket. A total of approximately 400 ml blood stained fluid drained. Paediatrician opinion sought and patient was discharged after 15 days after complete resolution of Subgaleal hematoma with advice to avoid head banging and head punching and to follow in pediatric and neurosurgery opd. Patient was followed after 1 & 3 months of discharge, no recurrence noted.



**Figure 1** - Massive subgaleal hematoma involving whole of scalp mimicking turban



**Figure 2** - NCCT brain of the patient at admission



**Figure 3** - Resolved subgaleal hematoma after aspiration and closed drain placement

## Discussion

The subgaleal space is located between the periosteum and the epicranial galea and comprises loose connective tissue; vessels connecting the scalp vein and skull diploe vein as well as the intracranial venous sinus are located within this space. External shear force during trauma may result in the rupture of the vessels, causing a large amount of blood to flow into the subgaleal space to form an SGH. The subgaleal space is not bounded by suture lines; therefore, an SGH can involve massive swelling of the entire scalp (4, 5). Non-traumatic SGH is very rare. The cause of non-traumatic SGH is sometimes associated with aneurysms of the STA, scalp AVF, and coagulation disorders (6, 7). Davis et al. reported on the diagnosis and management of neonatal subgaleal hemorrhage, and described it to be caused by a rupture of the emissary veins, which are connections between the dural sinuses and the scalp veins (8). Kashino et al. reported that an angiographic examination of three out of four cases of atraumatic SGH showed a well-developed STA on the surface of the SGH, and one case had shown similar findings from the early stage of the development of the hematoma (9). Raffini et al reported a von Willebrand disease case of SGH (10).

Cerebral palsy is commonly associated with a spectrum of developmental disabilities, including mental retardation, epilepsy, and visual, hearing, speech, cognitive, and behavioral abnormalities. Very impaired children with Cerebral palsy, especially those with Mental Retardation, can have self-abusive

behavior such as biting, head banging, or scratching. In the present patient, SGH developed due to self-abusive behavior of patient while the blood coagulation and platelet aggregation functions were normal.

No definitive therapeutic strategy has yet been established for SGH. Therefore, there are various opinions concerning the treatment of hematoma. Falvo et al. elected surgical evaluation and pressure dressings to shorten the period of blood resorption and decrease the risk of infection, calcification, and blood reaccumulation (11). Faber noted that aspiration may set the stage for infection or may be followed by recurrent bleeding and suggested that the extravasation itself may act as a tamponade to prevent further bleeding (12). Beauchamp et al. noted that hematoma aspiration was unnecessary unless severe pain, impending necrosis of the overlying scalp, or evidence of infection was present (13).

In present case there was a huge subgaleal hematoma with multiple septations causing severe pain and discomfort to the patient, aspirated and pressure bandage applied.

To the best of our knowledge, this is the first case to be reported with large subgaleal hematoma involving the entire scalp caused by self-abusive behavior of patient with cerebral palsy. An excellent response to treatment with surgical aspiration and compression bandage can be achieved followed by behavior therapy and rehabilitation.

## References

1. Benaron DA. Subgaleal hematoma causing hypovolumic shock during delivery after failed vacuum extraction: Case report. *J Perinatol.* 1993;13:228–31.
2. Vu TT, Guerrero MF, Hamburger EK, Klein BL. Subgaleal hematoma from hair braiding. Case report and literature review. *Pediatr Emerg Care.* 2004;20:821–3.
3. Strowitzki M, Eymann R, Schleifer J and Steudel WI. Vertex epidural hematoma with communicating bifrontal subgaleal hematomas treated by percutaneous needle aspiration. *Pediatr Neurosurg* 2001; 35: 1-4
4. Panigrahi S, Mishra SS, Das S and Patra SK. Large subgaleal hematoma as a presentation of parahemophilia. *J Neurosci Rural Pract* 2013; 4: 240-242.
5. Kichari JR and Gielkens H. Massive traumatic subgaleal haematoma. *Emerg Med J* 2013; 30: 344.
6. Rohyans JA, Miser AW, Miser JS. Subgaleal hemorrhage in infants with hemophilia: Report of two cases and review of the literature. *Pediatrics* 1982;70:306-7.
7. Maruki C, Nakajima M, Tsunoda A, Ebato M, Ikeya F. A case of giant expanding cephalhematoma: Does the administration of blood coagulation factor XIII reverse symptoms? *Surg Neurol* 2003;60:138-41.
8. Davis DJ. Neonatal subgaleal hemorrhage: diagnosis and management. *Can Med Assoc J.* 2001; 164 (10): 1452-1453.
9. Kashino S, Takuji T, Nagai H. A study on diffuse subgaleal hematoma in childhood. *Nerv Syst Child.* 1988; 13(14): 319-323.
10. Raffini L, Tsarouhas N: Subgaleal hematoma from hair braiding leads to the diagnosis of von Willebrand disease. *Pediatr Emerg Care.* 2004; 20(5): 316-318.
11. Falvo CE, San Filippo JA, Vartany A, et al. Subgaleal hematoma from hair combing. *Pediatrics.* 1981; 68: 583-584.
12. Faber M. Massive subgaleal hemorrhage: A hazard of playground swings. *Clin Pediatr.* 1976; 15: 384-385.
13. Beauchamp CJ, Metcalf MB. Subgaleal hemorrhage. *Pediatrics.* 1983; 72: 912-913.