



NOTE

Surgery

Humeral fracture in a Japanese Black calf repaired by closed approach and two methods of external skeletal fixation

Norio YAMAGISHI^{1,2)*}, Ayano KAJIWARA³⁾, Ken-ichi SHIBANO¹⁾,
Takahiro AOKI¹⁾, Megumi ITOH¹⁾, Kaoru HATATE^{1,2)} and Kimie IINO¹⁾

¹⁾Department of Veterinary Medicine, Obihiro University of Agriculture and Veterinary Medicine, Inada, Obihiro, Hokkaido 080-8555, Japan

²⁾United Graduate School of Veterinary Sciences, Gifu University, Gifu 501-1193, Japan

³⁾Ikeda Veterinary Clinical Center, Tokachi Agricultural and Mutual Aid Association (Tokachi-NOSAI), Ikeda-cho, Nakagawa-gun, Hokkaido 083-0021, Japan

J. Vet. Med. Sci.

79(6): 1056–1060, 2017

doi: 10.1292/jvms.17-0017

Received: 14 January 2017

Accepted: 17 April 2017

Published online in J-STAGE:
7 May 2017

ABSTRACT. A healthy 71-day-old female Japanese Black calf was evaluated for fracture of the left humerus. The left humeral fracture was treated by closed repair and unilateral external skeletal fixation (ESF) with an epoxy putty fixator. The calf was active, and eight days after surgery slipped and fell, resulting in breakage of the ESF. The calf underwent repair by transfixation pinning and casting (TPC), which is an alternative to the ESF method. The TPC was removed 37 days after the first surgery, and the calf could bear weight on the left forelimb while walking. This case suggests that recovery after closed repair with TPC for a humeral fracture in an active calf can be successfully managed on the farm.

KEY WORDS: calf, closed repair, external skeletal fixation, humeral fracture, transfixation pinning and casting

Fracture of the humerus is infrequent in cattle, and less than 5% of fractures in cattle involve the humerus. Treatment of humeral fractures depends on the size, age, temperament, and economic value of the animal [4, 13]. Several treatment options exist, including strict stall rest [16] and internal fixation using plates and intramedullary pins [4, 13]. We have previously reported outpatient recovery of humeral fractures in calves using unilateral external skeletal fixation (ESF) with an epoxy putty fixator (type I) [18]. We also described using transfixation pinning and casting (TPC) as an alternative to ESF [1, 2, 17].

Case History: A 71-day-old female Japanese Black calf (weight, 78 kg) was referred to the Veterinary Medical Center (VMC) of Obihiro University of Agriculture and Veterinary Medicine for treatment of a suspected left humeral fracture. The fracture occurred one day prior to admission, when the calf was in a large pen with its dam to allow nursing. Physical examination revealed a rectal temperature of 39.4°C; heart rate, 120 bpm; and respiratory rate, 30 bpm. The calf was non-weight-bearing on the left forelimb, unable to fully extend the elbow, and had the appearance of a dropped elbow indicating diminished radial nerve function. Preoperative radiographs confirmed an oblique midshaft fracture of the left humerus (Fig. 1A).

First surgery: The calf was sedated with xylazine (0.1 mg/kg; 2% Seractal; Bayer, Osaka, Japan) and administered cefazolin (10 mg/kg; Cefazolin-Chu; Fujita Pharmaceutical, Tokyo, Japan) and flunixin meglumine (2 mg/kg; FORVET-50, Nagase Medicals, Itami, Hyogo, Japan) intravenously. The calf was positioned in right lateral recumbency, and the left forelimb was held upward and prepared aseptically. Lidocaine (10-mL of 2% Xylocaine; AstraZeneca, Osaka, Japan) was used for a brachial plexus block [8, 14]. The fracture was repaired using a closed approach and unilateral ESF. The ESF used four 4.0-mm threaded pins (Kirschner wire (code no. 01-134-60); Mizuho Ikakogyo, Tokyo, Japan) inserted with a power drill (part no. 30010; IMEX Veterinary Inc., Longview, TX, U.S.A.). The lateral epicondyle and the greater tubercle of the humerus were identified by palpation to identify the radial nerve. At each pin insertion site, a small stab incision was made followed by blunt dissection to the bone. Two pins were inserted percutaneously across the fracture plane to stabilize the fragments. Two additional pins were placed percutaneously in a lateral-to-medial direction into the proximal and distal fragments, respectively (Fig. 1B and 1C). The four pins inserted through the bone were in a “half-pin” configuration. A cefazolin-containing ointment (Cefamezin DC; Zenoaq, Koriyama, Fukushima, Japan) was applied around each pin site and covered with sterile gauze. The pins were cut, and the ends joined together with epoxy putty (Cemedine Epoxy Putty [for metal]; Cemedine, Tokyo, Japan) unilaterally at the extracorporeal position.

*Correspondence to: Yamagishi, N., Laboratory of Bovine Medicine, Department of Veterinary Medicine, Obihiro University of Agriculture and Veterinary Medicine, Inada Nishi 2-11, Obihiro, Hokkaido 080-8555, Japan. e-mail: yamagishi@obihiro.ac.jp

©2017 The Japanese Society of Veterinary Science



This is an open-access article distributed under the terms of the Creative Commons Attribution Non-Commercial No Derivatives (by-nc-nd) License. (CC-BY-NC-ND 4.0: <https://creativecommons.org/licenses/by-nc-nd/4.0/>)

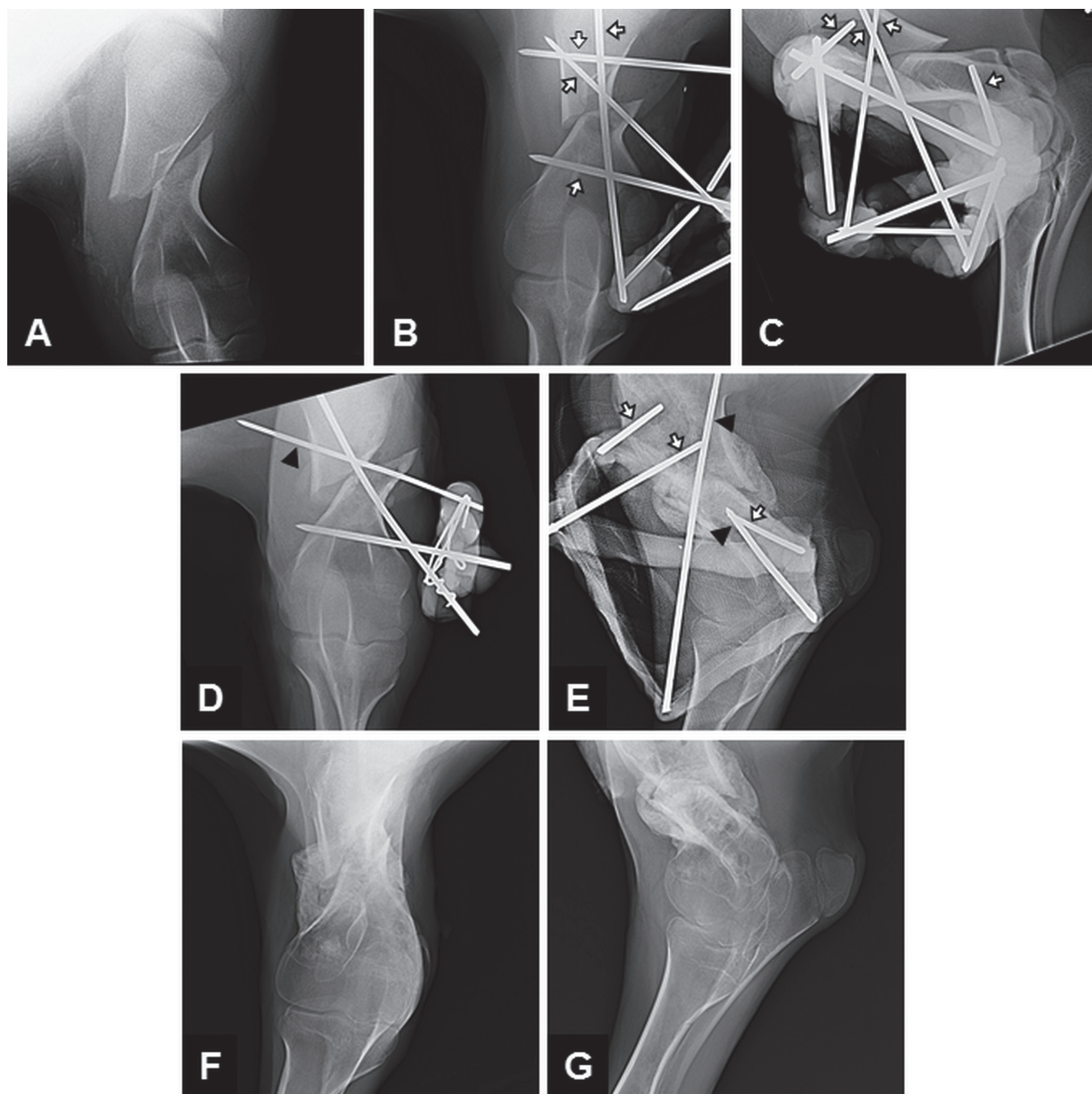


Fig. 1. Radiographs of the left humerus of a Japanese Black calf. (A) Cranio-caudal view before the first surgery. (B) Cranio-caudal and (C) lateral-medial views after the first surgery, using external skeletal fixation with four pins through the bone placed in the “half-pin” configuration (white arrows) with a unilateral epoxy putty fixator. The epoxy putty was wrapped around the pin fragments to provide strength. (D) Cranio-caudal view nine days after the first surgery showing an immature bony callus at the fracture site and three pins from the broken external skeletal fixation. Black arrows indicate the over-inserted pin. (E) Lateral-medial view 28 days after the second surgery (37 days after the first surgery) showing transfixation pinning and casting with five pins placed in the “half-pin” configuration. The black arrows indicate pins inserted at first surgery and white arrows indicate pins inserted at second surgery. (F) Cranio-caudal and (G) lateral-medial views immediately after the pins were removed 28 days after the second surgery (37 days after the first surgery).

Additional administration of intramuscular xylazine (0.05 mg/kg BW) was performed at 30-min intervals to maintain sedation during the surgery. Surgery was completed in 100 min.

After surgery, the calf was returned to the farm and the pen with the dam. Antibiotics were administered for 5 days. The calf was able to walk and bear weight on the left forelimb the day after surgery. The calf was active, and eight days after surgery slipped and fell, breaking the ESF.

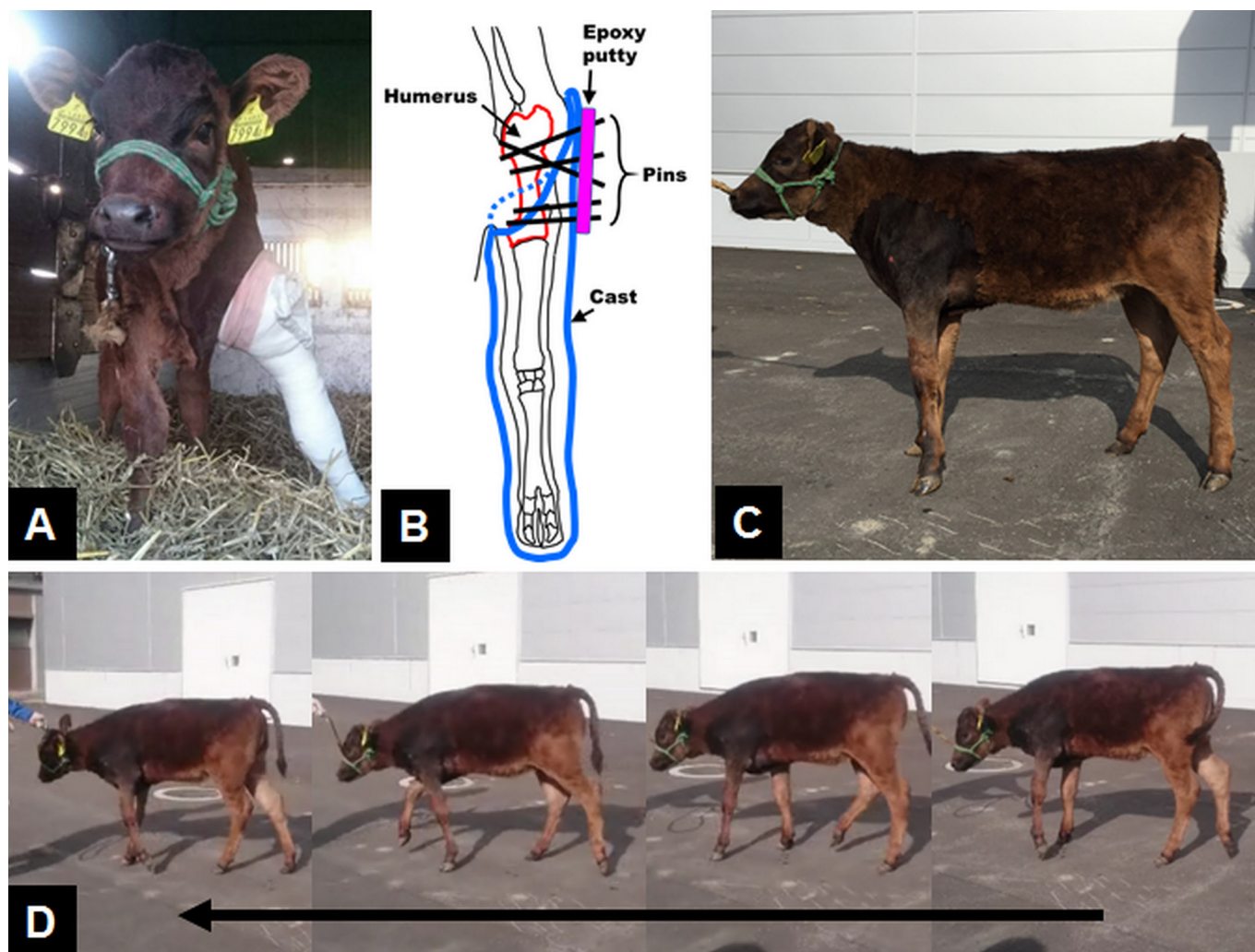


Fig. 2. Photographs of a Japanese Black calf with a fracture of the left humerus after surgery. (A) Standing posture immediately after the second transfixation pinning and casting using five pins placed through the bone in the “half-pin” configuration (nine days after the first surgery). (B) Schematic illustration of transfixation pinning and casting using five pins to stabilize the fractured humerus. (C) Standing posture of the calf after the pins were removed (37 days after the first surgery). (D) Serial images of walking after the pins were removed (37 days after the first surgery).

Second surgery: The calf returned to the VMC nine days after the first surgery. A radiograph revealed an immature bony callus at the fracture site, and one of the four ESF pins was broken (Fig. 1D). One of the pins across the fracture plane was migrated beyond the original position. To reconstruct the ESF using a cast and TPC, the calf was sedated with the brachial plexus block and prepared in the same manner as the first surgery. The over-inserted pin was removed. The other two pins (one across the fracture plane and one into the distal bone fragment) were left, as they were unbroken and remained firmly without evidence of pin tract infection. New pins were percutaneously placed from a lateral-to-medial direction into the proximal (two pins) and distal (one pin) fragments. In total, five pins were positioned into the left humerus in a “half-pin” configuration (Fig. 1E). The cefazolin-containing ointment was applied around each pin site and covered with sterile gauze. A full-limb cast incorporating the pin ends was applied (Fig. 2A). A layer of cast padding (Orthowrap 3; Alcare, Tokyo, Japan) was applied over the limb from the lateral aspect of the humerus to the sole of the foot (Fig. 2B). Five layers of fiberglass casting tape (Schotchcast Plus-J 3; 3M Japan Health Co., Tokyo, Japan) were placed over the limb. The pins were cut at the level of the cast surface, and the pin ends were joined together with epoxy putty. This surgery was completed in 90 min.

The calf returned to the farm and was confined individually to a small pen with bottle-feeding. The calf could bear the weight on the left forelimb and walk. Antibiotics were administered for five days. To promote weight bearing, 14 days after the second surgery, the distal region of the cast was truncated below the elbow joint. Twenty-eight days after surgery, the calf was sedated for radiographic examination and removal of the ESF and cast. The calf was able to stand with mild ankylosis of the elbow and carpal joints (Fig. 2C) and bear weight on the left forelimb while walking (Fig. 2D). The calf’s body weight on that day was 103 kg. Radiographs revealed bony union at the fracture site (Fig. 1E–1G). A pin tract infection, identified from a small amount of discharge at the time of pin removal, resolved with the initial systemic antibiotics and daily cleaning with sterile saline. The calf

remained in good condition, grew normally for 14 months, and is ready to be bred.

Strict stall confinement is the most common nonsurgical approach for managing humeral fractures in cattle [12]. Conservative treatment often results in normal use of the affected limb and normal growth of the animal [9]. Prognosis with conservative treatment is improved when the fracture is minimally displaced, the animal is young, and the radial nerve is intact [16]. Many Japanese Black cattle farmers rear their calves in pens with their dams to allow nursing. This management practice limits the use of conservative fracture management because it is difficult to stabilize the fractured limb [18].

Instability and displacement without contact of the proximal and distal fragments decrease the probability of a favorable result [11, 13]. Internal fixation techniques using plates and intramedullary pins have been used successfully for the repair of humeral fractures in cattle [3, 12]. However, plate fixation is rarely done in cattle, because it requires expensive implants and equipment, specialized surgical facilities, and anesthetic support for orthopedic surgery [9]. Plate fixation is also difficult in cattle due to short length and irregular surface of humerus and a heavy muscle mass surrounding the bone [12]. The intramedullary pin technique is less invasive than plating [11, 16]. Intramedullary pins cannot be used when there is extensive comminution [13], and are best suited for oblique fractures or, in combination with cerclage wires, for long oblique fractures [10]. Our group and others in Japan have previously reported favorable outcomes using unilateral ESF (type I) to manage humeral fractures in calves [7, 18]. In these cases, the owner requested repair of the fracture using a less expensive approach. In the present case, we applied ESF with the unilateral epoxy putty fixator for during the first surgery. Breakage of the ESF when the calf slipped and fell suggests a shortcoming of this fixation for active calves. In addition, the over-insertion of the pin after the ESF broke was unsafe. Therefore, stall confinement is necessary to manage humeral fractures repaired by the ESF in calves.

The calf in this case underwent surgery to reconstruct the fracture using TPC fixation after breakage of the ESF. TPC fiberglass casting tape to replace the clamp and sidebars [17]. The goal of TPC is to return the calf to full weight bearing within a time frame that minimizes hindrance of limb use [17]. Moreover, this method minimizes the distance between the bone and cast, preventing loading of the fracture site and interfragmentary movement [17]. Normally, the pins of TPC are inserted as full pins, meaning that the pins exit both sides of the limb [17]. In the present case, five pins were positioned into the left humerus in a “half-pin” configuration (Fig. 1E). The pin ends were incorporated into a full-limb cast that covered the lateral aspect of the humerus (Fig. 2B). This TPC configuration restricted the use of the affected limb and the movement of the calf and provided stability of the fracture site, even after the cast was truncated. Daily monitoring is necessary to avoid cast-related complications and acute breaking of the pins [11].

Possible disadvantages of TPC are pin tract infection, and when compared to traditional ESF, lack of access to soft tissue [1, 2, 6, 17]. Another disadvantage is restriction of joint movement and tendon and ligament laxity [11]. After the pins were removed, the calf showed ankylosis of the elbow and carpal joints (Fig. 2C). This TPC technique is a practical outpatient treatment for humeral fractures in calves, and may be used in the field setting.

In cattle, the surgical treatment of fractures requires general anesthesia, whereas external coaptation can be performed in the farm using sedation [5]. The calf in this case underwent two surgeries under xylazine-sedation and brachial plexus block, suggesting that ESF and TPC may be feasible techniques to repair humeral fractures of calves in the field setting. In the previous reports [18] and the present case, additional intramuscular administration of xylazine was necessary to maintain sedation during the surgery. Continuous infusion of propofol may be useful for maintenance anesthesia in calves [3]; however, it is necessary to include analgesia for invasive surgical procedures. Further studies are needed to establish a protocol for continuous infusion of propofol for ESF or TPC surgery in calves.

This is the first report of outpatient recovery of a humeral fracture in a calf using the TPC system with pins placed in the “half-pin” configuration (Fig. 2B). In our previous report on humeral fractures in four of five calves repaired using ESF and an open approach, the fixations were removed 47–62 days post-surgery, and clinical signs of lameness were not evident 3–4 months after surgery [18]. In that report, another one calf with closed repair could walk with weight bearing 40 days after surgery [18]. Another group in Japan reported that the ESF was removed 51 days after an open surgical approach of a humeral fracture in a 3-day-old calf [7]. In the case reported here, the period from surgery to pin removal and of the onset of weight bearing was shorter (37 days after the first surgery), and body weight gain was optimal (78 to 103 kg in 37 days). This suggests that the closed repair of a humeral fracture may be a better option than the open repair method. Potential advantages of the closed approach are preservation of local blood flow and bone stimulatory proteins at the fracture sites [1, 2, 15, 17]. Disadvantages include difficulty in fracture realignment and healing with a malunion [9]. Therefore, the closed repair approach is the preferred outpatient treatment for humeral fractures in calves using the TPC system in the field; however, the open repair method should be used in cases where an adequate reduction cannot be achieved by the closed approach.

REFERENCES

1. Anderson, D. E. and St Jean, G. 1996. External skeletal fixation in ruminants. *Vet. Clin. North Am. Food Anim. Pract.* **12**: 117–152. [Medline] [CrossRef]
2. Anderson, D. E. and St Jean, G. 2008. Management of fractures in field settings. *Vet. Clin. North Am. Food Anim. Pract.* **24**: 567–582, viii. [Medline] [CrossRef]
3. Deschk, M., Wagatsuma, J. T., Araújo, M. A., Santos, G. G., Júnior, S. S., Abimussi, C. J., Siqueira, C. E., Motta, J. C., Perri, S. H. and Santos, P. S. 2016. Continuous infusion of propofol in calves: bispectral index and hemodynamic effects. *Vet. Anaesth. Analg.* **43**: 309–315. [Medline] [CrossRef]
4. Ferguson, J. D. 1997. Surgical conditions of the proximal limb. pp. 262–276. *In: Lameness in Cattle*, 3rd ed. (Greenough, P. R. ed.), W. B.

- Saunders Company, Philadelphia.
5. Gangl, M., Grulke, S., Serteyn, D. and Touati, K. 2006. Retrospective study of 99 cases of bone fractures in cattle treated by external coaptation or confinement. *Vet. Rec.* **158**: 264–268. [[Medline](#)] [[CrossRef](#)]
6. Harari, J. 1992. Complications of external skeletal fixation. *Vet. Clin. North Am. Small Anim. Pract.* **22**: 99–107. [[Medline](#)] [[CrossRef](#)]
7. Hashimoto, T., Kobayashi, K., Shibasaki, A. and Katamoto, H. 2006. Repairing humeral fractures using external fixation in a Japanese Black calf. *J. Jpn. Vet. Med. Assoc.* **59**: 109–111 (in Japanese with English abstract). [[CrossRef](#)]
8. Iwamoto, J., Yamagishi, N., Sasaki, K., Kim, D., Devkota, B. and Furuhashi, K. 2012. A novel technique of ultrasound-guided brachial plexus block in calves. *Res. Vet. Sci.* **93**: 1467–1471. [[Medline](#)] [[CrossRef](#)]
9. Langley-Hobbs, S. J., Carmichael, S. and McCartney, W. 1996. Use of external skeletal fixators in the repair of femoral fractures in cats. *J. Small Anim. Pract.* **37**: 95–101. [[Medline](#)] [[CrossRef](#)]
10. Markel, M. D., Nunamaker, D. M., Wheat, J. D. and Sams, A. E. 1988. In vitro comparison of three fixation methods for humeral fracture repair in adult horses. *Am. J. Vet. Res.* **49**: 586–593. [[Medline](#)]
11. Pentecost, R., Niehaus, A. J. and Anderson, D. E. 2016. Surgical management of fractures and tendons. *Vet. Clin. North Am. Food Anim. Pract.* **32**: 797–811. [[Medline](#)] [[CrossRef](#)]
12. Rakestraw, P. C. 1996. Fractures of the humerus. *Vet. Clin. North Am. Food Anim. Pract.* **12**: 153–168. [[Medline](#)] [[CrossRef](#)]
13. Rakestraw, P. C., Nixon, A. J., Kaderly, R. E. and Ducharme, N. G. 1991. Cranial approach to the humerus for repair of fractures in horses and cattle. *Vet. Surg.* **20**: 1–8. [[Medline](#)] [[CrossRef](#)]
14. Re, M., Blanco, J. and Gómez de Segura, I. A. 2016. Ultrasound-guided nerve block anesthesia. *Vet. Clin. North Am. Food Anim. Pract.* **32**: 133–147. [[Medline](#)] [[CrossRef](#)]
15. Rokkanen, P., Slätis, P. and Vanka, E. 1969. Closed or open intramedullary nailing of femoral shaft fractures? A comparison with conservatively treated cases. *J. Bone Joint Surg. Br.* **51**: 313–323. [[Medline](#)]
16. Saint-Jean, G. and Hull, B. L. 1987. Conservative treatment of a humeral fracture in a heifer. *Can. Vet. J.* **28**: 704–706. [[Medline](#)]
17. Vogel, S. R. and Anderson, D. E. 2014. External skeletal fixation of fractures in cattle. *Vet. Clin. North Am. Food Anim. Pract.* **30**: 127–142, vi. [[Medline](#)] [[CrossRef](#)]
18. Yamagishi, N., Devkota, B. and Takahashi, M. 2014. Outpatient treatment for humeral fractures in five calves. *J. Vet. Med. Sci.* **76**: 1519–1522. [[Medline](#)] [[CrossRef](#)]