

Pediatric Retina Cases

Making the decision whether to proceed with surgery can be challenging.

BY BARBARA PAROLINI, MD

Surgery for retinal detachment or for macular hole is considered a routine approach for adults, but the decision to operate on a child is more difficult.

Many times, children do not immediately report the occurrence of a loss in vision either because they do not realize that they have vision loss or they do not understand the importance of reporting their symptoms. When a retinal pathology is finally discovered, in deciding whether to proceed to surgery, the following are some points for consideration:

1. Is the retinal pathology long-standing and could amblyopia contraindicate any potential benefit of surgery?
2. Might vitrectomy induce a cataract, necessitating phaco and IOL implantation? Calculating biometry can be challenging in young patients as their eyes continue to grow.
3. What if surgery induces retinal complications? The child will then have to undergo more surgery with possible further loss of peripheral and central field.
4. Can the child position properly and maintain good postoperative practices (eg, not rubbing the eye)?

Unfortunately surgeons are unable to know the answers to these questions in advance. Family counseling in pediatric cases is particularly important to make the process as acceptable and least mentally traumatic as possible.

CASE NO. 1

A 7-year-old boy was referred to me due to a strange foveal reflex in his left eye. Uncorrected visual acuity in that eye was 20\200 with loss of central fixation. The anterior segment appeared normal on examination. Biomicroscopy showed a full thickness macular hole with some pigment alterations, findings that were confirmed on optical coherence tomography (OCT).

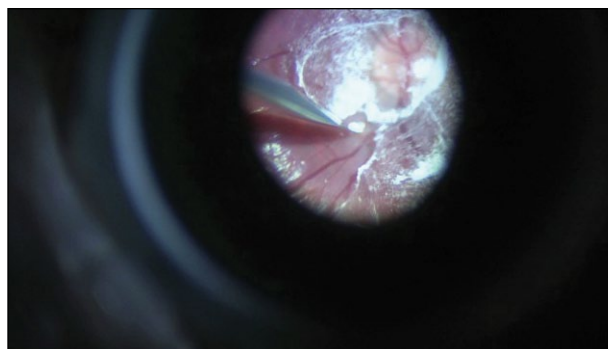


Figure 1. Posterior vitreous detachment induced by incising the ILM with a bent sclerotome.

However, OCT did not show any sign of posterior vitreous detachment. The differential diagnosis between traumatic and idiopathic macular hole remained unclear.

The parents reported that the child had an uncertain traumatic event with a ball more than 1 year previous. Even though the prognosis was not good for such a long-standing injury, the parents decided that they wanted their child to undergo surgery.

I planned to perform 20-gauge surgery with tangential sclerotomies, opening the superior conjunctiva from 3:00 to 9:00. I opted not to use trocars to lower the risk of touching the lens. My choice of 20-gauge instrumentation was made because I anticipated difficulty in detaching the vitreous, and it is my belief that a 20-gauge set-up is better for such a case.

TECHNIQUE

I used an illuminated infusion cannula to avoid entering with a fiber-optic and used only 2 sclerotomies. As I imagined, the most difficult step was detaching the vitreous from the optic nerve. Aspiration with the vitrector was not enough. Therefore, I incised the internal

limiting membrane (ILM) around the nasal side of the optic nerve with the bent tip of a microvitreoretinal blade (Figure 1). The vitrector could then aspirate the posterior cortex and detach it from the optic nerve first, and then progressively from the retina to the equator. At the equator, the adhesion seemed extremely strong, and I decided to stop exerting traction. Although I typically perform a large and wide vitrectomy in adults, for this case I considered the risk of inducing peripheral breaks during peripheral vitrectomy too high. Instead, I performed ILM peeling. After a 10-minute fluid-air exchange I repeated aspiration of residual fluid at the optic nerve several times. This maneuver is difficult and could be considered unnecessary because fluid continues to form, depositing at the papilla, particularly when there is still a large amount of vitreous in the periphery.

The superior sclerotomy self sealed because it was created tangentially and had not become enlarged with multiple instrument exchanges. However, a single-pass suture was applied to the infusion cannula sclerotomy to avoid any chance of postoperative hypotony.

One 7.0 reabsorbable suture at 3:00 and one at 9:00 were enough to close the conjunctiva, which is important to ensure that the sclerotomies remain covered. Before removing the infusion cannula, I injected 0.8 cc of SF₆ to obtain a roughly 20% mixture of gas.

POSTOPERATIVE RECOVERY

Facedown positioning was easy for my young patient to maintain, and, although there is debate on its necessity, it was something that the patient could do easily during his daily activities. He reported very little discomfort after surgery.

One week postoperative, OCT showed a closed hole with some trauma to the retinal pigment epithelium and the ellipsoidal zone in the fovea, a possible sign of the trauma that had originally caused the hole.

After 1 month, the patient's uncorrected vision improved from 20\200 to 20\40. The lens was transparent and the retina was attached with the macular hole closed.

CASE NO. 2

An 8-year-old boy presented with blurred vision in the right eye. Uncorrected visual acuity in that eye was 20\200. The anterior segment appeared normal. The eye presented a detachment of the inferior hemiretina with involvement of half of the fovea. The detachment was caused by a disinsertion of the inferotemporal retina.



Experience may help in selecting the technique with the best efficacy and fewest complications.

Pigment lines indicated that the detachment was not recent. The child was a soccer player, so trauma was a reasonable hypothesis. The child's parents, after being informed about the pathology and treatment options, decided to have the boy undergo surgery.

TECHNIQUE

I planned to apply cryotherapy along the margins of the disinsertion, implant an external buckle parallel to the limbus that would be wide enough to support both sides of the disinsertion and to avoid drainage of the subretinal fluid. The intraocular pressure was lowered with an anterior paracentesis.

One resorbable suture was placed at 3:00 and another at 9:00 to close the conjunctiva.

POSTOPERATIVE RECOVERY

In this case, like the first, the patient did well postoperatively. The detachment resolved progressively over 3 weeks with improvement in vision to 20\30. Retinal pigment epithelial modifications, however, continue to still prevent full vision restoration.

SUMMARY

The take-home messages of these cases include the following:

1. Surgery to treat vitreoretinal diseases in children is feasible.
2. Vision in children can improve more than expected, even at amblyopia age.
3. Experience may help in selecting the technique with the best efficacy and fewest complications.
4. Family cooperation and, at times, the unexpected ability of pediatric patients to comply with postoperative instructions and demands placed upon them at a young age can help the surgeon to provide good outcomes. ■

Barbara Parolini, MD, is Director of the Vitreoretinal Service at the Istituto Clinico S. Anna in Brescia, Italy. Dr. Parolini states that she has no financial relationships to disclose in relation to this article. She may be reached at parolinibarbara@gmail.com.

