

Article

Case report: minimal invasive approach in a case of cervical schwannoma

Raghuvendra Kumar, Amar C Dhal, Abhishek Kumar
INDIA



Case report: minimal invasive approach in a case of cervical schwannoma

Raghuvendra Kumar, Amar C Dhal, Abhishek Kumar

Department of Neurosurgery, IPGME&R Kolkata, INDIA

Abstract: *Purpose:* The purpose of our case report is to present our experience with minimal invasive approach in a case of cervical schwannoma. *Method:* The data of patient treated for cervical schwannoma like site, size and extension of the lesion were obtained by neuroimaging and preoperative neurological status obtained by clinical examination. The postoperative neurological status and radiological image were available. The clinical course was documented by Karnofsky score (KPS). *Result:* We approached the tumour through interlaminar fenestration in cervical (C1-C2) region. Postoperative neuroimaging revealed complete removal of the lesion and no sign of spinal instability. At discharge improvement of KPS score and neurological improvement was observed. *Conclusion:* Minimal access procedures are increasingly gaining popularity in spine surgery. The aim of the surgical procedure is minimizing the invasiveness and maximizing the efficacy. Modern neuroimaging allows adequate preoperative planning and microsurgical techniques provide adequate execution of the surgical act.

Key words: Cervical schwannomas, Interlaminar fenestration, Minimally invasive technique

Introduction

Schwannomas are the most common extramedullary spinal tumors, representing almost one-third of primary spinal neoplasms [16]; they are categorized as spinal nerve sheath tumors (NSTs) together with neurofibromas. They affect men and women in equal proportions and are mainly encountered in their 50s; they may cause signs and symptoms related to the radicular and/or spinal cord involvement in the

interested spinal level [1, 5]. The majority of schwannomas are located in the lumbar, followed by the thoracic and cervical spine [1, 6, 19].

Traditionally laminectomy is used to approach these lesions [9, 18], even if it may cause delayed postoperative spinal instability and deformities [7, 8, 18, 23], thus requiring reconstructive procedures [2, 17]. In order to prevent these complications, many authors have performed and popularized alternative

less invasive surgical techniques. In our case we approached the tumour through interlaminar fenestration in cervical c1-c2-region as our patient had idem situated in the right anterolateral position.

Patient case presentation

A 50 yr old male with average built and height, govt employee presented with the c/o weakness of all four limbs with tingling and numbness all four limb since 1 yr. History of neck pain since 1 yr. Urinary symptoms like hesitancy, frequency and urgency since 3 months.

Weakness started initially in right lower limb then involving upper limb on same side with involvement of opposite upper and lower limb in a span of 3 month. Our patient had ability to carry out normal acitivity and work with KPS of 80, with no comorbidities nor any familiy history of genetic diseases. Patient used to take pregabalin 75 mg twice a day and pantoprazole 40 mg once a day with minimal relief of symptoms as advised by physician whom patient consulted previously with no history of any drug allergy. Patient had mixed dietary habits.

On examination patient had increased tone with MRC grade of power 4/5 in all four limbs with exaggerated all deep tendon reflexes bilaterally with b/l plantar extensor and absent superficial reflex with preserved anal tone. Patient had decreased all modality of sensation below C5 level.

Imaging

Location, size, extent of the lesion, and preoperative neurological status of patient, was obtained by neuroimaging data and clinical examination. Postoperative clinical

examination and radiological images, including Computed Tomography (CT) scan and Magnetic Resonance (MR) imaging, were obtained.

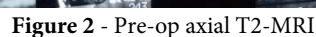
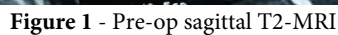
MR images (p+c), showing characteristic well marginated inhomogeneous intradural extramedullary lesion at right anterolateral aspect of spinal canal at foramen magnum, C1, C2 level with 25x29x18 mm size, causing compression at cervico-medullary junction...? neurofibroma.

Surgical procedure

After anesthetic fitness, written and informed consent, patient was planned for operation. Position-prone with slight neck flexion. Incision made from occiput to C3 spinous process. The fascia was dissected free, incised longitudinally in the mid line. Muscular insertions were dissected in a subperiosteal way from the spinous processes and from laminae. Lamina of C1 and C2 identified. Space was increased with the help of small mastoid retractor. Partial ligamentum flavectomy of ipsilateral side was done. Right sided interlaminar dural incision was made between C1 and C2 space and underlying arachnoid layering the tumor was seen. Arachnoidal separation over tumour was done. Tumour of approx. 2 x 3 cm, greyish pink, variegated consistency, lying antero lateral to cord with clear plane between tumour and adjacent cord seen. With meticulous surgical dissection tumour was completely removed in total and free flow of CSF was seen at the end of surgery. No nerve root was sacrificed to reach or to remove the tumour. Water tight dural closure done and confirmed.

Patient was extubated after procedure and

status. Pain was subsided, and there was significant improvement of neurological status. Follow up CT scan & MR images were obtained and did not reveal residual tumor. No signs of spinal instability found on CT scan. Histological examination confirmed the diagnosis of schwannoma.





0 1



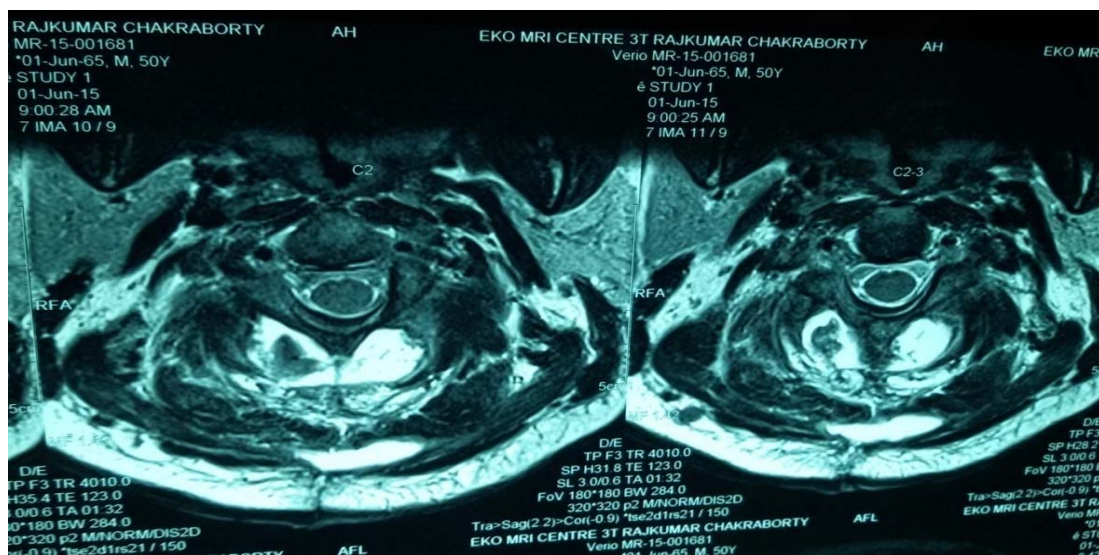


Figure 4 - Post-op T2 MRI, axial & coronal section

Discussion

Traditionally open posterior laminectomy is used to approach these lesions. Multiple risk factors are associated with cervical spine deformity after laminectomy including age (11, 15, 22) location and extension of laminectomy (upper, middle, or lower cervical spine) (3, 11, 22) number of laminae removed, preoperative loss of lordosis (10, 11) intraspinal pathologies (10, 14) degree of facet resection (11). Kaptain et al. (10) reported that the risk of postoperative deformities doubled when the spine was deformed preoperatively. Fassett et al. (8) noted a 14% incidence of postoperative kyphosis in patients who initially had a lordotic cervical spine, and more than twice the incidence (30%) in patients whose spine was straight (4° of lordosis or kyphosis) preoperatively. Spinal cord lesions alone, without surgical destabilization, can cause

spinal deformities in both adults and children (20).

Extent of laminectomy and then the exposure of dura mater are related to the formation of epidural scar tissue and so to the risk of postoperative spinal-fluid fistulae (13). Fibrosis often produces adhesions tethering the nerve root to adjacent tissues, impeding nerve mobility and increasing tension on the nerve during motion, leading to pain, due to local nerve fiber traction, and to nerve injury (4). Reduction of the scar formation is associated with clinically better results (21), emphasizing the importance of preventing the formation of epidural fibrosis through devices, such as good sterile technique, meticulous hemostasis, and in particular minimal tissue trauma.

In this case, we discuss our surgical experience in the treatment of cervical schwannomas. Ability in microsurgical

techniques has allowed us to remove spinal tumor. Exploiting the wider space between the vertebrae C1 and C2, we performed an interlaminar fenestration, with decreasing iatrogenic trauma. In our patient, no complication was observed. Static and dynamic plain radiograph films and CT scan showed no kyphosis and/or instability postoperatively and also during follow-up.

Postoperative MR images demonstrated complete tumor removal, without epidural fibrosis. Clinical and neurological results were good.

Conclusion

Minimal access procedures are increasingly gaining popularity in spine surgery. The aim of the surgical procedure is minimizing the invasiveness and maximizing the efficacy. Modern neuroimaging allows adequate preoperative planning and microsurgical techniques provide adequate execution of the surgical act. The procedure has to be tailored case by case considering the specific lesional features and the individual anatomical situation.

Correspondence

Dr. Raghuvendra Kumar, Department of neurosurgery, Institute of Postgraduate Medical Education & Research (IPGME&R) Kolkata, PIN-700020, India
Mobile no: 09007366440, 07238085537
Email: dr.raghuvendrakumar@gmail.com

References

1. Abbasi SS, Senoglu M, Theodore N et al (1998) Microsurgical management of spinal schwannomas: evaluation of 128 cases. *J Neurosurg Spine* 9:40–47
2. Alexander E Jr (1985) Postlaminectomy kyphosis. In: Wilkins RH, Rengachary SS (eds) *Neurosurgery*, vol 3. McGraw-Hill, New York, pp 2293–2297
3. Aronson DD, Kahn RH, Canady A et al (1991) Instability of the cervical spine after decompression in patients who have Arnold-Chiari malformation. *J Bone Joint Surg Am* 73:898–906
4. Cemil B, Tun K, Kaptanoglu E et al (2009) Use of pimecrolimus to prevent epidural fibrosis in a postlaminectomy rat model. *J Neurosurg Spine* 11:758–763
5. Cerqui A, Kim DH, Kim SH (2007) Surgical approaches to paraspinal nerve sheath tumors. *Neurosurg Focus* 22(6):E9
6. Conti P, Pansini G, Mouchaty H (2004) Spinal neurinomas: retrospective analysis and long-term outcome of 179 consecutively operated cases and review of the literature. *Surg Neurol* 61:35–44
7. Deutsch H, Haid RW, Rodts GE, Mummaneni PV (2003) Postlaminectomy cervical deformity. *Neurosurg Focus* 15(3):E5
8. Fassett DR, Clark R, Brockmeyer DL, Schmidt MH (2006) Cervical spine deformity associated with resection of spinal cord tumors. *Neurosurg Focus* 20(2):E2
9. Guidetti B (1974) Removal of extramedullary benign spinal cord tumors. In: Krayenbuhl II, Brihaje J, Loew F (eds) *Advances and technical standards in neurosurgery*, vol 1. Springer, New York, pp 173–197
10. Kaptain GJ, Simmons NE, Replogle RE et al (2000) Incidence and outcome of kyphotic deformity following laminectomy for cervical spondylotic myelopathy. *J Neurosurg* 93(Suppl 2): 199–204
11. Katsumi Y, Honma T, Nakamura T (1989) Analysis of cervical instability resulting from laminectomies for removal of spinal cord tumor. *Spine* 14:1171–1176
12. Koch Wiewrodt D, Wagner W, Perneczky A (2007) Unilateral multilevel interlaminar fenestration instead of laminectomy or hemilaminectomy: an alternative surgical approach to intraspinal space-occupying lesions. *Neurosurg Spine* 6:485–492
13. La Rocca H, Macnab I (1974) The laminectomy membrane. Studies in its evolution, characteristics, effects and prophylaxis in dogs. *J Bone Joint Surg Br* 56:545–550
14. Lonstein JE (1977) Post-laminectomy kyphosis. *Clin Orthop Relat Res* 128:93–100

15. Mikawa Y, Shikata J, Yamamuro T (1987) Spinal deformity and instability after multilevel cervical laminectomy. *Spine* 12:6–11
16. Nittner K (1976) Spinal meningiomas, neurinomas and neurofibromas and hourglass tumors. In: Vinken PJ, Bruyn Gw (eds) *Handbook of clinical neurology*, vol 20. Tumors of the Spine and Spinal Cord. North-Holland, Amsterdam, pp 177–322
17. Raimondi AJ, Gutierrez FA, Di Rocco C (1976) Laminotomy and total reconstruction of the posterior spinal arch for spinal canal surgery in childhood. *J Neurosurg* 45:555–560
18. Schwartz TH, McCormick PC (2004) Spinal cord tumors in adults. In: Winn HR (ed) *Youmans neurological surgery*, vol 4, 5th edn. WB Saunders, Philadelphia, pp 4817–4834
19. Seppala MT, Haltia MJ, Sankila RJ, Jaaskelainen JE, Heiskanen O (1995) Long-term outcome after removal of spinal schwannomas: a clinicopathological study of 187 cases. *J Neurosurg* 83:621–626
20. Sim FH, Svien HJ, Bickel WH et al (1974) Swan-neck deformity following extensive cervical laminectomy. A review of twentyone cases. *J Bone Joint Surg Am* 56:564–580
21. Tatsui CE, Martinez G, Li X, Pattany P, Levi AD (2006) Evaluation of DuraGenh in preventing peridural fibrosis in rabbits. *J Neurosurg Spine* 4:51–59
22. Yasuoka S, Peterson HA, MacCarty CS (1982) Incidence of spinal column deformity after multilevel laminectomy in children and adults. *J Neurosurg* 57:441–445
23. Yeh JS, Sgouros S, Walsh AR, Hockley AD (2001) Spinal sagittal malalignment following surgery for primary intramedullary tumors in children. *Pediatr Neurosurg* 35(6):318–324