

Case Report

Combined hepatocellular - cholangiocarcinoma: a diagnostic challenge

E.K.D.M.Wickramaratne¹, A.Dharmapala² and S.Wijetunge¹

¹Department of Pathology, Faculty of Medicine, University of Peradeniya, Sri Lanka; ²Department of Surgery, Faculty of Medicine, University of Peradeniya, Sri Lanka

DOI: <http://doi.org/10.4038/jdp.v11i2.7707>

Submitted on 02.10.2016 Accepted for publication on 10.12.2016

Introduction

Combined hepatocellular-cholangiocarcinoma (cHCC-CC) is a rare primary liver tumour with histopathological features of both hepatocellular carcinoma (HCC) and cholangiocarcinoma (CC) (1). This neoplasm demonstrates unequivocal, intimately mixed elements of HCC and CC (2). In collision tumours HCC is juxtaposed with CC without intermingling of the two elements, hence excluded in the WHO classification of cHCC-CC (3).

Primary hepatic neoplasms containing both elements of HCC and CC were initially described in 1903 by Wells; however, the first comprehensive description was published in 1949 by Allen and Lisa (4). The reported incidence of cHCC-CC among primary liver malignancies ranges from 1.0% to 4.7%, however this tumour is being increasingly recognized currently (3). Age and sex specific incidence and geographic distribution of this tumour are similar to HCC (2).

As cHCC-CCs are uncommon, the knowledge on clinical course is limited and some studies revealed that they have intermediate clinical features to that of HCC

and CC. Similar to HCC alpha fetoprotein levels are elevated in cHCC-CC, and there is no reported difference between the levels observed in the two types of tumours (5). Studies indicate that although cHCC-CC are also observed in patients with cirrhosis and chronic hepatitis B or C, the frequency is less than that of HCC (4,6). Furthermore, imaging studies of these neoplasms may differ according to the predominant component and therefore, enhancement patterns depend on the distribution of the components of HCC and CC within the tumour (3). For accurate preoperative diagnosis a biopsy should be performed. However, due to the heterogeneity of the tumour, a core biopsy may be not representative enough and could only contain one of the two components, leading to misdiagnosis of the lesion as either HCC or CC (5). Complete surgical resection of the tumour is the treatment of choice for non-cirrhotic patients with localized disease. However, cHCC-CC is reported to be more aggressive with higher recurrence risk and the overall poorer prognosis than with conventional HCC or CC (5-7).

Case report

Clinical history

A 66-year-old lady presented with right sided abdominal pain for 6 months. She also

Author for correspondence:

E.K.D.M. Wickramaratne (MBBS, Dpath),
Department of Pathology, Faculty of Medicine,
University of Peradeniya, Sri Lanka. E mail:
diliniwickramaratne@gmail.com

complained of recent loss of weight and appetite. The patient did not have a past history of malignancy. On examination, she was emaciated and had mild pallor. Icterus was not detected. Abdominal examination revealed tenderness in the right hypochondrium with moderate hepatomegaly.

She was anaemic with a Haemoglobin level of 10.6 g/dl. Alpha feto protein level was 7010 IU/ ml (Reference range – <5.5 IU/ml). The liver enzymes were mildly elevated.

Pathological features

The cut surfaces of the specimen showed a nodular mass measuring 17x12x12cm. The tumour nodules were predominantly solid, tan white and showed extensive friable areas suggestive of necrosis (Fig.1 B). A para-aortic lymph node was also included with the specimen.

Microscopic examination of the mass revealed a biphasic tumour composed of polygonal cells closely resembling hepatocytes with a trabecular arrangement and cuboidal cells arranged in glandular structures resembling an adenocarcinoma. The former component had only mild cellular pleomorphism and trabeculae were more than three cells in thickness as demonstrated

with reticulin stain (Fig. 2A), confirming that this component is a well differentiated HCC. The glandular component comprised moderately pleomorphic cuboidal cells and a desmoplastic stroma (Fig. 3A). The two components were admixed and the interphase regions showed solid nests resembling HCC gradually transforming into glandular structures (Fig. 4). There was extensive tumour necrosis. Non-neoplastic liver tissue did not show features of cirrhosis.

The glands showed evidence of intracytoplasmic mucin production with Periodic acid-Schiff stain with diastase digestion and alcian blue stain (Fig. 3B) and HCC like areas were negative for mucin. Immunohistochemical profile of the HCC like area was as follows: positive HepPar-1 (Fig. 2 B) and alfa feto protein, canalicular positivity with CD10 and CEA (Fig. 2D) and negative CK 7 (Fig. 2C). The glandular areas were positive for cytokeratin 7 (Fig. 3C) and negative for HepPar 1(Fig. 3D) and alfa feto protein; neither cannalicular staining pattern nor cellular positivity was seen with CD10 and CEA. Accordingly, the tumour was diagnosed as a combined hepatocellular-cholangiocarcinoma.

The para-aortic lymph node was free of tumour and it showed extensive non specific reactive changes.

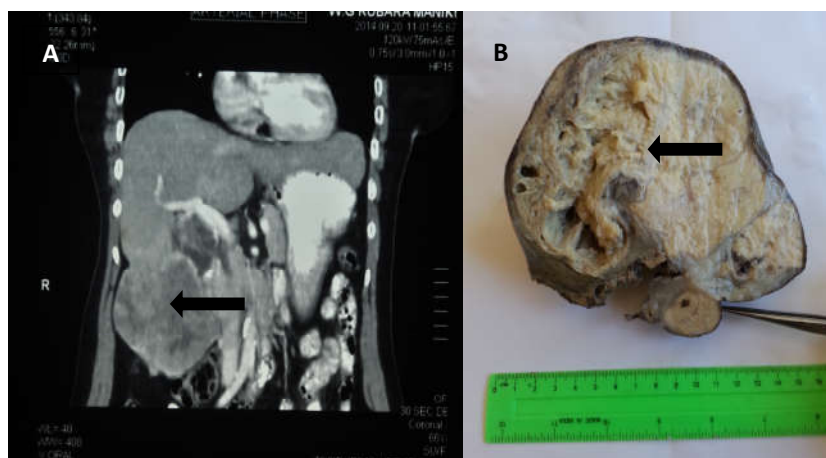


Figure 1 A) Computed tomographic scan image of the tumour. The tumour is seen as an exophytic mass in the right lobe of the liver (arrow) B) The gross appearance of the resected tumour showing a vaguely nodular mass involving most of the resected right lobe of the liver (arrow).

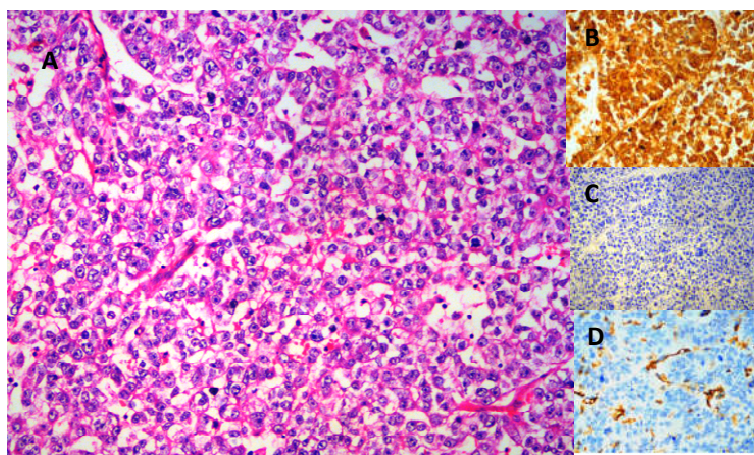


Figure 2 Hepatocellular carcinoma component of the tumour. A) Neoplastic cells resembling hepatocytes with minimal pleomorphism arranged in trabeculae. (Haematoxylin and eosin stain x 20) B) HepPar 1 showing granular cytoplasmic positivity (x 40) C) Negative cytokeratin 7 (x 40) D) CD10 highlighting a canalicular pattern (x 40).

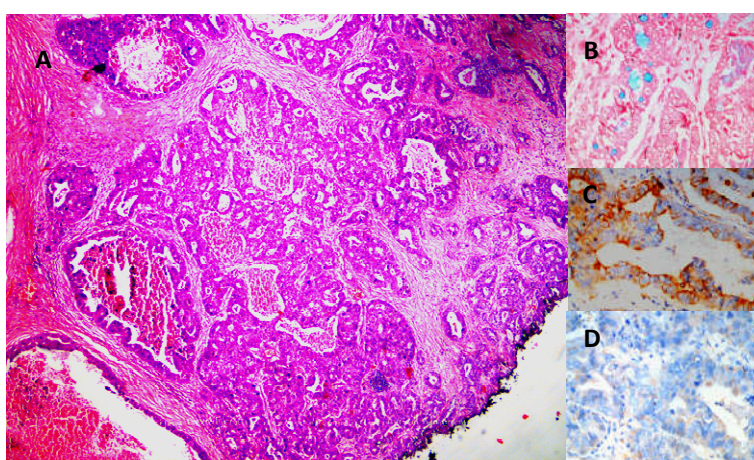


Figure 3 Glandular component of the tumour A) Neoplastic glandular structures surrounded by desmoplastic stroma (Haematoxylin and eosin stain x 40) B) Alcian blue shows luminal positivity (x 40) C) cytokeratin 7 revealing membrane and cytoplasmic positivity in glandular areas (x 40) D) Negative Hep Par 1 (x 40)

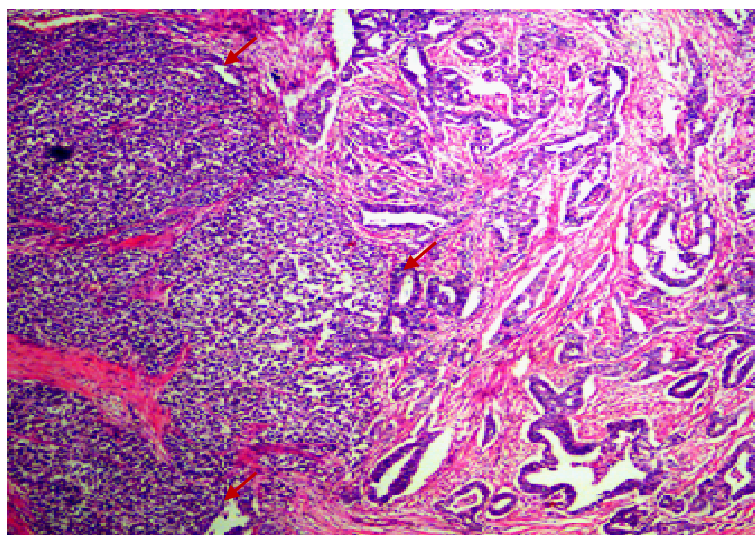


Figure 4 – Solid nests of neoplastic hepatocytes (left) transforming into glandular structures (right) within the same cluster at the interphase. (arrow) (Haematoxylin and eosin stain x 40)

Discussion

WHO classification of liver tumours (2010) classifies cHCC-CC into classical type and three subtypes with stem cell features (2). In the classical type, there are areas of typical HCC intermixed with areas of typical CC. The hepatocellular component is recognized by the trabecular growth pattern, bile production or intercellular bile canaliculi. Confirmation of this component can be done by performing immunostains such as HepPar-1 and alpha fetoprotein and the bile canaliculi can be demonstrated with anti-CD10 and/or polyclonal carcinoembryonic antigen (CEA). Glypican-3 is a relatively novel marker that is expressed in most HCC but not in normal adult liver tissue (8,9). Subtypes with stem cell features are extremely rare and includes tumours predominantly containing cells that have phenotypical or immunophenotypical features of stem/progenitor cells. However, in this case there were no features to support a stem cell differentiation such as small cells with hyperchromatic nuclei with CK7 expression. The cholangiocarcinoma component is usually a typical adenocarcinoma containing definite glands often embedded in a desmoplastic stroma. Mucin production may be demonstrated histochemically by using special stains for mucin such as digested Periodic acid-Schiff, alcian blue and mucicarmine. Immunohistochemically these cells are positive for CK7, CK19 and MOC31 and are negative for hepatocellular markers. In addition, most of the tumours show foci of intermediate morphology at the interface of HCC and CC components. These areas can have cells with stem cell-like KIT positivity. Furthermore, these transition areas stain for CK 7 and 19 as well as HepPar-1 (2,5-7). Histopathology is the only reliable method to make a definitive diagnosis of cHCC-CC and proper sampling including the transitional area is essential to come to an accurate diagnosis (7).

Histological differential diagnosis in the present case includes well differentiated HCC with acinar/pseudoglandular pattern, metastatic adenocarcinoma in the liver, HCC–

CC collision tumour, cHCC-CC and a metastatic adenocarcinoma in a HCC. Occasionally HCC demonstrate acinar arrangement of cells surrounding a space mimicking an adenocarcinoma. However, these are not true glands and formed by dilated bile canaliculi like structures. These pseudoglandular regions are negative for mucin stains and show positive staining with CD10 and polyclonal CEA and Hep Par 1 and negative staining with MOC31, CK7 and CK19. However, occasionally HCC can express CK7 and CK19 (3). In the present case, positive mucin stains and positive cytokeratin 7 with negative HepPar-1 staining of glands confirmed that they are true glands, excluding the possibility of HCC with acinar/pseudoglandular pattern.

Histologically, HCC like component in the present tumour was well differentiated and the cells resembled normal hepatocytes with minimal cellular atypia. Therefore, metastatic adenocarcinoma in benign hepatic tissue also comes into the histological differential diagnosis. However, presence of more than 3 cell thick trabeculae confirmed that the hepatic component is neoplastic. In collision tumours the two tumour types abut each other with a sharp demarcation between the tumours, whereas in combined/composite tumours the components are intermixed with a transitional zone. Due to intricate admixture of two tumour components, a collision tumour is unlikely in the present case. The extremely rare possibility of metastatic adenocarcinoma in a HCC is unlikely due to the absence of clinical evidence of a primary tumour elsewhere. Accordingly, the tumour was diagnosed as a combined hepatocellular-cholangiocarcinoma.

In conclusion, cHCC-CC is a rare hepatic neoplasm that can be misdiagnosed as either HCC or CC, both clinically and histopathologically, especially in core biopsies. As this tumour is reported to show a worse prognosis with a more aggressive clinical course, it is important to arrive at a correct diagnosis. High index of suspicion on radiology, proper sampling and thorough

histological evaluation with immunohistochemistry are essential for the diagnosis of cHCC-CC.

References

1. Ming C, Mikhitarin K, Shi C, Goft LW. Management of Combined Hepatocellular-Cholangiocarcinoma: A Case Report and Literature Review. *Gastrointestinal Cancer Research* 2012; 5:199–202.
2. Theise ND, Nakashima O, Park YN, Nakanuma Y. Combined hepatocellular – cholangiocarcinoma. In: Bosman FT, Carneiro F, Hruban RH, Theise ND (eds), *WHO classification of tumours of the digestive system* 2010; 4th edition: 225-227.
3. Yeh MM. Pathology of combined hepatocellular-cholangiocarcinoma. *Journal of Gastroenterology and Hepatology* 2010;25: 1485–1492.
4. Jarnagin WR et al. Combined Hepatocellular and Cholangiocarcinoma. Demographic, Clinical, and Prognostic Factors. *Cancer* 2002; 94:2040-2046.
5. Combined hepatocellular – cholangiocarcinoma c(HCC-CC): a distinct entity. *Annals of Hepatology* 2014; 13: 317-322.
6. Farrel L, Kakar S. Tumours of the liver, biliary tree and gall bladder. In: Fletcher CDM (ed), *Diagnostic histopathology of tumours*. 4th edition.: 496-497.
7. Maximin S et al. Current update on Combined hepatocellular –cholangiocarcinoma. *European Journal of Radiology Open* 2014; 1:40-48
8. Capurro M. et al. . Glypican-3: a novel serum and histochemical marker for hepatocellular carcinoma. *Gastroenterology*. 125, 89–97 (2003).
9. Nakatsura T, Nishimura Y. Usefulness of the novel oncofetal antigen glypican-3 for diagnosis of hepatocellular carcinoma and melanoma. *Bio Drugs*. 2005;19:71-7.