

Case Report

Bladder neurofibroma: A rare cause of pelvic mass

Raju Agarwal^{*1}, RK Shrivastava², Sazia Khan³, RD Wadhwa VSM⁴, Madhusudan Dey⁵ and Anupam Kapur⁶

¹Associate Professor, Department of Obstetrics and Gynecology, Armed Forces Medical College, Pune India

²Department of Surgical Oncology, Command Hospital, Pune, India

³Resident, Department of Obstetrics and Gynecology, Armed Forces Medical College, Pune, India

⁴HOD & Professor, Department of Obstetrics and Gynecology, Armed Forces Medical College, Pune, India

⁵Reader, Department of Obstetrics and Gynecology, Armed Forces Medical College, Pune, India

⁶Professor, Department of Obstetrics and Gynecology, Armed Forces Medical College, Pune, India

* Correspondence Info:

Dr. Raju Agarwal,
Associate Professor,
Department of Obstetrics and Gynecology,
Armed Forces Medical College, Pune India
Email: rajumona@hotmail.com

Abstract

Neurofibromatosis is an inherited autosomal dominant disease and it rarely involves genitor-urinary tract. Urinary bladder is the commonest organ involved in cases of urinary tract involvement and patients generally presents with urinary symptoms. We are presenting a case of neurofibroma of bladder without urinary symptoms.

Keywords: Neurofibroma, Bladder, Pelvic mass, Malignancy, Cystectomy

1. Introduction

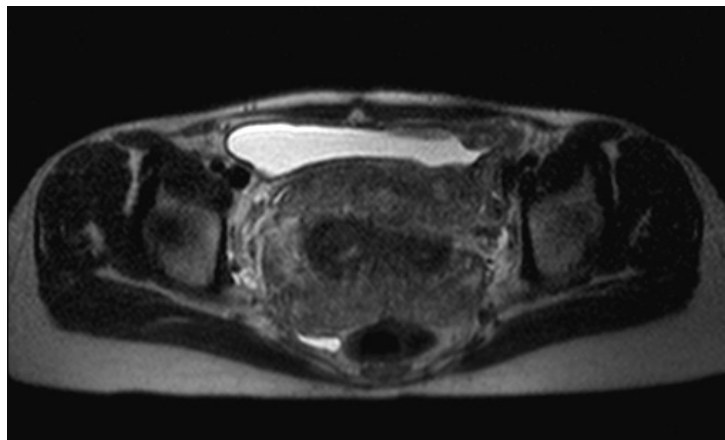
Neurofibromatosis or Von Recklinghausen's disease is a pathology that features dominant autosomal transmission caused by a mutation in the NF1 gene, which is located on chromosome 17q11.2. It demonstrates 100% penetration but a highly variable phenotypic expression¹. The incidence of systemic disease is 1 in every 3000 births; however, urogenital involvement is rare, and only about 70 cases with urinary manifestation have been described, in most cases featuring involvement of the bladder². It is known that there is a 12 to 29% risk of malignant transformation and so follow-up with such patients is important, as is resection of the lesion whenever there is a suspicion of malignant transformation³. We present a rare case of a nerve sheath tumor of the bladder in a young patient presenting without any urinary symptoms.

2. Case Report

A previously healthy 24-year-old Para1 lady presented with left sided lower abdominal pain and swelling of 3yrs duration, which was dull aching type with no aggravating or relieving factors. She also gave history of progressively increasing multiple nodular swellings over her entire body for past 5yrs. She however gave no menstrual or urinary complaints. Her previous delivery was a term caesarean section for fetal distress 3yrs back. Her medical history was unremarkable. On physical examination she had multiple 1-2cm subcutaneous nodules over her face, neck, trunk, back, upper and lower limbs along with café-au-lait spots. Her abdominal examination revealed an 18wk gravid uterine size mass arising from pelvis, non tender, immobile and firm in consistency. A per vaginal examination revealed the mass being anterior to uterus and closely abutting the cervix. She had no neurological deficit.

MRI abdomen showed a large pelvic mass (8x10cm) of solid consistency extending from just below the fundus of uterus till pelvic floor; encasing the uterus and cervix circumferentially (Fig 1). The external and internal iliac vessels were displaced laterally. IVU showed extrinsic impression of pelvic mass on urinary bladder with dilated ureters. FNAC from the mass showed no atypical or malignant cells. Cystopanendoscopy revealed a bulge in posterior bladder wall, with pin hole ureteric orifices and pulled up ureters. Bilateral ureteral stenting was done after difficult dilatation of ureters with Double J stents.

Fig 1 T weighted MRI image showing heterogenous lobulated bladder mass along with its extent



The patient underwent an exploratory laparotomy through midline supra umbilical incision. During the intra-operative dissection 10 x 10 cm mass was noted at fundus of urinary bladder, adherent to anterior uterine surface. It was dissected from surrounding structures. Bladder had to be opened up and ureteric orifices identified. The fundus of bladder and posterior wall dissected out from uterus. Partial cystectomy along with total abdominal hysterectomy was done as the bladder mass was inseparable from the cervix (Fig 2). Complete removal of the lesion could be achieved. Intraoperative frozen section revealed benign neurofibroma. The final histopathology report was consistent with plexiform neurofibroma of the urinary bladder (Fig 3). Post operative recovery was uneventful and she was discharged on 5th post-op day and urinary catheter was removed on 14th post-op day.

Fig 2 Gross specimen of bladder with a large variegated mass

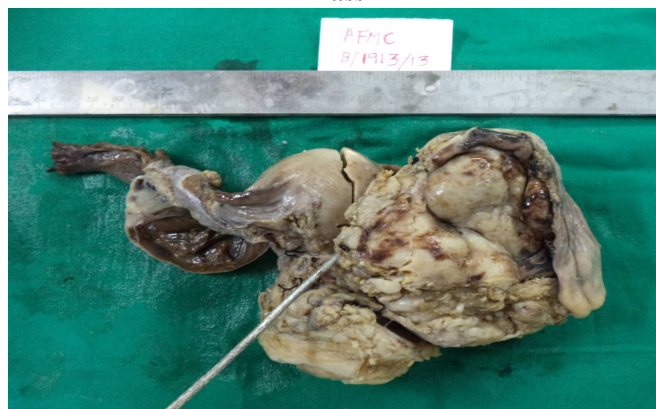
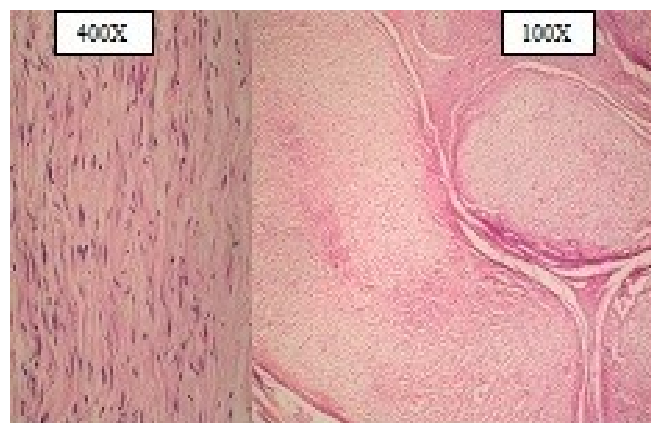


Fig 3 Plexiform neurofibroma



3. Discussion

Neurofibromatosis type 1 (NF1) is an inherited disorder that predominantly affects the skin and peripheral nervous system. NF1 is characterized by wide variability of clinical forms, and most patients with NF1 have only milder manifestations of the disease, such as pigmentary lesions and Lisch nodules. The diagnosis can be made if two or more of the following are present: (a) six or more café au lait spots, (b) two or more neurofibromas, (c) one or more plexiform

neurofibromas, (d) freckling in the axilla or inguinal region, (e) optic glioma, (f) two or more Lisch nodules, (g) a distinctive osseous lesion, or (h) a first-degree relative with NF1.⁴ The diagnosis is usually suspected in childhood when café au lait spots are identified and our patient had three out of eight features. Visceral or extracutaneous involvement is rare and seen only in 1% of cases⁵. Neurofibromas appear to be derived from the pelvic, vesical, and/or prostatic nerve plexuses, which form a continuous network, allowing the plexiform neurofibroma to spread and involve multiple organs. However, urinary bladder is the most common site for genitor-urinary tract involvement⁶. The condition is more common in males than females by a ratio of 3:1. The spectrum of urologic presentation includes urinary frequency or urgency and hematuria with or without a palpable abdominal or pelvic mass. However, in some cases, dysfunctional voiding or even urinary retention related to mass localization may occur. Diffuse plexiform neurofibroma involving the genitor-urinary system is uncommon and volume of the disease does not correlate with the degree of symptomatology⁷. Our case presented as palpable abdomino-pelvic mass and pain which was due to compression of surrounding structures.

Imaging techniques are useful for assessing the manifestations of neurofibromatosis especially for the lesions in abdominopelvic and cranial regions. Neurofibromas can be visualized with many imaging modalities. Ultrasonography is often the initial investigation and neurofibromas appear as solid, round or oval masses that are relatively nonspecific and may look very similar to a leiomyoma. Bladder involvement can manifest as a focal mass or diffuse bladder wall thickening in the case of a plexiform neurofibroma. However, CT and MR imaging are often needed to further characterize the abnormality and to better define the extent of tumor involvement. No systemic lesion was found in our patient's scans. These techniques are useful in either early detection of neurofibromas or a possible malignant transformation; suspicious radiological signs of malignancy include an asymmetry in size and heterogeneity in CT attenuation⁸. Our patient had a large asymmetric and heterogeneous mass in MRI of the abdomen; however, no malignant transformation was detected in the pathologic examination. In radiological investigations, bladder involvement can only be seen as a thickening of the bladder wall or a large mass just like our patient.

Treatment of patients with NF1 and bladder involvement is not standard and depends on the extent of disease, the symptoms, and suspicion for malignant degeneration. Anticholinergic medication is helpful in cases where patients are presents with irritative voiding symptoms. If the disease progresses during this conservative treatment, most patients develop obstructive voiding symptoms due to the mass effect of the lesion and may require surgery. Removal of the mass allows for more accurate pathological diagnosis; thus, a possible cure of the disease can be achieved⁹. In our patient, we performed a partial resection of the bladder. Recurrence is common, as it is difficult to resect the entire tumour. Most cases reported in the literature have been treated with local excisions. Surveillance may be the only treatment for asymptomatic disease.

In conclusion, the patients of generalized neurofibromatosis presenting as pelvic mass the possibility of neurofibroma of the genitor-urinary tract should be considered.

References

1. Brasfield RD, DasGupta TK: Von Recklinghausen's disease: a clinicopathological study. *Ann Surg.* 1972; 175: 174-83.
2. Salvitti M, Celestino F, Gerocarni Nappo S, Caione P. Diffuse ganglioneuromatosis and plexiform neurofibroma of the urinary bladder: an uncommon cause of severe urological disease in an infant. *J Paed urology* 2013 Jun;9(3):e131-3.
3. Clark SS, Marlett MM, Prudencio RF, and Dasgupta TK, "Neurofibromatosis of the bladder in children: case report and literature review," *Journal of Urology*, 1977; 118(4):654-656.
4. Mulvihill JJ, Parry DM, Sherman JL, Pikus A, Kaiser-Kupfer MI, Eldridge R. NIH conference. Neurofibromatosis 1 (Recklinghausen disease) and neurofibromatosis 2 (bilateral acoustic neurofibromatosis): an update. *Ann Intern Med* 1990; 113:39-52
5. Nasir AA, Abdur-Rehman LO, Ibrahim KO, Adegoke MA, Afolabi JK, Adeniran JO. Genitourinary plexiform neurofibroma mimicking sacrococcygeal teratoma. *J Surg Tech Case report*: 2012;4:50-2
6. Pycha A, Klingler CH, Reiter WJ, Schroth B, Haitel A, Latal D: Von Recklinghausen neurofibromatosis with urinary bladder involvement. *Urology.* 2001; 58:
7. Kaefer M, Adams MC, Rink RC, Keating MA. Principles in management of complex pediatric genitourinary plexiform neurofibroma. *Urology.* 1997;49:936-40.
8. E. Levine, M. Huntrakoon, and L. H. Wetzel, "Malignant nerve-sheath neoplasms in neurofibromatosis: distinction from benign tumors by using imaging techniques," *American Journal of Roentgenology*, 1987;149(5):1059-1064.
9. Üre I, Gürocak S, Gönül II, Sözen S, Deniz N. Neurofibromatosis Type 1 with Bladder Involvement. *Case Reports in Urology*, 2013; 1-3.