

Edwards Intuity Aortic Bioprosthesis in Patient with Bicuspid Aortic Valve

OANA MARIA CORÎCI^{1,2}, M. GAȘPAR¹, G. LAUFER³, MARIA IANCĂU²

¹Institute of Cardiovascular Medicine, Cardiac Surgery Department, Timisoara, Romania

²University of Medicine and Pharmacy of Craiova, Romania

³AKH-Vienna, Cardiac Surgery Department, Vienna, Austria

ABSTRACT: Bicuspid aortic valve (BAV) is generally considered to be a contraindication to sutureless aortic valve replacement (AVR). Implantation of the Edwards Intuity aortic bioprosthesis is an innovative approach associated with superior hemodynamic performance, significantly reduced myocardial ischaemia and cardiopulmonary bypass times and proves to be suitable for type 1 and 2 of bicuspid aortic valves replacement. We report a case of successful AVR using a fast deployment bioprosthesis, the Edwards Intuity Valve System, in a 67-year-old woman with a bicuspid aortic valve and concomitant severe aortic stenosis.

KEYWORDS: bicuspid aortic valve, aortic valve replacement, sutureless bioprosthesis.

Introduction

A congenital bicuspid aortic valve is present in approximately 1% to 2% of the population and is more prevalent in men, accounting for 70% to 80% of cases. Most patients with bicuspid valve develop calcific valve stenosis later in life, typically presenting with severe aortic stenosis after the age of 50 years [1,2]. Open-heart operations with aortic valve

replacement (AVR) remain the standard treatment for patients with severe symptomatic aortic valve disease [3].

We herein describe an innovative approach for AVR, the Edwards Intuity Valve System (Fig.1), in a 67 year-old woman with bicuspid aortic valve and severe aortic valve stenosis, performed through a full median sternotomy.

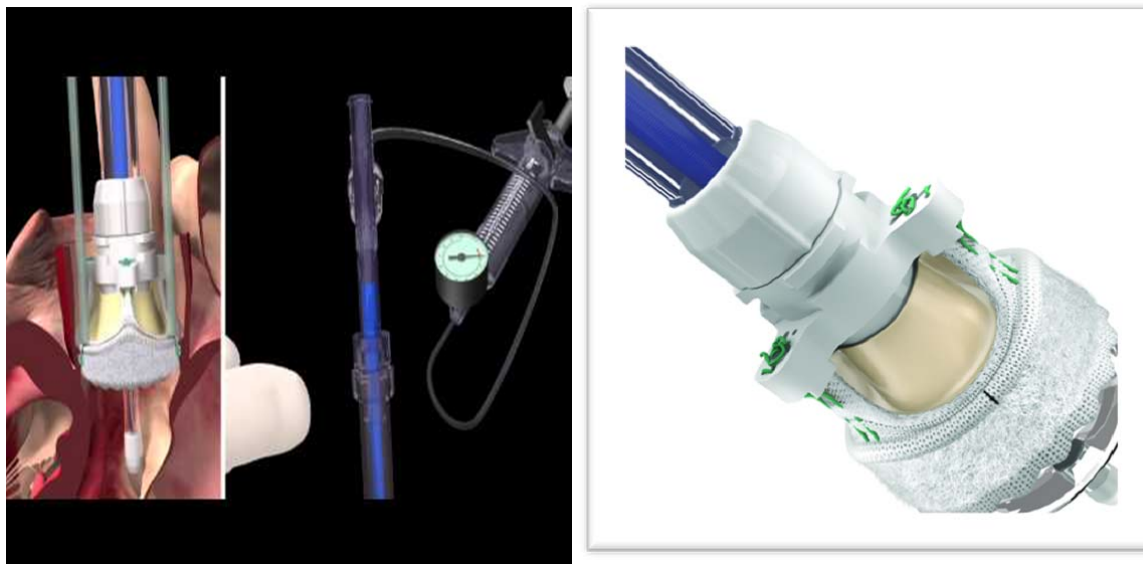

Fig.1. Edwards Intuity Valve System.

Case presentation

The patient is a 67-year-old female with symptomatic, severe aortic stenosis that was referred to our hospital for surgical correction of this pathology. Auscultation revealed a systolic grade 4/6 murmur at the right sternal border. Chest radiography showed moderate cardiomegaly. The patient was on sinus rhythm.

Transthoracic echocardiography showed a morphologically bicuspid aortic valve with evidence of severe aortic valve stenosis. The aortic annulus diameter was 24 mm, the aortic orifice area was 0.5 cm² and the mean aortic transvalvular pressure gradient was 53 mmHg with preserved left ventricular function. The patient has dilated ascending aorta (44 mm). Mild tricuspid regurgitation was present, and

mitral valve showed a I/II regurgitation. Angiography demonstrated severe aortic valve

stenosis with evidence of normal coronary arteries. (Fig.2).

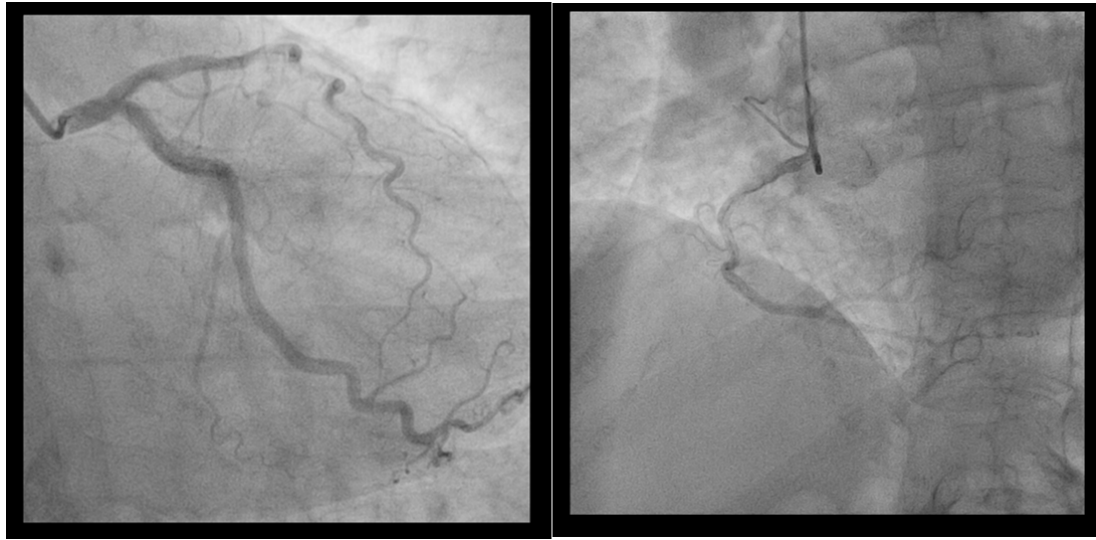

Fig 2. Angiography demonstrated the evidence of normal coronary.

Our approach for AVR involves a full median sternotomy. The skin incision is started at the sternal fork and extended 15 cm inferiorly. An oscillating saw is used to perform the sternotomy. The pericardium is opened in an inverted T incision.

Operation

CPB was instituted with aortic and bicaval cannulation and the heart arrested with antegrade and retrograde normothermic blood cardioplegia. Venting of the left ventricle is performed via the right superior pulmonary vein, the main pulmonary artery. Transverse aortotomy was performed ~3 cm above the commissures and aortic valve was inspected. Morphologically, we found a bicuspid aortic

valve with an anterior-posterior orientation, with fusion of the right and noncoronary cusps.

The calcified aortic valve is removed in the standard manner for AVR surgery. Then, the sizer is placed through the aortic annulus for an accurate sizing. The proper size in our patient is a 23 mm bioprosthesis.

Once the proper size is confirmed, the corresponding valve is washed in saline solution for three minutes and then loaded onto the delivery system. Three braided, non-pledgeted 2-0 sutures are placed at the nadir of each aortic valve sinus using a horizontal mattress technique. The sutures are then separately placed at the black markers of the sewing ring of the Intuity valve and snared with a tourniquet[4]

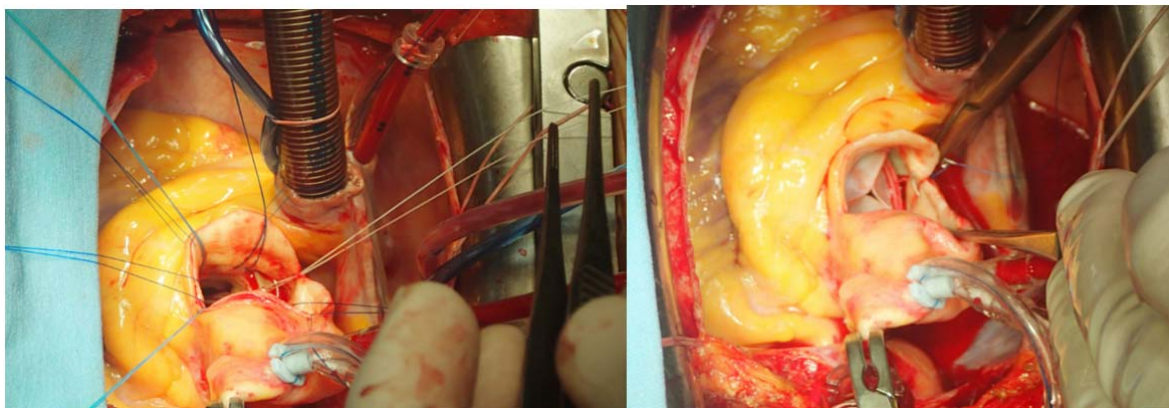


Fig.3. Intraoperative photographs

The valve is lowered into place in the aortic annulus and the tourniquets are snared (Fig.3).

Once annular seating is confirmed, the balloon is inserted through the holder and the stent is deployed using balloon inflation with saline to the appropriate pressure (4.5 atm) for a period of ten seconds. The balloon is deflated thereafter and the delivery system is removed. The guiding sutures are tied and final inspection of the valve is performed in order to confirm proper seating[4].

Closure of the aorta, sternum and subcutaneous tissues are performed in the usual manner. Transesophageal echocardiography is performed to confirm good function of the Intuity valve prosthesis and to rule out a paravalvular leak.

Postoperative course was uneventful. Patient was discharged home 6 days after the surgery.

Discussion

The development of rapid deployment aortic valves represents a significant advancement for AVR surgery [4]. At present, three sutureless bioprostheses are available on the market: 3f Enable (Medtronic Inc., Minneapolis, Minnesota, USA), Perceval (Sorin Group, Saluggia, Italy) and Intuity (Edwards Lifesciences, Irvine, California, USA)[5].

The current case involves an successful implantation of an EDWARDS INTUITY rapid deployment valve (Edwards Lifesciences, Irvine, CA, USA) by a full median sternotomy in a patient with bicuspid aortic valve and severe aortic stenosis. A theoretic advantage of Edwards Intuity Valve System is the fast implantation and consequently a reduced crossclamp and CPB time. Gunther *et al.* reported in a consecutive series of 46 patients an aortic cross-clamp (ACC) time of 41.3 ± 20.3 min (MIS RDAVR) vs. 54.0 ± 20.3 min (FS AVR) in 48 patients[6]. In our case, the ACC time was 38 minutes. However, the Edwards Intuity Valve System has several more advantages in the case of aortic valve dysfunction than conventional AVR: superior hemodynamic performance, facilitate broader application of minimal invasive approaches for AVR, better solution for sclerotic and calcified roots and annuli (e.g.calcified homograft, stentless bioprosthesis), reduced perioperative anticoagulation[6] Borger *et al.* performed a multicenter, prospective, randomized, controlled trial comparing MIS AVR with the Edwards Intuity valve to standard full-sternotomy AVR with a conventional stented bioprosthesis . A

total of 100 patients were randomized into the two groups. Patients randomized to MIS AVR with the Intuity valve had a significantly shorter aortic cross clamp time, despite the fact that these procedures were performed with MIS techniques. In addition, he showed that Intuity patients had significantly lower transvalvular gradients and a lower proportion of patient-prosthesis mismatch when compared to those who received a conventional bioprosthesis[7].

The anatomic limitations which are mentioned are bicuspid aortic valves type 0, but seems to be feasible for type 1 and type 2[6]. Herein , we performed a successful implantation of a fast deployment bioprosthesis,the Edwards Intuity Valve System, in a 67-year-old woman with a type I bicuspid aortic valve. Another limitation is that the surgeon is unable to conform the annulus to the sewing ring, as is the case for conventional AVR surgery with sutures, therefore, accurate sizing of the annulus is crucial for all rapid deployment valves. Overestimating the size of the annulus will result in a paravalvular leak. Underestimating the size of the annulus will lead to valve “pop-out” which requires immediate re-replacement of the aortic valve either with a second, properly sized Intuity prosthesis or a conventional bioprosthetic valve[4].

In addition, perioperative and early follow up results are very favorable. We also noticed shorter ICU and hospital lengths of stay, and decreased ventilation times.

Conclusions

We reported a case of successful AVR using a fast deployment bioprosthesis, the Edwards Intuity Valve System, in a 67-year-old woman with a bicuspid aortic valve and concomitant severe aortic stenosis.

In conclusion, Edwards Intuity sutureless bioprosthesis implantation is a feasible and safe procedure in patients with bicuspid aortic valve, type 1 and 2.

Moreover, the Edwards Intuity Valve System has several more advantages in the case of aortic valve dysfunction than conventional AVR: superior hemodynamic performance, facilitate broader application of minimal invasive approaches for AVR, better solution for sclerotic and calcified roots and annuli (e.g.calcified homograft, stentless bioprosthesis), reduced perioperative anticoagulation.

References

1. Nguyen A, Fortin W, Mazine A, Bouchard D, Carrier M, El Hamamsy I, Lamarche Y, Demers P. Sutureless aortic valve replacement in patients who have bicuspid aortic valve. *J Thorac Cardiovasc Surg.* 2015 Jun 21. pii: S0022-5223(15)01036-3.
2. Mann D.L., Braunwald's Heart Disease Family, 10th Ed., Bicuspid Aortic Valve Disease, p.1468-1469. Elsevier
3. Concistrè G., Farneti P., Miceli A., Glauber M., Sutureless aortic bioprosthesis in severe aortic root calcification: an innovative approach. *Interact Cardiovasc Thorac Surg.* 2012 May;14(5):670-2.
4. Borger M.A. Minimally invasive rapid deployment Edwards Intuity aortic valve implantation. *Ann Cardiothorac Surg.* 2015 Mar;4(2):193-5.
5. Santarpino G, Fischlein T. Use of sutureless prosthetic aortic valves in cardiac surgery. *G Ital Cardiol (Rome).* 2014 Mar; 15(3):170-6. Article in Italian
6. Kocher A.A., Laufer G., Haverich A., Shrestha M., Walther T., Misfeld M, Kempfert J., Gillam L., Schmitz C., Wahlers T.C., Wippermann J., Mohr F.W., Roth M., Skwara A., Rahmanian P., Wiedemann D., Borger M.A.. One-year outcomes of the Surgical Treatment of Aortic Stenosis With a Next Generation Surgical Aortic Valve (TRITON) trial: a prospective multicenter study of rapid-deployment aortic valve replacement with the EDWARDS INTUITY Valve System. *J Thorac Cardiovasc Surg.* 2013 Jan;145(1):110-5; discussion 115-6. doi: 10.1016/j.jtcvs.2012.07.108. Epub 2012 Oct 8
7. Borger M.A., Moustafine V., Conradi L. et al. A randomized multicenter trial of minimally invasive rapid deployment versus conventional full sternotomy aortic valve replacement. *Ann Thorac Surg* 2015;99:17-25

Corresponding Author: Oana Maria Corîci, Ph.D. Student, University of Medicine and Pharmacy of Craiova, Petru Rares St. no.2, Craiova 200349, Romania; e-mail:oana.andreea.corici@gmail.com