

International Journal of Biomedical and Advance Research

ISSN: 2229-3809 (Online); 2455-0558 (Print)

Journal DOI: [10.7439/ijbar](https://doi.org/10.7439/ijbar)

CODEN: IJBABN

Case Report**Vertebral body reconstruction using antibiotic impregnated bone cement (PMMA) in osteomyelitis of lumbar spine: Case reports**

**J. Praneeth Kumar Reddy^{1*}, Paparaja Murthy², B.S.Nazeer¹, Manohar P.V¹
and Anil Kumar S.V¹**

¹Department of orthopedics, Sri Devaraj Urs Medical College, Kolar, Karnataka, India²Department of Neurosurgery, Sri Devaraj Urs Medical College, Kolar, Karnataka, India***Correspondence Info:**

Dr. J. Praneeth Kumar Reddy

Junior resident,

Department of orthopedics,

Sri Devaraj Urs Medical College, Kolar, Karnataka, India

E-mail: Praneeth.reddy89@gmail.com**Abstract**

Osteomyelitis has long been one of the most common, difficult and challenging problem confronted by the surgeons in daily practice. The key to successful management is early diagnosis and appropriate treatment. The first line in treatment of vertebral osteomyelitis is conservative. There is an increased risk of deep infection with the use of spinal instrumentation. Therefore, the placement of implants in an infected area remains a matter of debate. We present two patients with lumbar vertebral osteomyelitis using antibiotic impregnated PMMA for vertebral body reconstruction and pedicle screw fixation. Post-operative follow-up showed satisfactory results both symptomatically and neurologically. The antibiotic impregnated bone cement acts as both interbody spacer and an antibiotic carrier. However, a long term outcome in both the cases requires further evaluation.

Keywords: Lumbar spine osteomyelitis, vertebral body reconstruction, Antibiotic impregnated PMMA, Citrobacter koseri, Spinal tuberculosis

1.Introduction

Osteomyelitis is defined as inflammation of bone and its marrow due to microorganisms. The infection involves the marrow spaces, the haversian canals and the subperiosteal space. The involvement of bone is secondary.

Osteomyelitis has long been one of the most common, difficult and challenging problem confronted by the surgeons in daily practice. Vertebral osteomyelitis was recognized as a distinct clinical entity by Hippocrates and Galen. In the early 1990s, about 20% of patients with osteomyelitis died and patients who survived had significant morbidity. Currently mortality is now rare because of modern treatment methods which include use of antibiotics and aggressive surgical treatment. Nevertheless, morbidity is still common. The key to successful management is early diagnosis and appropriate treatment.

The first line of treatment in vertebral osteomyelitis is conservative. However, development of severe kyphosis, neurological deficits, paravertebral abscess and failure of conservative treatment are often indications for surgery[1],[4]. There is an increased risk of deep infection with the use of spinal instrumentation. Therefore, the placement of implants in an infected area remains a matter of debate; partly focus on questions as to whether the implants interfere with control of infection[3],[7],[14].

Studies show that high antibiotic concentrations in local lesion can be achieved by releasing antibiotic agent mixed with PMMA beads chain into surrounding soft tissues. In clinical application, antibiotic PMMA beads chain has been used in treating patients with open fractures, chronic osteomyelitis, total joint arthroplasty and soft tissue infections for decades[2],[4][8],[9][12],[13]. In this

article, we described about vertebral body reconstruction using antibiotic impregnated bone cement (PMMA), which is an acrylic based resin, biocompatible, nondegradable material along with pedicle screw fixation for lumbar spine osteomyelitis. The antibiotic impregnated bone cement acts as both interbody spacer and an antibiotic carrier.

2. Case reports

2.1 A 50 year old female presented with complaints of progressive worsening backache, low fever, loss of weight, loss of appetite and inability to walk (Neurogenic claudication). Patient is a known case of L4-L5 spondylodiscitis and is on ATT for the past 4 months. On examination pallor was present and vitals were stable. Tenderness present over the spinous processes of L4-L5. Neurological examination showed motor deficits in both lower limbs. Plain radiography and MRI LS spine done showed L4-L5 Spondylodiscitis with destruction of L4 lower $\frac{1}{2}$ and L5 upper $\frac{1}{2}$ vertebral bodies. The impression diagnosis was made as L4-L5 spondylodiscitis(vertebral tuberculosis).

Under general anesthesia with endotracheal intubation, patient was placed in prone position. Through posterior approach and mid-line vertical incision surgical region was exposed. Intra-operatively degenerated L4-L5 disc with destruction of L4 and L5 bodies were noted. L3, L5 pedicle screw fixation was done followed by excision of the necrotic and granulation tissue, L4-L5 disc and partialcorpectomy of L4 vertebra was carried out. Gentamycin impregnated bone cement (PMMA) was placed in the corpectomy defect. The disc material and osteomyelitic bone was sent for histopathological evaluation which revealed chronic granulomatous lesion consistent with tuberculosis.

Post operatively intravenous antibiotics and analgesics were given for a period of 5-7 days along with ATT was continued. Patient was gradually mobilized with LS belt on 3rd post-op day and continued for a period of 12 weeks.

Patient had significant symptomatic improvement after surgery and was reviewed periodically on OPD basis at 6 weeks and 12weeks. At a 12 week follow-up back pain was resolved completely with improved power of bilateral lower limbs in addition to the improvement of general condition. There were no fresh complaints. Long term outcome requires further evaluation.

Figure 1: Pre-op imageIntra-op image

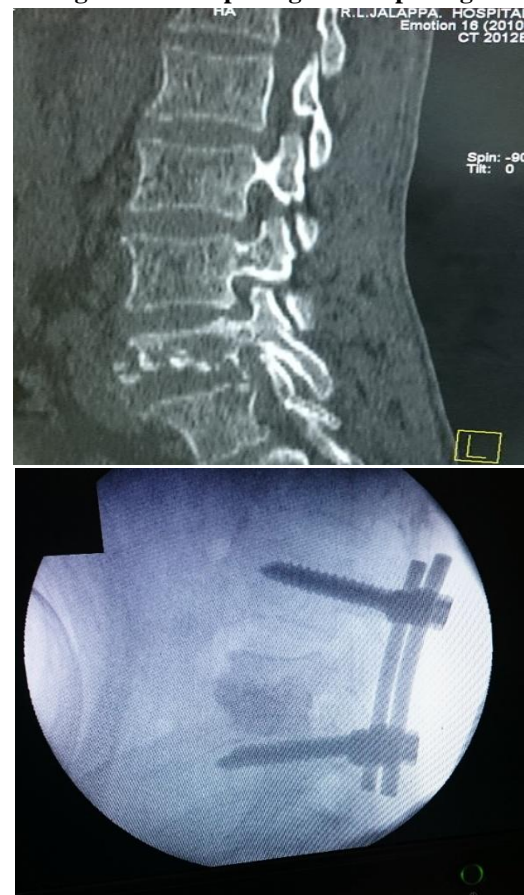
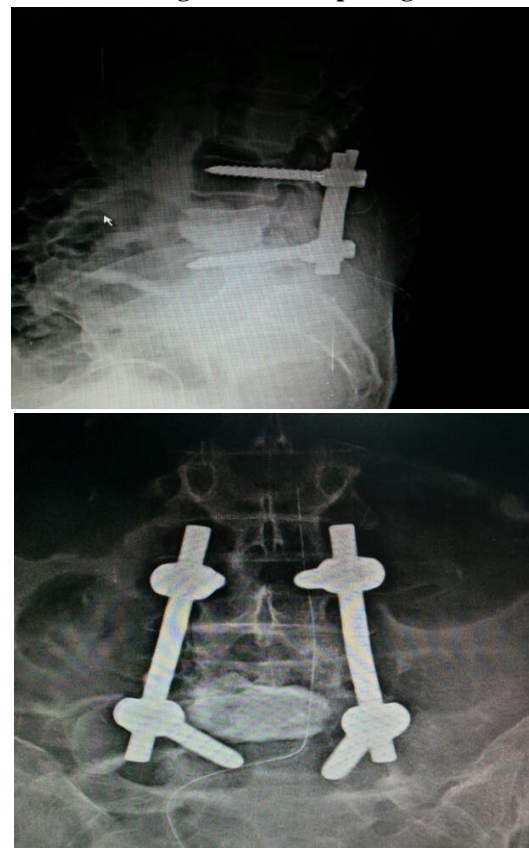


Figure 2: Post-op images



2.2 A 40 year old male presented to a physician with complaints of intermittent fever, chills and low back ache for the past one month. He was evaluated and diagnosed to have Pyrexia of unknown origin with thrombocytopenia, Alcohol dependent state and L5-S1 spondylodiscitis. He was treated conservatively with empirical antibiotics and after one week he presented to us with complaints of worsening backache and unable to walk. On examination patient was pale and vitals were stable. Tenderness present over the spinous processes of L5-S1 with paraspinal muscle spasm. Neurological examination done showed motor deficits in bilateral lower limbs. Plain radiography and MRI LS spine showed features suggestive of L5-S1 spondylodiscitis, early spondylodiscitis at L2-L3 level, disc bulge with annular tear at L4-L5 causing bilateral nerve root and thecal compression. The impression diagnosis was made as spondylodiscitis L5-S1 with epidural enhancing soft tissue.

Under general anesthesia with endotracheal intubation, patient was placed in prone position. Through posterior approach and mid-line vertical incision surgical region was exposed. Intra-operatively epidural soft tissue noted which is moderately vascular and firm, degenerated L5-S1 disc, erosion of L5 inferior endplate and destruction of inferior half of L5 vertebral body were noted. Neural decompression was carried out with L4 hemi and L5 total laminectomy, excision of osteomyelitic L5 body along with Gentamycin impregnated bone cement placement and L5,S1 pedicle screw fixation. The disc material and osteomyelitic bone was sent for microbiology and histopathological evaluation. Culture and sensitivity of the disc material reported *Citrobacter koseri* (diversus)(Amp-C producer) which is sensitive to gentamycin. HPE of disc and osteomyelitic bone reported as Chronic non-specific osteomyelitis.

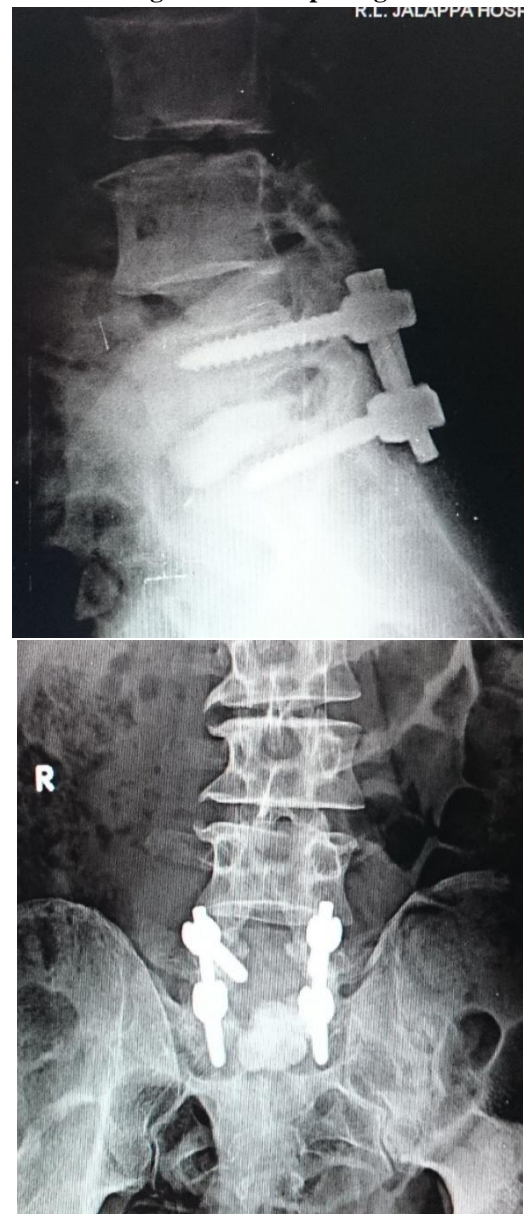
Post operatively appropriate intravenous antibiotics and analgesics were given for a period of 2 weeks. Patient was gradually mobilized with LS belt on 3rd POD and continued for a period of 12 weeks.

Patient had significant symptomatic improvement after surgery and was reviewed periodically on OPD basis at 6 weeks and 12 weeks. At a 12 week follow-up back pain was resolved completely with improved power in bilateral lower limbs in addition to the improvement in his general condition. There were no fresh complaints. Long term outcome requires further evaluation.

Figure 3: Pre-op image

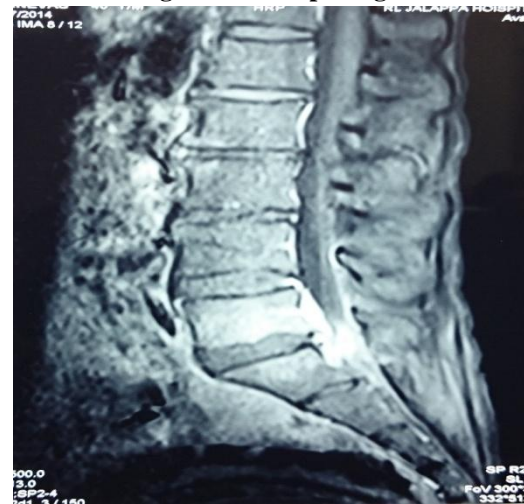

Figure 4: Post-op images



3. Discussion

With the advent of modern diagnostic aids, use of effective antibiotics and advancement in the surgical treatment, the prognosis of spinal osteomyelitis has improved significantly. The infection can be presented as acute, sub-acute or chronic. Common causes result from surgeries, penetrating wounds, open fractures, ulcers or systemic infections. The most common initial symptom is backache which is non-specific. Fever may not be invariably present. Neurological impairment such as sensory loss, weakness or radiculopathy can be seen in 30% of the cases. Due to variable clinical presentation, gold standard investigation of choice remains biopsy and culture of the lesion tissue for obtaining definitive diagnosis. Rise in the ESR and CRP values are highly sensitive in diagnosing vertebral osteomyelitis. MRI has led to early diagnosis with a sensitivity of 100% and specificity of 88%[1][4]. High signal intensity within the disc on T2-weighted sequences can be typically noticed. In diagnostic accuracy Positron-emission tomographic (PET) scanning with 18F-fluorodeoxyglucose is similar to that of MRI. The key to successful management is early diagnosis and appropriate treatment.

The first line of treatment in vertebral osteomyelitis is conservative. However, development of severe kyphosis, neurological deficits, paravertebral abscess and failure of conservative treatment are often indications of surgery[1][4]. The goals of surgery include infection control, prevention of neurological impairment and achieving spinal stability. There is an increased risk of deep infection with the use of spinal instrumentation. Therefore, the placement of implants in an infected area remains a matter of debate; partly focus on questions as to whether the implants interfere with control of infection[3][7],[14].

Studies show that high antibiotic concentrations in local lesion can be achieved by releasing antibiotic agent mixed with PMMA beads chain into surrounding soft tissues. In clinical application, antibiotic PMMA beads chain has been used in treating patients with open fractures, chronic osteomyelitis, total joint arthroplasty and soft tissue infections for decades[2],[4][8],[9][12],[13]. After placement of antibiotic-PMMA beads chain in vivo, toxic side effects are ruled out with low antibiotic concentration in serum and urine. Before the implantation of antibiotic-PMMA for spinal reconstruction, thorough radical debridement by removing all sequestered bony fragments along with necrotized disc tissue is mandatory. Pedicle screw

fixation is mandatory in reconstruction of vertebra with antibiotic-PMMA for obtaining spinal stability.

Postoperatively patients were improved symptomatically with backache and neurological function. Infection eradication was achieved and spinal stability was maintained well with pedicle screw fixation and vertebral reconstruction with PMMA.

The benefits of spinal reconstruction with PMMA are: Firstly it is inexpensive and easily available. Secondly it is simple to prepare and easily applicable. Thirdly it is biocompatible, non-magnetic, inert and rigid. Fourthly it provides same stability and framework effect as any other grafts and it can be made into unlimited size. Fifthly it can be moulded to appropriate shape required. Finally it is composed of not metal but polymer materials which can display sufficient clarity the interface between the vertebra and itself while performing CT scanning [10].

4. Conclusion

In our cases with osteomyelitis of Lumbar Spine, vertebral body reconstruction using antibiotic impregnated Bone cement (PMMA) offered satisfactory results with improvement symptomatically and neurologically without any signs of infection recurrence. Though, long term outcome requires further evaluation.

References

- [1] Jain A K: Tuberculosis of the spine: A fresh look at an old disease. *J Bone Joint Surg Br* 2010; 92(7):905-913.
- [2] Alonge T O, Ogunlade SO, Omololu A B, Fashina AN, Oluwatosin A: Management of chronic osteomyelitis in a developing country using ceftriaxone-PMMA beads: an initial study. *Int J Clin Pract* 2002; 56(3):181-183.
- [3] Choma T, Burrke M, Kim C, Kakarlapudi R: Epidural abscess as a delayed complication of spinal instrumentation in scoliosis surgery: A case of progressive neurologic dysfunction with complete recovery. *Spiner (Phila Pa 1976)* 2008; 33(3):E76-80.
- [4] Tuli SM: Tuberculosis of the spine: A historical review. *Clin Orthop Relat Res* 2007; 460: 29-38.
- [5] Joseph T N, Chen AL, Di Cesare PE: Use of antibiotic impregnated cement in total joint arthroplasty. *J Am Acad Orthop Surg* 2003; 11(1):38-47.
- [6] Klemm K: The use of antibiotic-containing bead chains in the treatment of chronic bone infections. *Clin Microbiol Infect* 2001; 7(1):28-31.

- [7] Krause F G, deVries G, Meakin C, Kalla TP, Younger AS: Outcome of transmetatarsal amputations in diabetics using antibiotic beads. *Foot Ankle Int*2009; 30(6):486-493.
- [8] Kim JI, Suh KT, Kim SJ, Lee J S: Implant removal for the management of infection after instrumented spinal fusion. *J Spinal Disord Tech* 2010; 23(4):258-265.
- [9] Mohanty S P, Kumar MN, Murthy NS: Use of antibiotic-loaded polymethyl methacrylate beads in the management of musculoskeletal sepsis--a retrospective study. *J Orthop Surg (Hong Kong)* 2003; 11(1):73-79.
- [10] Stone PA, Armstrong PA, Bandyk DF, Brumberg RS, Flaherty SK, Back MR, Johnson BL, Shames ML: Use of antibiotic loaded polymethylmethacrylate beads for the treatment of extra-cavitary prosthetic vascular graft infections. *J VascSurg*2006; 44(4):757-761.
- [11] Chen JF, Wu CT, Lee SC, Lee ST: Hollow cylindrical polymethylmethacrylate strut for spinal reconstruction after single-level cervical corpectomy. *J Neurosurg Spine*2006; 5(4):287-293.
- [12] Soultanis K, Mantelos G, Pagiatakis A, Soucacos PN: Late infection in patients with scoliosis treated with spinal instrumentation. *ClinOrthopRelatRes*2003; 411:116-123.
- [13] Taggart T, Kerry RM, Norman P, Stockley I: The use of vancomycin- impregnated cement beads in the management of infection of prosthetic joints. *J Bone Joint Surg Br*2002; 84(1):70-72.
- [14] Wang J, Calhoun J H, Mader J T: The application of bioimplants in the management of chronic osteomyelitis. *Orthopedics*2002; 25(11):1247-1252.
- [15] Talu U, Gogus A, Ozturk C, Hamzaoglu A, Domanic U: The role of posterior instrumentation and fusion after anterior radical debridement and fusion in the surgical treatment of spinal tuberculosis: Experience of 127 cases. *J Spinal Disord Tech* 2006; 19(8):554-559.
- [16] Wan JUN, Kang YI-JUN, Chen FEI, LvGUO-HUA, LiDONG-ZHE: Application of an antibiotic crescent-shaped polymethyl methacrylatestrut in thoracic vertebral tuberculosis. *Neurosurg (Turkish)* 2013; 23(1):107-112.
- [17] Rihn JA, Lee JrY, Ward W T: Infection after the surgical treatment of adolescent idiopathic scoliosis: Evaluation of the diagnosis, treatment, and impact on clinical outcomes. *Spine (Phila Pa 1976)*2008; 33(3):289-294.
- [18]Chen JF, Lee ST: Antibiotic-polymethylmethacrylate strut: An option for treating cervical pyogenic spondylitis. Case report. *J Neurosurg Spine*2006; 5(1):90-95.
- [19]Pan HC, Wang YC, Lee CH, Yang DY: Hollow bone cement filled with impacted cancellous bone as a substitute for bone grafts in cervical spine fusion. *J Clin Neurosci* 2007; 14(2):143-147.
- [20]Chen JF, Lee ST, Wu CT: A hollow cylindrical PMMA strut for cervical spine reconstruction after cervical multilevel corpectomy. *J Spinal Disord Tech*2010; 23(5):321-327.
- [21]Mihir B, Vinord L, Umesh M, Chaudhary K: Anterior instrumentation of the cervicothoracic vertebrae: Approach based on clinical and radiologic criteria. *Spine (Phila Pa 1976)*2006; 31(9):E244-249.
- [22]Chen JF, Wu CT, Lee SC, Lee ST: Use of a polymethylmethacrylate cervical cage in the treatment of single-level cervical disc disease. *J Neurosurg Spine* 2005; 3:24-28.
- [23]Anguita-Alonso P, Rouse MS, Piper KE, Jacofsky DJ, Osmon DR, Patel R: Comparative study of antimicrobial release kinetics from polymethylmethacrylate. *Clin Orthop Relat Res* 2006; 445:239-244.
- [24]Dai LY, Jiang LS, Wang W, Cui YM: Single-stage anterior autogenous bone grafting and instrumentation in the surgical management of spinal tuberculosis. *Spine (Phila Pa 1976)*2005; 30(20):2342-2349.
- [25]Hamburger C, Festenberg FV, Uhl E: Ventral discectomy with PMMA interbody fusion for cervical disc disease: Long-term results in 249 patients. *Spine* 2001; 26:249-255.
- [26]Jin D, Qu D, Chen J, Zhang H: One-stage anterior interbodyautografting and instrumentation in primary surgical management of thoracolumbar spinal tuberculosis. *Eur Spine J*2004; 13(2):114-121.
- [27]Lee CG, Fu YC, Wang CH: Simulation of gentamicin delivery for the local treatment of osteomyelitis. *Biotechnol Bioeng*2005; 91(5):622-635.
- [28]Lin SY, Desmond E, Bonato D, Gross W, Siddiqi S: Multicenter evaluation of Bactec MGIT 960 system for second-line drug susceptibility testing of Mycobacterium tuberculosis complex. *J Clin Microbiol* 2009; 47(11):3630-3634.