

Short Communication

A Case Study of Rat Bite Fever Caused by *Streptobacillus moniliformis*

Yasue Hayakawa^{1***}, Jun Suzuki², Masahiro Suzuki³, Wataru Sugiura⁴, and Kiyofumi Ohkusu⁵

¹Department of Clinical Laboratory; ²Division of General Internal Medicine; and

⁴Department of Immunology and Infectious Diseases, Clinical Research Center, National Hospital Organization Nagoya Medical Center, Nagoya 460-0001;

³Laboratory and Bacteriology, Aichi Prefectural Institute of Public Health, Nagoya 462-8576; and

⁵Department of Microbiology, Tokyo Medical University, Tokyo 160-8402, Japan

SUMMARY: We report a case of rat bite fever, diagnosed based on positive cultures of *Streptobacillus moniliformis* from blood and synovial fluid. The patient was a 45-year-old man who presented with history of a rat bite and alcoholic liver cirrhosis. He had been bitten on his third finger by a rat, which was caught in a mousetrap installed in his house. Over the course of approximately 2 weeks after the bite, the patient developed fever, rash, and arthralgia. The patient was admitted to our hospital and treated with a combination of ampicillin-sulbactam, vancomycin (VAN), and minocycline (MIN) antibiotics. Initial culture findings from the Anaerobic/F resin blood culture were positive for gram-negative bacillus after overnight incubation. Thus, *S. moniliformis* infection was suspected, and administration of VAN and MIN was ceased. On hospital day 8, the treatment was switched to oral amoxicillin-clavulanic acid, and the patient was discharged from the hospital. Subsequently, the pathogen was also detected in synovial fluid and identified as *S. moniliformis* using 16S rRNA sequencing analysis.

Rat bite fever (RBF) is caused by *Streptobacillus moniliformis* or *Spirillum minus*, which are zoonotic pathogens transmitted by rodents. *S. moniliformis* is facultatively anaerobic, gram-negative rod bacteria found in the throat and nasopharynx of rodents. In a typical case of RBF, symptoms begin approximately 3 days to 3 weeks after sustaining a rodent bite; symptoms include sudden malaise, irregularly relapsing fever, headache, vomiting, and morbilliform rash. Subsequently, polyarthritides may appear in 50% to 70% of patients. The mortality rate of RBF from *S. moniliformis* infection is 7% to 10%, if patients are untreated (1,2).

In this case, a 45-year-old man was referred to the emergency room (ER) of our hospital by his family physician. Two weeks before visiting the ER, he was bitten on his right third finger by a rat, which was caught in a mousetrap installed in his house. Four days before visiting the ER, he developed fatigue and pain in his left knee and left wrist joints. The day prior to visiting the ER, he consulted his family physician and received piper-

racillin-tazobactam for the signs and symptoms of fever (38°C), rash, watery diarrhea, and pain in the finger, elbow, and ankle joints.

On admission, he had a blood pressure of 117/76 mmHg, pulse rate of 96 beats/min, temperature of 39°C, and respiratory rate of 31 beats/min. On physical examination, heat, tenderness, and swelling were observed in his left wrist, left elbow, and left knee joints. Other physical symptoms observed were the appearance of purpura on the lower legs, red papules and pustules on the forearms, and dusky-purple papules on the palms (Fig.1). The examination of his skin and extremities revealed the abnormalities as described above; otherwise, his exam was clear. At the time of his presentation to the ER, the associated bite wound was already healed. Clinical laboratory test results demonstrated signs of inflammation. The white blood cell count was 11,800/ μ L with 78% neutrophils and C-reactive protein was 16.1 mg/dL. According to the history of present illness and physical

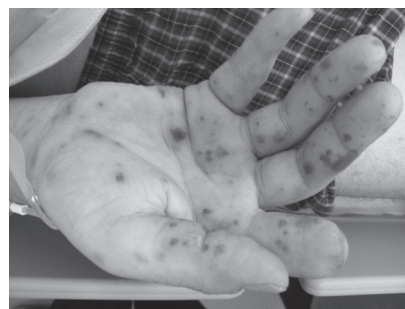

Fig. 1. Right hand of patient showing dusky-purple papules on the palm.

Received June 20, 2016. Accepted October 21, 2016.

J-STAGE Advance Publication December 22, 2016.

DOI:10.7883/yoken.JJID.2016.270

*Corresponding author: Mailing address: Department of Clinical Laboratory, National Hospital Organization Nagoya Medical Center, Nagoya 460-0001, Japan.

**Present address: Department of Clinical Laboratory, National Hospital Organization Nagara Medical Center, 1300-7 Nagara, Gifu-shi, Gifu 502-8558, Japan. Tel: +81-58-232-7755, Fax: +81-58-295-0077, E-mail: kensa02@nagara-lan.hosp.go.jp

examination, RBF, infectious endocarditis (IE), rickettsiosis, or cellulitis were suspected, and a blood culture test was performed at the time of admission. Blood specimens were inoculated into BACTEC Plus Aerobic/F resin and Anaerobic/F resin bottles (Nippon Becton Dickinson Diagnostic, Tokyo, Japan), and cultured using the BACTEC FX instrument (Nippon Becton Dickinson Diagnostic). Pending the results of the blood culture, treatment involving a combination of ampicillin-sulbactam (SAM) 12 g (3 g × 4), vancomycin (VAN) 2 g (1 g × 2), and minocycline (MIN) 200 mg (100 mg × 2) was initiated. SAM was selected to target suspected *S. moniliformis* or *S. minus*, and as empirical therapy for IE and cellulitis. VAN was chosen to treat possible methicillin resistant *Staphylococcus aureus* as the causative organism of IE or cellulitis. MIN was used to target suspected *S. moniliformis*, *S. minus*, and rickettsiosis.

On hospital day 2, left ventricular function was normal and neither valve regurgitation nor vegetation was observed by transthoracic echocardiography. Left knee arthrocentesis was performed, and 15 mL of synovial fluid was collected. The synovial fluid showed yellow turbidity, and inflammation was found as indicated by a total cell count of 2,700/μL (polymorphonuclear leucocytes/mononuclear leucocytes: 87/13); no crystals were observed. Gram staining of the synovial fluid did not yield a specific organism. The Anaerobic/F resin blood culture tested positive a day after the culture was initiated. The broth was extracted from the positive blood culture. Although we attempted to collect sediments to confirm microbials microscopically, we were unable to confirm presence of a meaningful organism by gram stain. This was partly because it was difficult to distinguish significant microbials from background debris. The positive blood culture broth was subcultured onto blood agar at 35°C in 8% CO₂ under moisturized conditions. The synovial fluid was cultured with brain-heart infusion broth supplemented with 10% Fetal Bovine Serum (FBS: HyClone).

On hospital day 5, the patient showed a trend towards apyrexia, and all eruptions became discolored and crusted over. After 48 hours of incubation, non-hemolytic, grayish white and flat colonies were obtained on blood agar plates. Thus, the blood agar smear preparations were found to be gram negative, and showed filamentous form. Treatment with VAN and MIN was discontinued

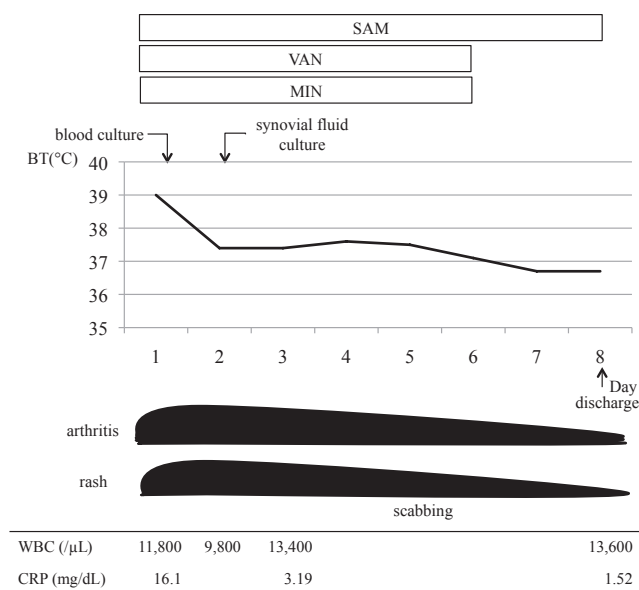


Fig. 2. Clinical course of this case.

because the gram-negative bacillus prompted suspicion of *S. moniliformis* or *S. minus*.

On hospital day 8, administration of SAM was discontinued and the patient was switched to administration of oral amoxicillin-clavulanic acid and discharged. Thereafter, no relapse of symptoms was reported (Fig.2).

To confirm strains genetically, the 16S rRNA gene from the colony on blood agar plates was analyzed. It showed 100% sequence similarity with *S. moniliformis* strain DSM 12112 (T). The synovial fluid culture isolate was also identified as *S. moniliformis* by 16S rRNA sequencing. Thus, concordant results were obtained from both the blood and synovial fluid.

An antibiotic susceptibility test was performed by broth microdilution method, using Dryplate 'Eiken' (Eiken Chemical Co., Ltd, Tokyo, Japan) as reported by Miyamoto et al., with minor modifications (3). After Mueller Hinton broth 'Eiken' (Eiken Chemical Co., Ltd) was added to FBS and accounted for 30% of the media, it was mixed with streptaemosupplement 'Eiken' (Eiken Chemical Co., Ltd) according to instructions of the manufacturer. Dryplate 'Eiken' DP34 was incubated for 48 h at 35°C in an 8% CO₂ humidified atmosphere. Results of antibiotic susceptibility tests are shown in Table 1.

Table1. Antimicrobial susceptibility of blood isolate (supplemented with 30% FBS)

Antimicrobial agent	MIC (μg/mL)	Antimicrobial agent	MIC (μg/mL)
Penicillin	< 0.06	Minocycline	< 0.12
Ampicillin	< 0.12	Clindamycin	< 0.12
Sulbactam/ampicillin	< 0.12/0.25	Clarithromycin	2
Cefazolin	< 0.5	Azithromycin	0.25
Cefotiam	< 0.06	Levofloxacin	< 1
Ceftriaxone	< 0.06	Gatifloxacin	< 0.12
Cefepime	0.25	Moxifloxacin	< 0.5
Cefaclor	< 0.5	Vancomycin	< 0.25
Cefcapenepivoxil	< 0.25	Sulfamethoxazole-trimethoprim	> 38/2
Imipenem/cilastatin	0.5		
Meropenem	< 0.06		

RBF is a common zoonotic infection in North America (1), but it is a rare disease in Japan. The optimal method for diagnosing RBF is detection of *S. moniliformis* through culture in suspected patients. However, *S. moniliformis* requires special conditions to culture; these conditions include (i) media enriched with 10–30% blood, serum, or ascetic fluid for growth and (ii) incubation in an atmosphere with 5% to 10% carbon dioxide (4). It is difficult to isolate *S. moniliformis* using the standard practices of laboratories.

In this case, we suspected *S. moniliformis* infection based on the clinical history of the patient and the positive result of the blood culture. As we could not confirm *S. moniliformis* cells by gram-staining of the blood culture specimen, we decided to clone splices on agar plates, then employ 16S rRNA typing to confirm *S. moniliformis*.

There are several reports of *S. moniliformis* RBF in Japan (3, 5–9), and all these cases were diagnosed by 16S rRNA sequencing analysis. Polymerase chain reaction in particular has been used in the detection of *S. moniliformis* DNA from the crust of a bite site (6). In future cases, we recommend attempting detection of *S. moniliformis* by 16S rRNA sequencing analysis from positive blood cultures in the early stages. Genetic diagnostic methods are becoming more important for diagnosis of microbial infections, especially for rare bacterial infections. In addition to the usefulness of genetic diagnostic methods, we also reported the importance of considering the clinical history of the patient to inform selection of

the appropriate diagnostic method to reach accurate diagnosis of the infection.

Conflict of interest Wataru Sugiura is an employee of GlaxoSmithKline since April 2015. The data in this manuscript were prepared before March 2015, when the author was the employee of National Hospital Organization Nagoya Medical Center.

REFERENCES

1. Sean PE. Rat bite fever and *Streptobacillus moniliformis*. Clin Microbiol Rev. 2007; 20: 13-22.
2. Gaastra W, Boot R, Ho HT, et al. Rat bite fever. Vet Microbiol. 2009; 133: 211-28.
3. Miyamoto J, Takahashi K, Satou T, et al. A case of rat-bite disease caused by *Streptobacillus moniliformis* from the blood culture. The J Hokkaido Assoc Med Technologists. 2011; 9: 12-6. Japanese.
4. Neil SL. Rat-bite fevers. In: David S, editor. Clinical Infection Disease. New York: Cambridge University Press; 2008. p. 1039-42.
5. Takayama Y, Fukui T. *Streptobacillus moniliformis* detected by blood culture. BYOTAI SEIRI. 2001; 35: 72-4. Japanese.
6. Nakagomi D, Deguchi N, Yagasaki A, et al. Rat-bite fever identified by polymerase chain reaction detection of *Streptobacillus moniliformis* DNA. J Dermatol. 2008; 35: 667-70.
7. Okamori S, Nakano M, Nakamura M, et al. A Japanese patient with a rare case of *Streptobacillus moniliformis* a bacteremia. J Infect Chemother. 2015; 21: 877-8.
8. Nei T, Sato A, Sonobe K, et al. *Streptobacillus moniliformis* bacteremia in a rheumatoid arthritis patient without a rat bite: a case report. BMC Res Notes. 2015; 8: 694.
9. Sato R, Kuriyama A, Nasu M. Rat-bite fever complicated by vertebral osteomyelitis: a case report. J Infect Chemother. 2016; 22: 574-6.