

Full Length Research Paper

# Antioxidant, hepatoprotective, and ameliorative effects of *Azadirachta indica* on *Eimeria papillata*-induced infection in mice

Mohamed A. Dkhil<sup>1,2\*</sup>, Ahmed E. Abdel Moneim<sup>2</sup> and Saleh Al-Quraishy<sup>1</sup>

<sup>1</sup>Department of Zoology, College of Science, King Saud University, Riyadh, Saudi Arabia.

<sup>2</sup>Department of Zoology and Entomology, Faculty of Science, Helwan University, Cairo, Egypt.

Accepted 30 January, 2012

*Azadirachta indica* (neem) is used in traditional medicine for its pharmacological properties. Here, we investigated the effects of neem on the outcome of coccidiosis caused by *Eimeria papillata* in mice. Coccidiosis was induced by infection of mice with  $10^3$  sporulated oocysts of *E. papillata*. The methanolic extract of neem (*Azadirachta indica*) leaves (500 mg/kg) was used *in vivo* for its antioxidant and hepatoprotective properties. Anticoccidial and anti-inflammatory activities of neem were determined through oocyst output and liver histopathology, respectively. The data showed that mice infected with *E. papillata* revealed an output of about  $6.5 \times 10^5$  oocysts per gram faeces on day 4 postinoculation (p.i.). This output is significantly decreased to about  $2.7 \times 10^5$  oocysts in neem-treated mice. Infection caused a marked liver injury as indicated by histopathological alterations as well as the significant increase in liver aspartate aminotransferase (AST), alanine aminotransferase, alkaline phosphatase (ALP) and bilirubin. Also, infection induced a significant increase in nitric oxide (NO) and malondialdehyde (MAD) and a significant decrease in glutathione (GSH). The methanolic extract of *A. indica* leaves showed a significant ( $P \leq 0.05$ ) hepatoprotective potential by improving the above mentioned parameters. Based on these results, it is concluded that *A. indica* leaves contain potent antioxidant compounds that could offer protection against hepatotoxicity as well as ameliorate preexisting liver damage and oxidative stress conditions.

**Key words:** Neem, liver, *Eimeria papillata*, oxidative stress, mice.

## INTRODUCTION

Coccidiosis is a parasitic disease affecting a variety of animals, especially mammals and birds. It is the most important infectious poultry disease, as far as economy is concerned. Coccidiosis is a global disease and costs on yearly basis, for prophylaxis, as well as therapy exceed two billion Euros (Dallouil and Lillehoj, 2006). The protozoan parasite of the genus *Eimeria* multiplies in the intestinal tract of poultry and produces tissue damage, resulting in reduced growth and increased susceptibility to pathogens (McDougald, 2003). The Eimerian parasites are characterized by fast reproduction and by infecting especially young animals (Gres et al., 2003; Pakandl,

2005). Infection begins with oral uptake of Eimerian oocysts, which release infectious sporozoites in the intestine. These, in turn, invade mainly epithelial cells of the intestine, in which they asexually multiply before oocysts are finally discharged with the feces. In this study, we used *E. papillata* which is a pathogenic species of the distal small intestine (Danforth et al., 1992).

In recent years, evidence has accumulated for a role of reactive oxygen metabolites as a mediator of tissue injury in several animal models (Özdemir et al., 2010; Fukui et al., 2010; Sato et al., 2011). Although, the exact mechanisms of free-radical generation are not yet completely understood, it is postulated that the antioxidant GSH depletion by the intestinal parasites may be a trigger for the production of reactive oxygen species (ROS) (Cam et al., 2008). Generation of ROS in the cytoplasm of cells may increase the mitochondrial

\*Corresponding author. E-mail: mohameddkhil@yahoo.com.  
Tel: 00966-14675754. Fax: 00966-14678514.

hydrogen peroxide production and lipid peroxidation of cell and mitochondrial membranes, resulting in loss of membrane integrity and finally cell necrosis or apoptosis (Valko et al., 2007).

Neem (*Azadirachta indica*) exhibits several activities useful for agricultural and medicinal applications known in India for thousands of years. The plant or its preparations are extensively reported to exert insecticidal, pesticidal, and agrochemical properties. Additionally, its constituents are applied in alternative and modern medicine, for example, for the treatment of diverse infectious, metabolic, or cancer diseases (Brahmachari, 2004; Ezz-Din et al., 2011).

Neem exhibit various multi-targeted biological activities, such as antibacterial (Thakurta et al., 2007), hypoglycemic (Murty et al., 1978), anti-ulcer (Pillai and Santhakumari, 1984), antimalarial (MacKinnon et al., 1997), anti-inflammatory (van der Nat et al., 1991), chemopreventive (Tepsuwan et al., 2002), and chemotherapeutic (Paliwal et al., 2005) properties. The present study has been designed to investigate the ameliorative effect of neem extract on the liver histopathology and oxidative stress-mediated by *E. papillata*.

## MATERIALS AND METHODS

### Animals

Swiss albino mice were bred under specified pathogen-free conditions and fed a standard diet and water *ad libitum*. The experiments were performed only with male mice at an age of 9-11 weeks and were approved by state authorities and followed Saudi Arabian rules for animal protection.

### Infection of mice

A self-healing strain of *E. papillata* was kindly provided by Prof. Mehlhorn (Heinrich Heine University, Duesseldorf, Germany). We maintained *E. papillata* in naturally infected mice, collected oocysts from feces, surface-sterilized the oocysts with sodium hypochlorite and washed at least four times with sterile saline before oral inoculation as described by Schito et al. (1996). These oocysts were used to inoculate mice by oral gavaging each mouse with  $10^3$  sporulated oocysts of *E. papillata* suspended in 100  $\mu$ l sterile saline. Once every 24 h, fresh faecal pellets were collected and weighed for each mouse and the bedding was changed to eliminate reinfection. Oocyst output was measured as previously described (Schito et al., 1996). Faecal pellets were suspended in 2.5% (wt/vol) potassium dichromate and diluted in saturated sodium chloride for oocyst flotation. Oocysts were counted in a McMaster chamber and expressed as number of oocysts per gram of wet faeces.

### Preparation of the neem extract

Fresh matured leaves of *Azadirachta indica* (neem) tree were collected in August from the garden in Obour City, Cairo, Egypt. The samples were authenticated by Dr. Jacob Thomas (Botany Department, College of Science, King Saud University, Saudi

Arabia) on the basis of taxonomic characters and by direct comparison with the herbarium specimens with a voucher number (KSU-10804) available at the herbarium of Botany (King Saud University, Saudi Arabia). *A. indica* (neem) leaf extract was prepared according to the method described by Manikandan et al. (2008) with some modification. Air-dried powder (100 g) of *A. indica* leaves were extracted by percolation at room temperature with 70% methanol and kept in refrigerator for 24 h. Leaves extract of *A. indica* was concentrated under reduced pressure (bath temperature 50°C) and dried in a vacuum evaporator. The residue was dissolved in distilled water, filtered and used in our experiment.

### Experimental design

Four groups of mice with 6 animals per group were investigated. The first group was inoculated only with sterile saline and served as the control group. The second group was treated by oral gavage with 100  $\mu$ l neem extract (500 mg/Kg) daily for 4 days. The dose and the route of injection were selected on the basis of the previous studies (Bhanwra et al., 2000; Ezz-Din et al., 2011). The third and fourth groups were infected with  $10^3$  sporulated oocysts of *E. papillata*. The fourth group was also treated once daily with neem extract for 4 days. Animals of all groups were cervically dislocated on day 4 postinoculation (p.i.), and blood samples were collected. Followed by standing for half an hour and then centrifuged at 500 g for 15 min at 4°C to separate serum and stored at -70°C.

### Histological analysis

Pieces of liver were freshly prepared, fixed in 10% neutral buffered formalin, and then embedded in paraffin. Sections were cut and then stained with hematoxylin and eosin. Histological damages were scored according to Jamshidzadeh et al. (2008) as follows: 0: absent; +: mild; ++: moderate; and +++: severe. Also, modified quantitative Ishak scoring system (Ishak et al., 1995) were used; scores of 1-3 were assigned to cases of minimal liver damage, scores of 4-8 to mild, scores of 9-12 to moderate and scores of 13-18 to severe cases.

### Biochemical analysis

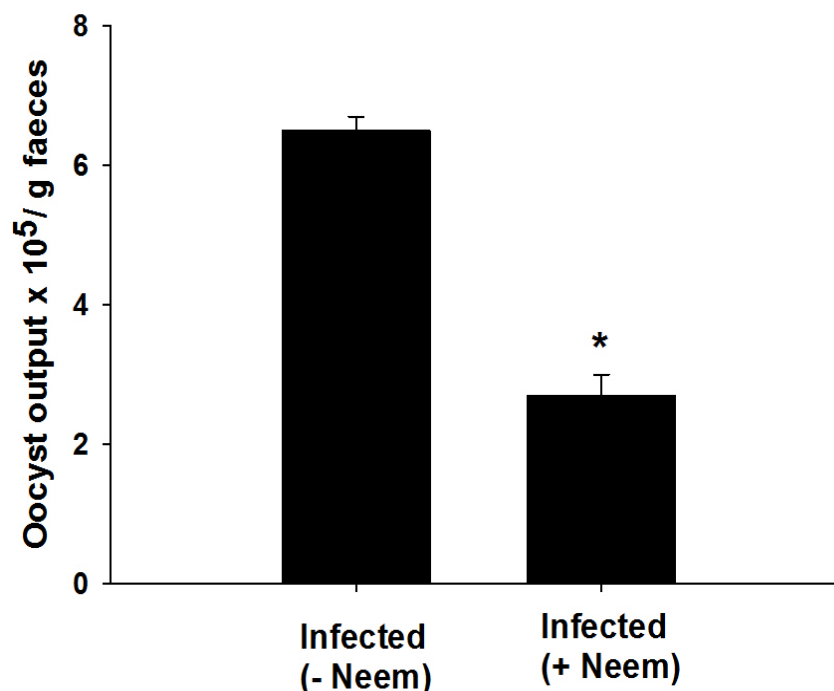
Parts of liver was weighed and homogenized immediately to give 50% (w/v) homogenate in ice-cold medium containing 50 mM Tris-HCl and 300 mM sucrose (Tsakiris et al., 2004). The homogenate was centrifuged at 500 g for 10 min at 4°C. The supernatant (10%) was used for the various biochemical determinations.

### Aminotransferases, alkaline phosphatase and bilirubin

Colorimetric determination of serum alanine aminotransferase (ALT) and aspartate aminotransferase (AST) was carried out. Colorimetric determination of ALT or AST was estimated by measuring the amount of pyruvate or oxaloacetate produced by forming 2, 4-dinitrophenylhydrazine. The color was measured at 546 nm according to Reitman and Frankel (1957). Alkaline phosphatase (ALP) was assayed in homogenate of liver using kits provided from Biodiagnostic Co. (Giza, Egypt). Total bilirubin (TB) of serum was also assayed according to the method of Schmidt and Eisenburg (1975).

### Glutathione

Glutathione (GSH) was determined chemically in liver homogenate



**Figure 1.** Mice oocyst output on day 4 p.i. with  $10^3$  sporulated *E. papillata* oocysts. Infected mice without neem treatment (- neem). Mice infected and treated with neem (+ neem). All values are means $\pm$ SD. \* $P < 0.001$  for - neem vs. + neem.

using Ellman's reagent (Ellman, 1959). The method is based on the reduction of Ellman's reagent (5,5' dithiobis (2-nitrobenzoic acid) with GSH to produce a yellow compound. The chromogen is directly proportional to GSH concentration, and its absorbance was measured at 405 nm.

#### Lipid peroxidation

Lipid peroxidation in liver homogenate were determined according to the method of Ohkawa et al. (1979) by using 1 ml of trichloroacetic acid 10% and 1 ml of thiobarbituric acid 0.67%, followed by heating in a boiling water bath for 30 min. Thiobarbituric acid reactive substances were determined by the absorbance at 535 nm and expressed as malondialdehyde (MDA) equivalents formed.

#### Nitric oxide

The assay of nitric oxide (NO) in liver homogenate was done according to the method of Berkels et al. (2004). In acid medium and in the presence of nitrite, the formed nitrous acid diazotises sulphanilamide, this is coupled with N-(1-naphthyl) ethylenediamine. The resulting azo dye has a bright reddish-purple color which was measured at 540 nm.

#### Statistical analysis

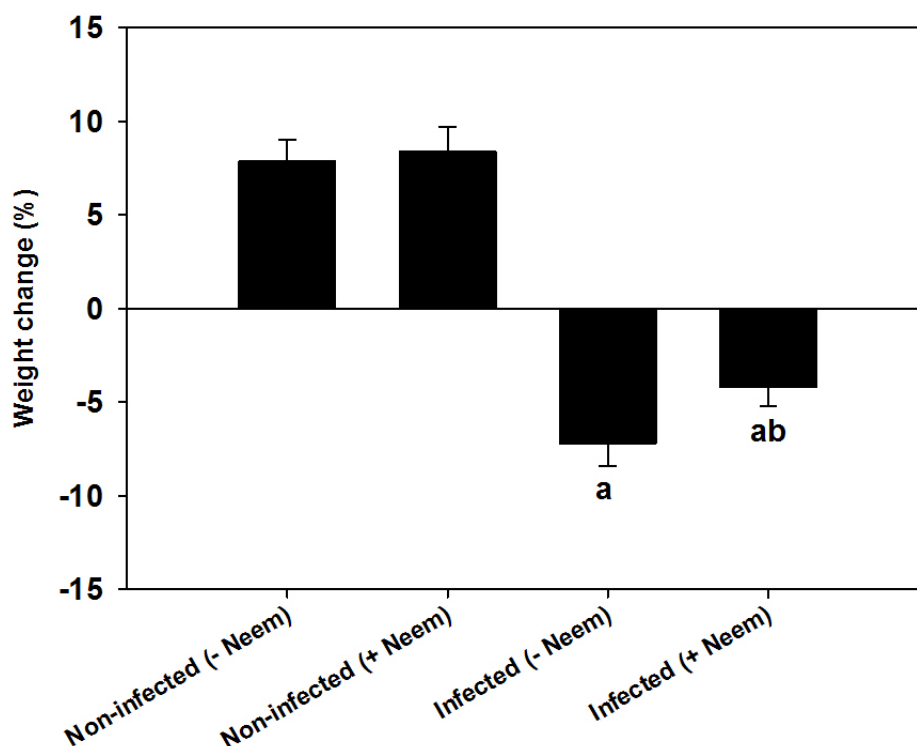
One-way ANOVA was carried out, and the statistical comparisons among the groups were performed with Duncan's test using a statistical package program (SPSS version 17.0). All p-values are

two-tailed and  $P < 0.05$  was considered as significant for all statistical analysis in this study.

## RESULTS

The effect of neem on the outcome of *E. papillata* infections was investigated. During the first 3 days of infection, there was no fecal output of oocysts. On day 4 postinoculation (p.i.), the output differed between neem-treated and non-treated mice. In the latter, the number of excreted oocysts reached approximately,  $6.5 \times 10^5$  per gram feces (Figure 1). However, the neem treatment significantly lowered the shedding of oocysts to about 60% on day 4 postinoculation (p.i.) (Figure 1). Concomitantly, the average weight of mice was significantly decreases ( $P < 0.01$ ). This weight loss is associated with watery mucoid diarrhea, and decreased uptake of water and food. Neem was able to lower this weight loss due to infection (Figure 2).

The liver has undergone some moderate pathological changes such as inflammatory cellular infiltrations, hepatocytic vacuolations, sinusoid dilatations, and edematous hepatocytes in comparison to livers of uninfected mice (Figure 3, Table 1). All these alterations are considered in the histological liver activity index according to Ishak, which can be categorized as 9-11 for the liver at day 4 postinoculation (p.i.) in comparison to the uninfected controls (Table 1). Histological analysis



**Figure 2.** Neem improved weight loss due to infection with *E. papillata*. Values are means  $\pm$  SD. Values are means  $\pm$  SD. a: Significant against non-infected (- Neem) group at  $P \leq 0.05$ , b: Significant against infected (- Neem) group at  $P \leq 0.05$ .

revealed that mice infected with sporulated oocysts of *E. papillata* suffered a moderate inflammatory injury in the liver (Figure 3, Table 1). This injury was diminished when mice were treated with neem (Figure 3, Table 1). Again, neem extract treatment significantly lowered the *E. papillata*-induced increase in ALT, AST, ALP and bilirubin, respectively (Table 2).

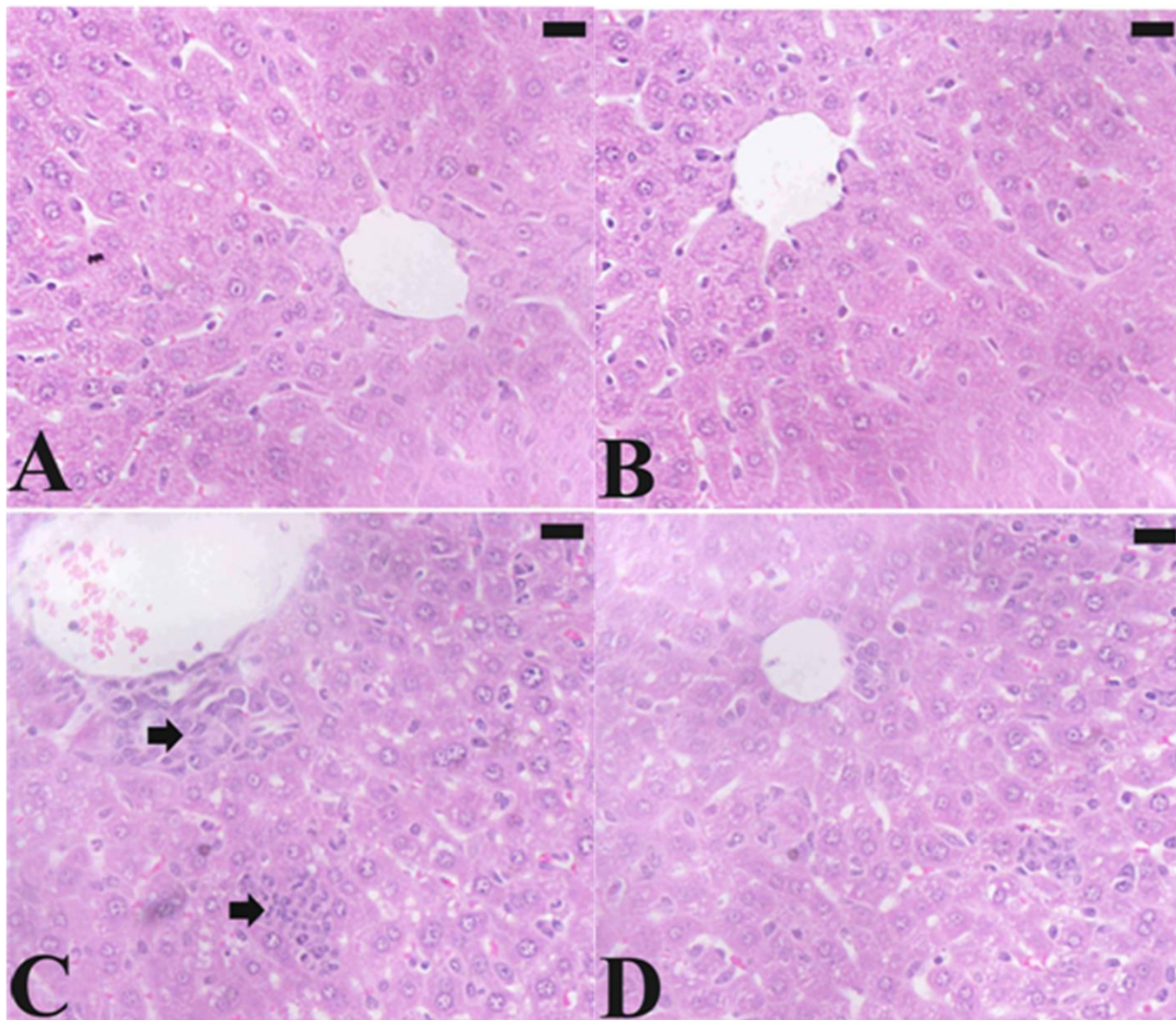
*E. papillata* infections also induced a highly significant increase in jejunal NO and MDA by approximately 78 and 43%, respectively (Table 3). Again, neem treatment significantly lowered the *E. papillata*-induced increase in both NO and MDA, respectively (Table 3). Finally, we also determined GSH which is the major component involved in the down regulation of substances formed during oxidative stress (Figure 4). Conspicuously, GSH was significantly down regulated by *E. papillata* infections, and these effects were largely prevented by neem treatment (Figure 4).

## DISCUSSION

The liver is the first-pass organ which is directly connected with the intestine by the portal vein. *E.*

*papillata* parasites infect the distal small intestine and normally do not invade the liver, though different lymphoid organs such as spleen and lymph nodes have been described to be infected by *E. coecicola* parasites (Renaux et al., 2001). Our data indicate that the inflammation of the intestine induced by *E. papillata* is also associated with an inflammatory response of the liver without being directly affected by the parasite (Dkhil et al., 2011). Moreover, our study shows that neem does not only target *Eimeria* parasites in hosts, but also exhibits anti-inflammatory activity thus protecting host tissues. Indeed, *E. papillata* infections cause an inflammatory response in the hepatic tissue of mice due to the abundance of leucocytes, in general, and lymphocytes, in particular as a prominent response of body tissues facing any injurious impacts. Also, the cytoplasmic vacuolation which is mainly a consequence of considerable disturbances in lipid inclusions and fat metabolism occurring under pathological cases were prominent in hepatocytes. Also, there was a significant increase activity of ALT, AST and ALP. Previous studies have shown increased activities of ALT, AST and ALP (San Martin-Nun̄ez et al., 1988) due to cholestasis in Rabbits suffering from hepatic coccidiosis (Joyner et al.,





**Figure 3.** Sections of mouse liver infected with *E. papillata* on day 4 p.i. (A) Non-infected jejunum with normal architecture. (B) Non-infected treated mouse liver with normal structure. (C) Infected liver with prominent inflammation (arrow) and hepatocytic vacuolation. (D) Infected treated mouse with less lesion. Sections are stained with hematoxylin and eosin. Bar=25  $\mu$ m.

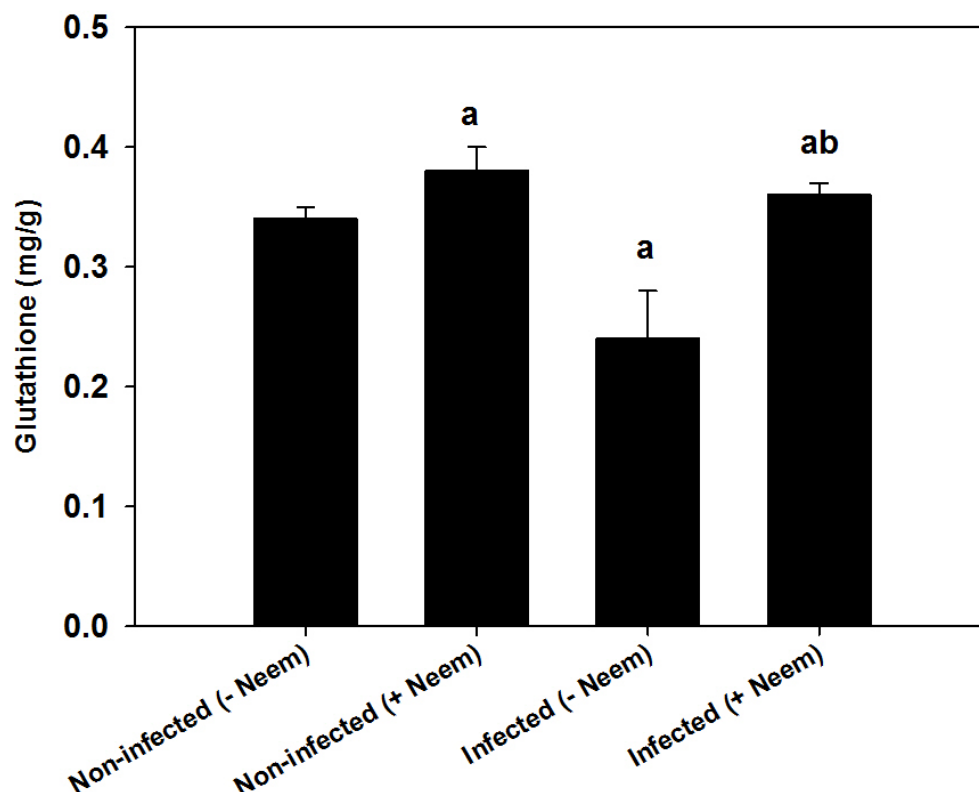
1983; Hein and Lammler 1978). Neem significantly diminishes liver injury and inflammation and therefore can be considered as a hepatoprotective agent.

The initial hope underlying the present experiment was to find a natural product with anticoccidial properties that could be used as a feed additive with minimal processing.

Neem exhibits anticoccidial activity, evidenced as a significant lowering in the output of *E. papillata* oocysts with the faeces of the infected mice. This diminished output reflects that neem impairs the development of parasites in the host before the relatively inert oocysts are formed and finally released. The fact that neem

possesses anticoccidial activity has also been reported in chicken coccidiosis (Toula et al., 2010).

Manikandan et al. (2008) reported that one of the major protective functions of neem is to decrease the oxidative damage in mice. Indeed, neem prevents the infection induced loss of GSH and increased production of NO and MDA. These components are normally lowered during oxidative damage induced by infection as it has been also described by Georgieva et al. (2006) who showed an increase in MDA levels of *E. tenella*-induced coccidiosis. In accordance, Balasenthil et al. (1999) have found that neem significantly decreased lipid peroxidation and



**Figure 4.** Effect of neem on the level of glutathione in liver of mice infected with *E. papillata*. Values are means  $\pm$  SD. Values are means  $\pm$  SD. a: Significant against non-infected (- Neem) group at  $P \leq 0.05$ , b: Significant against infected (- Neem) group at  $P \leq 0.05$ .

**Table 1.** Histopathological evaluations of the effects of neem extract on the induction of liver damage induced by *E. papillata*.

Group	Microscopic observation						
	Histologic al activity index <sup>a</sup>	Necrosis or apoptosis	Hemorrhage	Disorganize d sinusoids	Infiltration of lymphocytes	Hyperplasia of Kupffer cells	Hepatocyt ic swelling
Non-infected (- Neem)	2	+	0	0	0	0	0
Non-infected (+ Neem)	3	+	0	0	0	+	0
Infected (- Neem)	9-11	++	+	++	+++	++	++
Infected (+ Neem)	4-5	+	+	+	++	+	+

<sup>a</sup> Modified according to Ishak et al. (1995). Score: 1-3, minimal; 4-8, mild; 9-12, moderate; 13-18, severe. 0: absent; +: mild; ++, moderate; and +++: severe.

increased GSH.

Neem leaf consists of several valuable components and can be divided into two major classes: isoprenoids that include terpenoids containing limonoids, azadirone and its derivatives, c-secomeliacins, for example, azadirachtin and nonisoprenoids, which includes amino

acids, polysaccharides, sulphurous compounds, polyphenolics like flavonoids and their glycosides for example, quercetin, dihydrochalcone, coumarin and tannins, aliphatic compounds (Bandyopadhyay et al., 2002). A portion of these compounds present in the neem leaf can be extracted with water (Sarkar et al., 2007). The

**Table 2.** Effect of neem extract on serum ALT, AST, ALP and total bilirubin in mice infected with *E. papillata*.

Group	ALT (IU/ml)	AST (IU/ml)	ALP (IU/ml)	Bilirubin (mg/dl)
Non-infected (-Neem)	43 ± 2.3	39.5 ± 3.2	81 ± 4.3	3.4 ± 0.1
Non-infected (+Neem)	37.5 ± 2.8	37.5 ± 3.2	74.2 ± 3.2	3.2 ± 0.17
Infected (- Neem)	48 ± 2.5 <sup>a</sup>	48 ± 2.6 <sup>a</sup>	104 ± 3.6 <sup>a</sup>	4.8 ± 0.16 <sup>a</sup>
Infected (+ Neem)	44.2 ± 2.1 <sup>b</sup>	40.5 ± 3.4 <sup>b</sup>	73.3 ± 2.9 <sup>ab</sup>	3.2 ± 0.2 <sup>b</sup>

Values are means±SD (n=6). a: Significant change at  $P \leq 0.05$  with respect to non-infected mice, b: Significant change at  $P \leq 0.05$  with respect to infected mice.

**Table 3.** Effect of Neem extract on the level of nitric oxide and malondialdehyde in livers of infected mice with *E. papillata*.

Group	Nitric oxide (nmol/g)	Malondialdehyde (μmol/g)
Non-infected (- Neem)	0.60 ± 0.02	0.30 ± 0.01
Non-infected (+ Neem)	0.71 ± 0.02 <sup>a</sup>	0.29 ± 0.02 <sup>a</sup>
Infected (- Neem)	1.07 ± 0.02 <sup>a</sup>	0.43 ± 0.05 <sup>a</sup>
Infected (+ Neem)	0.67 ± 0.02 <sup>ab</sup>	0.36 ± 0.02 <sup>ab</sup>

Values are means ± SD. a: Significant against non-infected (- Neem) group at  $P \leq 0.05$ , b: Significant against infected (- Neem) group at  $P \leq 0.01$ .

antioxidative property of neem has been previously ascribed mainly to its major chemical component, Azadirachtin (Manikandan et al., 2008). Azadirachtin in neem leaves has been reported to produce anti- protozoan, anti-bacterial and antifungal effects (Morgan, 2009).

The present data indicate that neem exhibits a significant anticoccidial activity and, coincidentally, a significant improvement in histopathological picture of the liver as well as the antioxidant status and protect the host tissue from injuries induced by parasites.

## ACKNOWLEDGMENT

The authors extend their appreciation to the Deanship of Scientific Research at King Saud University for funding the work through the research group project.

## REFERENCES

- Balasenthil S, Arivazhagan S, Ramachandran CR, Ramachandran V, Nagini S (1999). Chemopreventive potential of neem (*Azadirachta indica*) on 7,12-dimethylbenz[a]anthracene (DMBA) induced hamster buccal pouch carcinogenesis. *J. Ethnopharmacol.*, 67: 189-195.
- Bandyopadhyay U, Biswas K, Chatterjee R, Bandyopadhyay D, Chattopadhyay I, Ganguly CK, Chakraborty T, Bhattacharya K, Banerjee RK (2002). Gastroprotective effect of Neem (*Azadirachta indica*) bark extract: possible involvement of H(+)-K(+)-ATPase inhibition and scavenging of hydroxyl radical. *Life Sci.*, 71: 2845-2865.
- Berkels R, Purol-Schnabel S, Roesen R (2004). Measurement of nitric oxide by reversion of nitrate/nitrite to NO. *J. Humana Press*, 279: 1-8.
- Bhanwra S, Singh J, Khosla P (2000). Effect of *Azadirachta indica* (Neem) leaf aqueous extract on paracetamol-induced liver damage in rats. *Ind. J. Physiol. Pharmacol.*, 44: 64-68.
- Brahmachari G (2004). Neem—an omnipotent plant: a retrospection. *Chem. Biochem.*, 5: 408-421.
- Cam Y, Atasever A, Eraslan G, Kibar M, Atalaym O, Beyazm L, Incim A, Liman BC (2008). *Eimeria stiedae*: experimental infection in rabbits and the effect of treatment with toltrazuril and ivermectin. *Exp. Parasitol.*, 119: 164-172.
- Dalloul RA, Lillehoj HS (2006). Poultry coccidiosis: recent advancements in control measures and vaccine development. *Expert Rev. Vaccines*, 5: 143-63.
- Danforth HD, Entzeroth R, Chobotar B (1992). Scanning and transmission electron microscopy of host cell pathology associated with penetration by *Eimeria papillata* sporozoites. *Parasitol. Res.*, 78: 570-573.
- Dkhil MA, Abdel-Baki AS, Wunderlich F, Sies H, Al-Quraishi S (2011). Anticoccidial and antiinflammatory activity of garlic in murine *Eimeria papillata* infections. *Vet. Parasitol.*, 175: 66-72.
- Ellman GL (1959). Tissue sulfhydryl groups. *Arch. Biochem. Biophys.*, 82: 70-77.
- Ezz-Din D, Gabry MS, Farrag AH, Abdel Moneim AE (2011). Physiological and histological impact of *Azadirachta indica* (neem) leaves extract in a rat model of cisplatin-induced hepato and nephrotoxicity. *J. Med. Plant Res.*, 5: 5499-5506.
- Fukui K, Takatsu H, Koike T, Urano S (2010). Hydrogen peroxide induces neurite degeneration: Prevention by tocotrienols. *Free Radic. Res.*, 45: 681-691.
- Georgieva N, Koinarski V, Gadjeva V (2006). Antioxidant status during the course of *Eimeria tenella* infection in broiler chickens. *Vet. J.*, 172: 488-492.
- Gres V, Voza T, Chabaud A, Landau I (2003). Coccidiosis of the wild rabbit (*Oryctolagus cuniculus*) in France. *Parasit.*, 10: 51-57.
- Hein B, Lammler G (1978). Alteration of enzyme activities in serum of *Eimeria stiedae* infected rabbits. *Parasitol. Res.*, 57: 199-211.
- Ishak K, Baptista A, Bianchi L, Callea F, De Groote J, Gudat F, Denk H, Desmet V, Korb G, MacSween RN (1995). Histological grading and staging of chronic hepatitis. *J. Hepatol.*, 22: 696-299.
- Jamshidzadeh A, Baghban M, Azarpira N, Bardbori AM, Niknahad H

- (2008). Effects of tomato extract on oxidative stress induced toxicity in different organs of rats. *Food Chem. Toxicol.*, 46: 3612-3615.
- Joyner LP, Catchpole J, Berrett S (1983). *Eimeria stiedae* in rabbits. The demonstration of responses to chemotherapy. *Res. Vet. Sci.*, 34: 64-67.
- MacKinnon S, Durst T, Arnason JT, Angerhofer C, Pezzuto J, Sanchez-Vindas PE, Poveda LJ, Gbeassor M (1997). Antimalarial activity of tropical Meliaceae extracts and gedunin derivatives. *J. Nat. Prod.*, 60: 336-341.
- Manikandan P, Letchoumy PV, Gopalakrishnan M, Nagini S (2008). Evaluation of *Azadirachta indica* leaf fractions for in vitro antioxidant potential and in vivo modulation of biomarkers of chemoprevention in the hamster buccal pouch carcinogenesis model. *Food Chem. Toxicol.*, 46: 2332-2343.
- McDougald LR (2003). Coccidiosis. In: Saif YM, Barnes HJ, Fadly AM, Glisson JR, McDougald LR, Swayne DE (Eds.), *Poultry Diseases*. Iowa State Press, Iowa, Pp. 947-991.
- Morgan ED (2009). *Azadirachtin*, a scientific gold mine. *Bioorg. Med. Chem.*, 17: 4096-4105.
- Murty KS, Rao DN, Rao DK, Murty LBG (1978). A preliminary study on hypoglycaemic and antihyperglycaemic effects of *Azadirachta indica*. *Ind. J. Pharmacol.*, 10: 247-250.
- Ohkawa H, Ohishi N, Yagi, K (1979). Assay for lipid peroxides in animal tissues by thiobarbituric acid reaction. *Anal. Biochem.*, 95: 351-358.
- Özdemir ÖM, Ergin H, Yenisey Ç, Türk NŞ, Şimşek NG (2010). Protective effects of clarithromycin in rats with hypoxia/reoxygenation-induced intestinal injury. *J. Pediatr. Surg.*, 45: 2169-2174.
- Pakandl M (2005). Selection of a precocious line of the rabbit coccidium *Eimeria flavescens* Marotel and Guilhon (1941) and characterization of its endogenous cycle. *Parasitol. Res.*, 97: 150-155.
- Paliwal S, Sundaram J, Mitragotri S (2005). Induction of cancerspecific cytotoxicity towards human prostate and skin cells using quercetin and ultrasound. *Braz. J. Cancer* 92: 499-502.
- Pillai NR, Santhakumari G (1984). Effects of nimbidin on acute and chronic gastro-duodenal ulcer models in experimental animals. *Planta, Med.*, 50:143-146.
- Reitman S, Frankel S (1957). A colorimetric method for the determination of serum glutamic oxalacetic and glutamic pyruvic transaminases. *Am. J. Clin. Pathol.*, 28: 56-63.
- Renaux S, Viard FD, Chanteloup NK, Vern Y, Kerboeuf D, Pakandl M, Coudret P (2001). Tissues and cells involved in the invasion of rabbit intestinal tract by sporozoites of *Eimeria coecicola*. *Parasitol. Res.*, 87: 98-106.
- Sarkar K, Bose A, Laskar S, Choudhuri SK, Dey S, Roychowdhury PK, Baral R (2007). Antibody response against neem leaf preparation recognizes carcinoembryonic antigen. *Int. Immunopharmacol.*, 7: 306-312.
- San Martin-Nunˆez BV, Ordonˆez-Escudero D, Alunda JM (1988). Preventive treatment of rabbit coccidiosis with a-difluoromethylornithine. *Vet. Parasitol.*, 30: 1-10.
- Sato Y, Itagaki S, Oikawa S, Ogura J, Kobayashi M, Hirano T, Sugawara M, Iseki K (2011). Protective effect of soy isoflavone genistein on ischemia-reperfusion in the rat small intestine. *Bio. Pharm. Bull.*, 34: 1448-1454.
- Schito ML, Barta JR, Chobotar B (1996). Comparison of four murine *Eimeria* species in immunocompetent and immunodeficient mice. *J. Parasitol.*, 82: 255-262.
- Schmidt M, Eisenburg J (1975). Serum bilirubin determination in newborn infants. A new micromethod for the determination of serum of plasma bilirubin in newborn infants. *Fortschritte Medizin* 93:1461-1466.
- Tepsuwan A, Kupradinun P, Kusamran WR (2002). Chemopreventive potential of neem flowers on carcinogen-induced rat mammary and liver carcinogenesis. *Asian Pac. J. Cancer, Prev.*, 3: 231-238.
- Thakurta P, Bhowmik P, Mukherjee S, Hajra TK, Patra A, Bag PK (2007). Antibacterial, antisecretory and antihemorrhagic activity of *Azadirachta indica* used to treat cholera and diarrhea in India. *J. Ethnopharmacol.*, 111: 607-612.
- Toulah FH, Ismeel HA, Khan S (2010). Effect of treatment with Neem (*Azadirachta indica*) compared with Baycox drug on the caecum of chicken experimentally infected with *Eimeria tenella*. *J. Egypt. Soc. Parasitol.*, 40: 93-106.
- Tsakiris S, Schulpis KH, Marinou K, Behrakis P (2004). Protective effect of L-cysteine and glutathione on the modulated suckling rat brain Na<sup>+</sup>, K<sup>+</sup>, -ATPase and Mg<sup>2+</sup> -ATPase activities induced by the in vitro galactosaemia. *Pharm. Res.*, 49: 475-479.
- Valko M, Leibfritz D, Moncol J, Cronin MT, Mazur M, Telser J (2007). Free radicals and antioxidants in normal physiological functions and human disease. *Int. J. Biochem. Cell Biol.*, 39: 44-84.
- van der Nat JM, van der Sluis WG, Hart LA, Van Dijk H, de Silva KT, Labadie RP (1991). Activity-guided isolation and identification of *Azadirachta indica* bark extract constituents which specifically inhibit chemiluminescence production by activated human polymorphonuclear leukocytes. *Planta Med.*, 57: 65-68.