

# Development of a PCR assay to detect cyprinid herpesvirus 1 in koi and common carp

Pedro H. O. Viadanna<sup>1,5</sup>, Tim Miller-Morgan<sup>2</sup>, Trace Peterson<sup>2</sup>, Keith Way<sup>3</sup>,  
David M. Stone<sup>3</sup>, Gary D. Marty<sup>4</sup>, Fabiana Pilarski<sup>5</sup>, Ronald P. Hedrick<sup>6</sup>,  
Thomas B. Waltzek<sup>1,\*</sup>

<sup>1</sup>Department of Infectious Diseases and Pathology, College of Veterinary Medicine, University of Florida, Gainesville, FL 32608, USA

<sup>2</sup>Department of Biomedical Sciences, College of Veterinary Medicine, Oregon State University, Corvallis, OR 97331-3804, USA

<sup>3</sup>Centre for Environment, Fisheries and Aquaculture Science, Barrack Road, The Nothe, Weymouth, Dorset DT4 8UB, UK

<sup>4</sup>Animal Health Centre, Ministry of Agriculture, 1767 Angus Campbell Rd., Abbotsford, British Columbia V3G 2M3, Canada

<sup>5</sup>Aquaculture Center, CAUNESP, Pathology of Aquatic Organism Laboratory, Rod. Paulo Donato Castellane s/n, Jaboticabal, SP, CEP: 14.884-900, Brazil

<sup>6</sup>Department of Medicine and Epidemiology, School of Veterinary Medicine, University of California, Davis, CA 95616, USA

**ABSTRACT:** Cyprinid herpesvirus 1 (CyHV1) infects all scaled and color varieties of common carp *Cyprinus carpio*, including koi. While it is most often associated with unsightly growths known as 'carp pox,' the underlying lesion (epidermal hyperplasia) can arise from a variety of disease processes. CyHV1-induced epidermal hyperplasia may occur transiently in response to water temperature, and thus histopathology cannot be used in isolation to assess CyHV1 infection status. To address this problem, here we describe a PCR assay targeted to the putative thymidine kinase gene of CyHV1. The PCR assay generates a 141 bp amplicon and reliably detects down to 10 copies of control plasmid DNA sequence (analytic sensitivity). The PCR does not cross-detect genomic DNA from cyprinid herpesvirus 2 and 3 (analytic specificity). The CyHV1 PCR effectively detected viral DNA in koi and common carp sampled from various locations in the UK, USA, Brazil, and Japan. Viral DNA was detected in both normal appearing and grossly affected epidermal tissues from koi experiencing natural epizootics. The new CyHV1 PCR provides an additional approach to histopathology for the rapid detection of CyHV1. Analysis of the thymidine kinase gene sequences determined for 7 PCR-positive carp originating from disparate geographical regions identified 3 sequence types, with 1 type occurring in both koi and common carp.

**KEY WORDS:** *Cyprinus carpio* · Specificity · Sensitivity

Resale or republication not permitted without written consent of the publisher

## INTRODUCTION

Cyprinid herpesvirus 1 (CyHV1) infects both common carp and koi carp *Cyprinus carpio* and is the most geographically widespread of the 3 alloherpesviruses that infect cyprinid fishes (Wolf 1988, Waltzek et al. 2009a). While cyprinid herpesvirus 2 and 3 (CyHV2 and CyHV3, respectively) are associated with lethal

systemic diseases in all ages of goldfish *Carassius auratus* and carp, respectively, CyHV1 is rarely the cause of mortality in fish >2 mo old (T. Sano et al. 1991). CyHV1 is unique among the cypriniviruses in that it induces seasonal episodes of epidermal hyperplasia that results in unsightly mucoid to waxy growths of variable severity known as 'carp pox' that have been recognized since the middle ages among

common carp cultured in Europe (Hofer 1904, McAllister et al. 1985, Sano et al. 1985a, Lu et al. 2009).

A viral etiology for carp pox was first hypothesized in the early 1900s (Löwenthal 1907). Herpes-like virus particles were associated with the characteristic epidermal growths using electron microscopy in the mid-1960s (Schubert 1964, 1966). Despite numerous past and more recent attempts, the virus has only been isolated with cell lines derived from fathead minnow *Pimephales promelas* (Sano et al. 1985b) and koi (Dixon 2008). The virus, named *Herpesvirus cyprini*, was the subject of a series of experimental studies from 1985 to 1995. These studies revealed 2 phases to CyHV1 infections: (1) a lethal systemic disease in carp <2 mo old and (2) a recurring proliferative skin disease linked to seasonal periods of lower water temperature among survivors or fish exposed at older ages (T. Sano et al. 1985a, 1991).

Being propagated widely, common carp is the species in which CyHV1 disease is most commonly reported (Wolf 1988, Chistiakov & Voronova 2009). Proliferative cutaneous lesions similar to those caused by CyHV1 in carp occur in other European cyprinids such as the golden ide *Leuciscus idus* (McAllister et al. 1985, Steinhagen et al. 1992) as well as salmonid, anguillid, osmerid, esocid, silurid, percid, pleuronectid, acipenserid, centrarchid, and various aquarium fishes (Nigrelli 1952, Lucky 1970, McAllister 1993, Hoole et al. 2001, Dixon 2008, Waltzek et al. 2009a, Freitas et al. 2016). However, the role of viruses in the skin lesions observed in these species is not yet known.

CyHV1 disease occurs in Europe (Schäperclaus 1969, Dixon 2008, Pääk et al. 2011), North America (Hedrick et al. 1990, Waltzek et al. 2009a), and Asia (T. Sano et al. 1985b, Timur 1991, Yardimci et al. 2009) in common carp varieties that have been dispersed widely as part of international food and ornamental aquaculture industries. Disease caused by CyHV1 occurs seasonally as water temperatures decline below 20°C. The disease manifests as foci of epidermal hyperplasia that expand progressively into pronounced lesions that can cover up to 60 % of the body surface and can involve up to 95 % of fish in highly affected populations (Lu et al. 2009). As water temperatures rise, the skin growths spontaneously regress as the likely result of an elevated cell-mediated immune response hypothesized from leukocytes being abundant in resolving lesions (Morita & Sano 1990, N. Sano et al. 1993b). Young fish that survive initial infections with CyHV1 are presumed to be life-long virus carriers as evidenced by (1) seasonal recurrences of lesions in the same fish and (2) persist-

ence of viral DNA in skin growths during disease episodes and in numerous tissues of healthy appearing fish following experimental or natural exposures to the virus (N. Sano et al. 1992, 1993a).

CyHV1-induced skin lesions are characterized by severe epidermal hyperplasia (up to 20 times thicker than the normal epidermis) that can become organized into large papillomatous folds described as papillomatous hyperplasia (Hines et al. 1974, Sonstegard & Sonstegard 1978, T. Sano et al. 1985a, Wolf 1988, Hedrick et al. 1990, Calle et al. 1999, Lu et al. 2009). Affected epidermal cells may display a wide range of cytologic changes such as cytomegaly, anisokaryosis, karyomegaly, multinucleation, marginated chromatin, prominent nucleoli, mitotic figures, and Cowdry type A inclusions. Other changes to the normal epidermal stratification include alterations in the number and orientation of mucous cells, alarm cells, and lymphocytic infiltration. In severe cases, the hyperplastic epidermis is nourished by a network of dermal pegs composed of proliferating connective tissue and associated vasculature that together can resemble a true papilloma. Moribund fry suffering from experimentally induced systemic disease display extensive necrosis of the liver, kidney, and intestinal lamina propria (T. Sano et al. 1991).

Diagnosis of the chronic proliferative disease among varieties of common carp begins with an appropriate clinical case history and gross findings supported by characteristic histopathologic changes. Given that epidermal hyperplasia is a common sequela in fish suffering from non-viral diseases, the presence of CyHV1 antigen or genomic DNA in formalin-fixed, paraffin-embedded tissue sections by indirect immunofluorescent or *in situ* hybridization assays, respectively, has been used to confirm the involvement of CyHV1 (N. Sano et al. 1992, 1993a,b). In cases where CyHV1 isolation is unsuccessful, diagnosis can be supported by the observation of herpesvirus particles by transmission electron microscopy (Hedrick et al. 1990, Calle et al. 1999). Most recently, a DNA array-based multiplex assay has been reported for the multiplex detection of all 3 cypriniviruses (CyHV1–3) as well as 3 *Flavobacterium* species in a single test (Lievens et al. 2011). Due to the difficulties reported in isolating CyHV1 in cell culture and accessing the DNA array-based test platform, here we developed a conventional PCR assay targeted to a region of the CyHV1 thymidine kinase gene. The diagnostic potential of the assay was assessed using CyHV1 isolates and tissues of naturally infected koi or common carp from locations in the USA, Europe, Japan, and Brazil.

## MATERIALS AND METHODS

### Fish, viruses, and sampling protocols

Nineteen koi from the Oregon Koi Gardens (Beaverton, Oregon, USA) undergoing a naturally occurring CyHV1 disease outbreak were sampled in July 2009. The fish were maintained in an 18900 l pond receiving well water at 15.5°C. To collect samples, fish were anesthetized with 100 ppm of buffered MS-222 (Margaritov 1982) and blotted dry with a clean towel prior to sampling. From the 10 fish that had gross lesions consistent with carp pox, a superficial biopsy of grossly abnormal skin in a lesion was excised with a sterile scalpel blade and placed into RNA later® (Ambion) for PCR analysis, and a comparable biopsy from a separate lesion was placed into 10% neutral buffered formalin for histopathology. From all 19 fish, a biopsy of grossly normal superficial skin just posterior to the left pectoral fin was placed in RNAlater®. Between July and the beginning of November 2009, 2 fish died and were discarded without being tested. At the beginning of November, the remaining fish were moved indoors and placed in a 3800 l recirculating system with the water heated to 24°C. After 6 wk indoors, the 17 koi were sampled again; however, because all skin lesions had resolved, biopsies were again collected behind the pectoral fin.

The origins of the common carp and koi skin samples examined from fish exhibiting gross proliferative lesions typical of CyHV1 disease are summarized in Table 1. Skin samples were obtained from Oregon Koi Gardens as described above (sample CyHV1O), 2 koi dealers in northern California (samples CyHV1C1 and CyHV1C2), 1 dealer in southern California (sample CyHV1C3), and from an ornamental carp producer in southeast Brazil (sample

CyHV1Br). The CyHV1 (CyHV1J) and CyHV2 isolates used in this study were kindly provided by Professor H. Fukuda (Tokyo University of Marine Science and Technology, Tokyo, Japan) and originated from Japanese koi and goldfish, respectively (Davison et al. 2013). The CyHV1UK isolate was isolated in KF-1 cells inoculated with material from a common carp sampled from a pond in the UK that also contained koi, goldfish, and rudd *Scardinius erythrophthalmus* (Hedrick et al. 2000, Dixon 2008). The CyHV3 koi isolate KHV-U used in this study was that described previously by Aoki et al. (2007). All isolates were propagated and purified as described previously (Waltzek et al. 2005).

### DNA extraction, sequence alignments, and primer design

DNA was extracted from carp skin samples and purified virus (CyHV1–3) using a DNeasy kit (Qia-gen) as described previously (Waltzek et al. 2005). PCR primers were designed to a putative thymidine kinase (TK) gene and flanking region (ORF 55) determined for CyHV1J (GenBank accession YP\_007003721). The primers CyHV1fullTKF+ (5'-AAG AGC TGC GGG TGA CTA ACA-3') and CyHV1 fullTKR+ (5'-CCA CAA AAC TGG GAG TAT GTG-3') were designed to amplify the complete TK gene sequence from the CyHV1UK isolate and infected carp skin samples from Oregon, California, and Brazil. An aliquot (10 µl) of the PCR was electrophoresed in a 1.0% agarose gel containing ethidium bromide (EtBr). PCR products were cloned into pCR®4-TOPO® (Invitrogen) and transformed into competent *Escherichia coli* using a TOPO TA Cloning® Kit (Invitrogen) according to the manufacturer's protocols.

Table 1. Summary of the samples used in the development and validation of the cyprinid herpesvirus 1 (CyHV1) conventional PCR assay targeting the putative thymidine kinase gene

Sample name	Sample type	Host	Origin	GenBank accession number	Reference
CyHV1C1	Skin	Koi	Northern California, USA	KU672601	This study
CyHV1C2	Skin	Koi	Northern California, USA	KT587201	This study
CyHV1C3	Skin	Koi	Southern California, USA	KT587202	This study
CyHV1O	Skin	Koi	Oregon, USA	KU672600	This study
CyHV1Br	Skin	Koi	Brazil	KT587200	This study
CyHV1UK	Isolate	Common carp	UK	KU672599	This study
CyHV1J	Isolate	Koi	Japan	YP_007003721	Davison et al. (2013)
CyHV2	Isolate	Goldfish	Japan	YP_007003876	Davison et al. (2013)
CyHV3	Isolate	Koi	USA	YP_001096090	Aoki et al. (2007)

Plasmid DNA was sequenced using M13 forward and reverse primers using an ABI 377 automated sequencer (Applied Biosystems). The CyHV1TK gene clone sequences were aligned against the homologous sequences for a Japanese CyHV2 isolate (YP\_007003876) and a US CyHV3 isolate (YP\_001096090). Alignments were carried out using Clustal X2.1 (Thompson et al. 1997), and text was formatted using BioEdit V7.2.5 (Hall 1999). CyHV1-specific diagnostic primers CyHV1F1 (5'-GTT CTA AAG TTG ATA CCC C-3') and CyHV1R1 (5'-TGT AGG CTT CTG TTC CAC C-3') were designed using Primer 3 (Untergasser et al. 2012) and manually edited in BioEdit (Hall 1999) to ensure the primers targeted regions of sequence dissimilarity between the 3 cypriniviruses (Fig. 1).

### Diagnostic PCR optimization

The diagnostic PCR conditions were optimized using 100 copies of CyHV1 pDNA linearized with

*NotI* and purified using a QIAquick PCR Purification Kit (Qiagen). The pDNA concentration was quantified using a Qubit 3.0 Fluorometer®. The PCR was tested in duplicate using 1.0, 1.5, 2.0 U Platinum *Taq* DNA polymerase (Invitrogen) and 0, 10, or 20 mM tetramethyl ammonium chloride (TMAC) at annealing temperatures of 51, 53, 55, 57, 59, or 61°C for 30, 32, 34, 36, 38, or 40 PCR thermal cycles. Aliquots (10 µl) of each PCR were electrophoresed in a 1.0% agarose gel containing EtBr, and amplified DNA was visualized on a UV transilluminator.

The detection limit of the optimized diagnostic PCR assay was determined using 10-fold serial dilutions of CyHV1 pDNA between 10<sup>8</sup> and 1 DNA copy, both with and without the inclusion of 100 ng genomic DNA extracted from CyHV1-negative koi. The analytic specificity of the assay for CyHV1, but not CyHV2 or CyHV3, was also examined using 100 ng DNA extracted from tissues of infected fish (Waltzek et al. 2005).



Fig. 1. Nucleotide sequence alignment of the complete thymidine kinase genes of cyprinid herpesvirus 3 (CyHV3), CyHV2, and CyHV1. Consensus sequences are presented for the 3 CyHV1 sequence types: (1) CyHV1O from Oregon, USA; (2) CyHV1C1/C2/Br from northern California, USA, and Brazil; and (3) CyHV1C3/UK/J from southern California, the UK, and Japan. CyHV1O serves as the alignment reference with the same nucleotide as the reference indicated by dots (.) and gaps indicated by dashes (-). Yellow highlighted regions indicate the CyHV1 diagnostic PCR primer binding sites



## RESULTS

### Genetic variability of CyHV1 samples

From the CyHV1 samples examined from different locations (Table 1), the CyHV1TKfull+ PCR amplified a 719 bp product containing the 444 bp CyHV1 TK gene sequence. The TK gene nucleotide sequences of the CyHV1 samples from southern California, UK, and Japan (CyHV1C3/UK/J) were identical and displayed 97 % sequence identity to the 2 northern California samples (CyHV1C1/C2) which were identical to each other and the sample from Brazil (CyHV1Br) (Fig. 1). The Oregon CyHV1 sample (CyHV1O) shared 99 and 98 % identity with the CyHV1C1/C2/Br and CyHV1C3/UK/J samples, respectively. The CyHV1 thymidine kinase gene sequences have been deposited in GenBank (Table 1).

### Diagnostic PCR optimization

The diagnostic PCR had an analytic sensitivity for plasmid DNA (pDNA) of 10 copies either in the presence or absence of 100 ng of koi genomic DNA (Fig. 2). Optimal 141 bp amplicon yields were obtained using 1× PCR buffer (Invitrogen), 2.0 mM MgCl<sub>2</sub>, 0.2 mM dNTPs, 0.5 mM of each primer (CyHV1F and CyHV1R3), 10 mM TMAC, and 1.5 U Platinum *Taq* polymerase (Invitrogen). Optimal thermal cycling conditions were 94°C for 5 min; 40 cycles of 94°C for 30 s, 59°C for 15 s, and 72°C for 15 s; and 72°C for 5 min. The test did not amplify DNA from either CyHV2 or CyHV3 (Fig. 2).

### Examination of koi tissues for lesions and CyHV1

When koi from Oregon Koi Gardens were sampled in July 2009, 10 of the 19 fish displayed raised opaque plaques consistent with carp pox. Gross disease signs ranged in severity from a few discrete growths to coalescing growths which covered approximately 50 % of the body surface. DNA extracted from tissue biopsies within lesions of the 10 affected fish and normal skin of all 19 fish tested positive using the CyHV1 diagnostic PCR. Proliferative skin lesions remained evident on the affected fish until

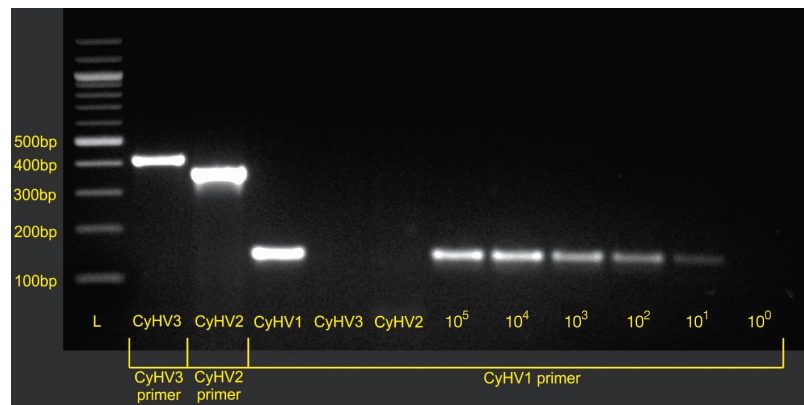


Fig. 2. Specific detection of CyHV1 (analytic specificity) with the thymidine kinase (TK) PCR among the closely related cypriniviruses CyHV3 and CyHV2. Lane 1 shows the molecular weight ladder with the sizes of the first 5 bands from bottom to top: 100, 200, 300, 400, and 500 bp. Lanes 2–4: CyHV3 (Bercovier et al. 2005), CyHV2 (Waltzek et al. 2009b), and CyHV1 (this study) samples tested against assays specific to the respective viruses. The expected 409 bp (Lane 2, CyHV3), 366 bp (Lane 3, CyHV2), and 141 bp (Lane 4, CyHV1) amplicons were observed. Lanes 5 and 6 (CyHV3- and CyHV2-infected tissue samples) run against the CyHV1 TK PCR assay. Lanes 7–12 illustrate the limits of the analytic sensitivity of the TK CyHV1 PCR. A linear plasmid target sequence for the CyHV1 PCR was diluted to provide target copy numbers of  $1 \times 10^5$  to  $1 \times 10^0$  per reaction for Lanes 7–12, respectively

November 2009. However, these lesions resolved within 2 to 3 wk after moving the fish indoors at an elevated water temperature. For all 17 koi remaining alive in December 2009, DNA extracted from skin biopsies tested negative by PCR.

Of the skin lesion tissue biopsies taken in July 2009, histopathology identified epidermis in all samples and also scales and/or dermal connective tissues in 5 samples. All biopsies had acanthosis (epidermal hyperplasia) consistent with 'papillomatous growths' (Figs. 3 & 4A). Several skin lesions had abundant lymphocytic infiltrates accompanied by other degen-



Fig. 3. Gross photo illustrating lesions associated with CyHV1 disease in *Cyprinus carpio*. Caudal peduncle and fin displaying 3 discrete, raised, smooth gray 'waxy' nodular growths (arrows) characteristic of CyHV1 disease

erative changes including spongiosis and single-cell necrosis (Fig. 4B–D). Some epidermal cells had multiple nuclei (Fig. 5A) or hydropic degeneration (Fig. 5B). Other epidermal changes included anisokaryosis and occasional mitotic figures, and 4 sections had low to moderate numbers of monogenean parasites (probably a *Gyrodactylus* sp.).

## DISCUSSION

A PCR was optimized and partially validated for its ability to specifically detect CyHV1 among naturally

infected koi and common carp. The diagnostic CyHV1 PCR complements the use of histopathology by differentiating CyHV1-induced epidermal hyperplasia from similar skin lesions in common carp varieties that can result from other infectious (e.g. parasites) or non-infectious (e.g. neoplasia) causes. Further studies are needed to determine whether the PCR assay is effective in diagnosing CyHV1 infections in fish (usually fry) suffering from the acute systemic form of CyHV1 disease when virus concentrations would be high, as well as in asymptomatic carriers with low-level persistent or latent infections (N. Sano et al. 1991, 1992, 1993a).

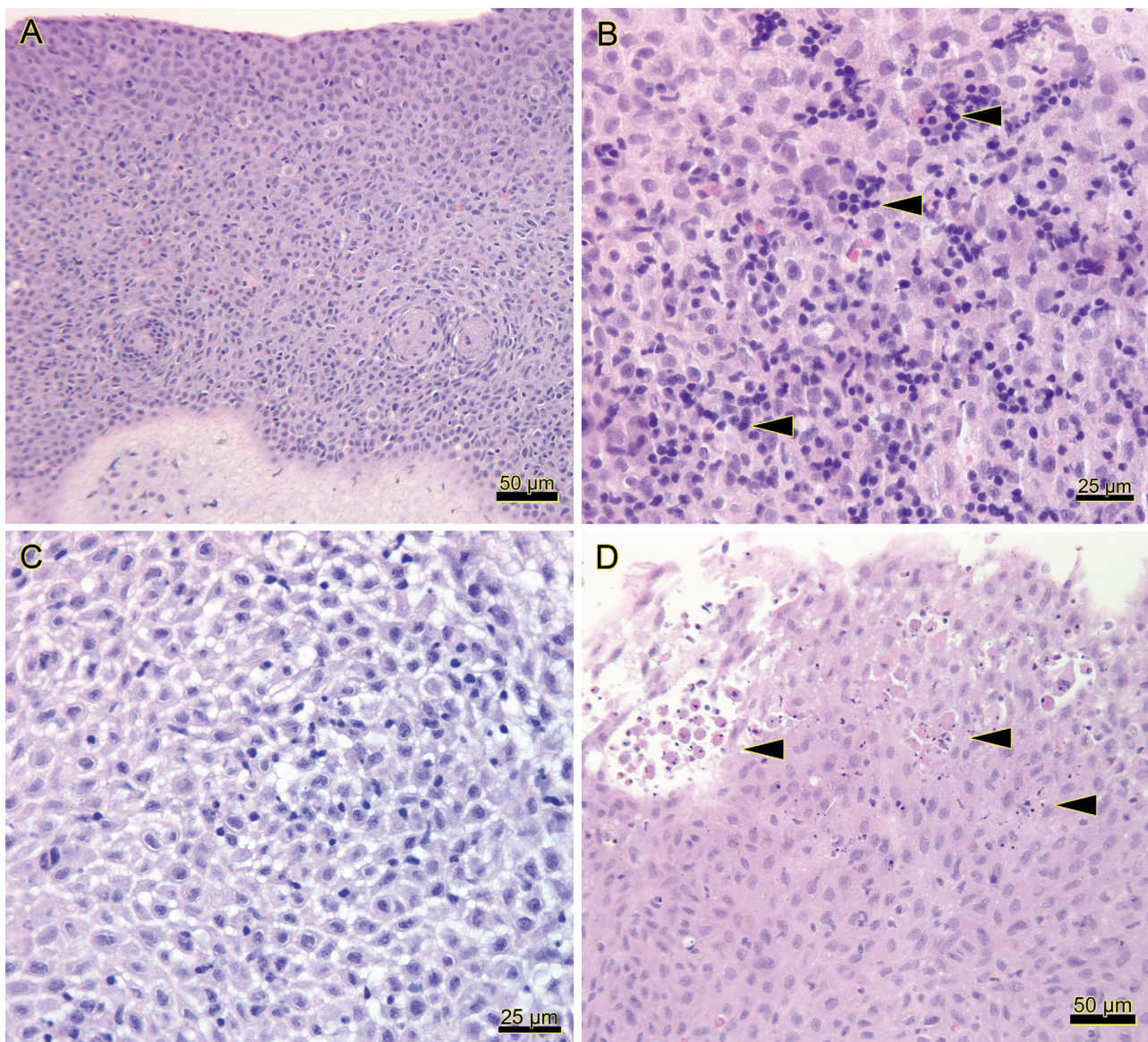


Fig. 4. Lesions associated with CyHV1 disease in *Cyprinus carpio*. (A) Severe epidermal hyperplasia in which the epidermis varies from 22 to 35 cells thick (H&E). (B) Epidermis infiltrated by moderate numbers of lymphocytes (arrowheads), some of which are in small discrete clusters, and fewer intermingled eosinophilic granular cells (H&E). (C,D) Degenerative changes within the epidermis include spongiosis (C) and necrosis (D) of individual epidermal cells (arrowheads) (H&E)



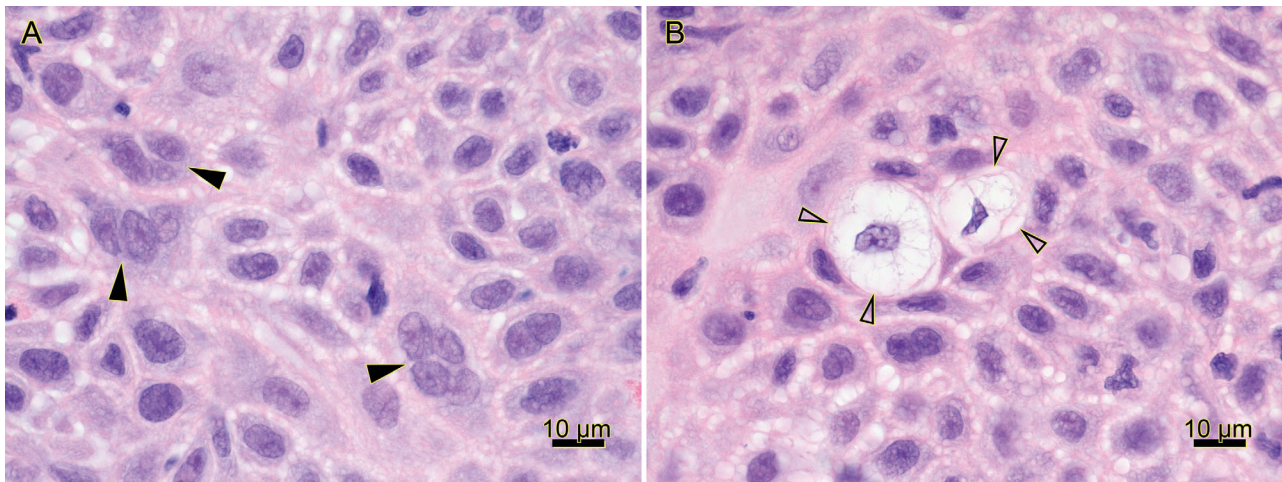


Fig. 5. Photomicrographs of infected skin of *Cyprinus carpio* sectioned roughly parallel to the basement membrane. H&E stain. (A) A few epidermal cells in the stratum spinosum have multiple nuclei (arrowheads). (B) Two epidermal cells in the stratum spinosum have vacuolated cytoplasm (arrowheads) characteristic of hydropic degeneration (H&E)

Our findings are consistent with previous work in that the CyHV1 genome could be detected in normal appearing and hyperplastic skin when proliferative skin lesions were observed grossly; however, upon raising the temperature and regression of the proliferative cutaneous lesions, the CyHV1 genome could not be detected in the skin (N. Sano et al. 1993a,b). N. Sano et al. (1993a) found the CyHV1 genome in cranial nerve ganglia and spinal nerves following the regression of proliferative lesions and suggested that these nervous tissues might serve as the site of viral latency. Although nervous tissue was not sampled from the fish examined here, the sensitive and specific diagnostic PCR assay described here will provide opportunities to corroborate and extend *in situ* hybridization data on CyHV1 pathogenesis (N. Sano et al. 1993a).

Histopathology in the diseased koi examined revealed epidermal hyperplasia expected for CyHV1. Although typical herpesviral-induced nuclear changes including margination of chromatin and inclusions have been observed by some authors (T. Sano et al. 1985a, 1991b, Hedrick et al. 1990), other studies including ours have not observed such changes (Calle et al. 1999). However, as virus is isolated most reliably shortly after skin lesions first appear (N. Sano et al. 1993a), and as nuclear inclusions cease to be evident when a CyHV1 epidemic passes its peak (Löwenthal 1907), lesions might already have been regressing in the affected koi when first examined. This possibility is also supported by the advanced degenerative state of the affected epidermis in the

fish as evidenced by the prominence of lymphocytic infiltrates and single-cell necrosis. Despite microscopic evidence of lesion regression, the PCR assay described here was able to detect CyHV1.

Restriction fragment analysis of CyHV1 isolates from diseased Japanese koi revealed slight differences supporting close genetic relatedness (Sano et al. 1991a). The CyHV1 TK gene sequence amplified from diseased koi and common carp from diverse geographical locations segregated into 3 distinct types: (1) koi from Oregon; (2) koi from northern California and Brazil; and (3) koi and common carp from southern California, Japan, and the UK (Fig. 1). The Type 3 grouping of the European (UK) and Asian (Japan) samples is perhaps expected considering CyHV1 existed in Europe and Asia prior to its introduction into North America via the release of common carp in the late 1800s (Bartlett 1905, Cole 1905). Although further details on the CyHV1 disease in the UK common carp are not known, it is possible that the koi cohabitating with the common carp originated from Japan and were the source of the virus. Similarly, the Type 3 grouping of the southern California sample is not surprising considering that these koi had been imported recently from Japan. The Brazilian sample is the first report of CyHV1 occurring in the Southern Hemisphere and underscores the importance of robust import biosecurity policies. Although the data on the origins of fish examined from northern California, Brazil, and Oregon are not available, the TK gene sequence suggests that it might be a useful phylo-

genetic marker in epidemiologic investigations and in determining the broader geographical distribution and nature of CyHV1 in both cyprinid and non-cyprinid species in which disease commonly referred to as a carp pox has been detected.

In recent years, the incidence of CyHV1 disease has declined in European and Israeli common carp aquaculture industries due to shifts away from using inbred strains (Schäperclaus 1941, 1969, 1979, Hines et al. 1974, Hoole et al. 2001). However, disease continues to negatively impact the large-scale production of common and hybrid carp in China (Jiang 1995, Pao & Kuanhong 2005, Lu et al. 2009) as well as the international koi industry (Sano et al. 1985b). Although important exceptions have been noted among severely affected specimens (Hoole et al. 2001, Pao & Kuanhong 2005, Lu et al. 2009), mortality is generally low in adult koi and common carp as well as in hybrids. However, fish may exhibit reduced growth and become less marketable due to the cosmetic impact of the viral-induced cutaneous lesions (Bauer 1961, T. Sano et al. 1985b, Wolf 1988). Control strategies employed currently to reduce the impact of the disease include the cultivation of resistant common carp strains, minimizing stress by avoiding excessive stocking densities and maintaining water quality, prophylactic water treatments involving the addition of lime or herbal extracts (Schäperclaus 1941, Jiang 1995), formalin baths in severe cases in which mortality is observed (Jiang 1995), and raising the water temperature. Virus concentrations are reduced significantly with low pH (3.0), heating, and certain chemotherapeutics (IUdR) (T. Sano et al. 1985a). Given the persistent nature of the CyHV1 infection and the lack of treatments to effectively clear a fish population of the virus, culling afflicted populations may provide a more appropriate control strategy, especially if naïve populations can be reestablished. The global distribution of the virus has likely arisen from the largely unregulated regional and international movements of fancy and common carp, the persistent nature of the virus, and the lack of coordinated surveillance programs. The diagnostic CyHV1 PCR assay described here is specific and sensitive, and with further validation could become integral to controlling the spread of CyHV1.

**Acknowledgements.** We thank T. Prew (Oregon Koi Gardens) and M. Tjaden (Flora Tropicana) for providing samples. This work was supported in part by the São Paulo Research Foundation (FAPESP).

## LITERATURE CITED

- ✦ Aoki T, Hirono I, Kurokawa K, Fukuda H and others (2007) Genome sequences of three koi herpesvirus isolates representing the expanding distribution of an emerging disease threatening koi and common carp worldwide. *J Virol* 81:5058–5065
- ✦ Bartlett SP (1905) Carp, as seen by a friend. *Trans Am Fish Soc* 34:207–216
- Bauer ON (1961) Diseases of carp in fish ponds in Leningrad, Velikie Luki, and Novgorod Oblast's. *Parasites Dis Fish* 42:68–88
- ✦ Bercovier H, Fishman Y, Nahary R, Sinai S and others (2005) Cloning of the koi herpesvirus (KHV) gene encoding thymidine kinase and its use for a highly sensitive PCR based diagnosis. *BMC Microbiol* 5:13
- ✦ Calle PP, McNamara T, Kress Y (1999) Herpesvirus-associated papillomas in koi carp (*Cyprinus carpio*). *J Zoo Wildl Med* 30:165–169
- Chistiakov DA, Voronova NV (2009) Genetic evolution and diversity of common carp *Cyprinus carpio* L. *Cent Eur J Biol* 4:304–312
- ✦ Cole LJ (1905) The status of the carp in America. *Trans Am Fish Soc* 34:201–206
- ✦ Davison AJ, Kurobe T, Gatherer D, Cunningham C and others (2013) Comparative genomics of carp herpesviruses. *J Virol* 87:2908–2922
- Dixon PF (2008) Virus diseases of cyprinids. In: Eiras JC, Segner H, Kapoor BG (eds) *Fish diseases*, Vol 1. Science Publishers, Enfield, NH, p 87–184
- Freitas JT, Subramaniam K, Kelley KL, Marcquenski S, Groff J, Waltzek TB (2016) Genetic characterization of esocid herpesvirus 1 (EsHV1). *Dis Aquat Org* 122:1–11
- Hall TA (1999) BioEdit: a user-friendly biological sequence alignment editor and analysis program for Windows 95/98/NT. *Nucleic Acids Symp Ser* 41:95–98
- ✦ Hedrick RP, Groff JM, Okihiro MS, McDowell TS (1990) Herpesviruses detected in papillomatous skin growths of koi carp (*Cyprinus carpio*). *J Wildl Dis* 26:578–581
- ✦ Hedrick RP, Gilad O, Yun S, Spangenberg JV and others (2000) A herpesvirus associated with mass mortality of juvenile and adult koi, a strain of a common carp. *J Aquat Anim Health* 12:44–57
- ✦ Hines RS, Wohlfarth GW, Moav R, Hulata G (1974) Genetic differences in susceptibility to two diseases among strains of the common carp. *Aquaculture* 3:187–197
- Hofer B (1904) *Handbuch der Fischkrankheiten*. Verlag Allgemeine Fischerei-Zeitung, Munich
- Hoole D, Bucke D, Burgess P, Wellby I (2001) *Diseases of carp and other cyprinid fishes*. Blackwell Science/Fishing News Books, Malden, MD
- Jiang Y (1995) Advances in fish virology research in China. In: Shariff M, Arthur JR, Subasinghe RP (eds) *Diseases in Asian aquaculture II*. Fish Health Section, Asian Fisheries Society, Makati, p 211–225
- ✦ Lievens B, Frans I, Heusdens C, Juste A, Jonstrup SP, Liefbrig F, Willems KA (2011) Rapid detection and identification of viral and bacterial fish pathogens using a DNA array-based multiplex assay. *J Fish Dis* 34:861–875
- ✦ Löwenthal W (1907) Einschlussartige Zell- und Kernveränderungen in der Karpfenpocke. *Z Krebsforsch* 5:197–204
- ✦ Lu H, Zhu G, Fan L, Zhang L (2009) Etiology and pathology of epidermal papillomas in allogynogenetic crucian carp *Carassius auratus gibelio* (♀) × *Cyprinus carpio* var. *singouensis* (♂). *Dis Aquat Org* 83:77–84



- Lucky Z (1970) Pathological changes with pox (*Epithelioma papulosum*) in the sheatfish (*Silurus glanis*). Acta Vet Brno 39:81–86
- Margaritov N (1982) Influence of the anesthetic tricaine methane sulfonate MS-222 on the size and age composition of peripheral blood erythrocytes of the common carp *Cyprinus carpio*. God Sofii Univ 'Kliment Okhridski' Biol Fak 75:71–81
- McAllister PE (1993) Goldfish, koi, and carp viruses. In: Stoskopf MK (ed) Fish medicine. Saunders Company, Philadelphia, PA, p 478–485
- ✦ McAllister PE, Lidgerding BC, Herman RL, Hoyer LC, Hankins J (1985) Viral diseases of fish—first report of carp pox in golden ide (*Leuciscus idus*) in North America. J Wildl Dis 21:199–204
- ✦ Morita N, Sano T (1990) Regression effect of carp, *Cyprinus carpio* L, peripheral blood lymphocytes on CHV-induced carp papilloma. J Fish Dis 13:505–511
- ✦ Nigrelli RF (1952) Virus and tumors in fishes. Ann NY Acad Sci 54:1076–1092
- Päkk P, Hussar P, Järveots T, Paaver T (2011) Club cells active role in epidermal regeneration after skin hyperplasia of koi carp *Cyprinus carpio*. Aquacult Aquar Conserv Legis Bioflux 4:455–462
- Pao X, Kuanhong M (2005) Viral studies on carp disease in China—with a special reference to herpesvirus on common carp. Bull Fish Res Agency (Suppl 2):27–34
- Sano N, Honda R, Fukuda H, Sano T (1991) Herpesvirus cyprini: restriction endonuclease cleavage profiles of the viral DNA. Fish Pathol 26:207–208
- ✦ Sano N, Sano M, Sano T, Hondo R (1992) *Herpesvirus cyprini*: detection of the viral genome by *in situ* hybridization. J Fish Dis 15:153–162
- ✦ Sano N, Moriwake M, Hondo R, Sano T (1993a) *Herpesvirus cyprini*: a search for viral genome in infected fish by *in situ* hybridization. J Fish Dis 16:495–499
- ✦ Sano N, Moriwake M, Sano T (1993b) Herpesvirus cyprini: thermal effects on pathogenicity and oncogenicity. Fish Pathol 28:171–175
- ✦ Sano T, Fukuda H, Furukawa M (1985a) Herpesvirus cyprini: biological and oncogenic properties. Fish Pathol 20:381–388
- Sano T, Fukuda H, Furukawa M, Hosoya H, Moriya Y (1985b) A herpesvirus isolated from carp papilloma in Japan. In: Ellis AE (ed) Fish and shellfish pathology. Academic Press, London, p 307–311
- Sano T, Morita N, Shima N, Akimoto M (1991) *Herpesvirus cyprini*: lethality and oncogenicity. J Fish Dis 14: 533–543
- Schäperclaus W (1941) Fischkrankheiten, 2nd edn. Gustav Wenzel & Sohn, Braunschweig
- Schäperclaus W (1969) Virusinfektionen bei Fischen. In: Rohrer H (ed) Handbuch der Virusinfektionen bei Tieren, Vol 2. Gustav Fischer Verlag, Jena, p 106–114
- Schäperclaus W (1979) Fischkrankheiten, 4th edn. Akademie-Verlag, Berlin
- ✦ Schubert G (1964) Elektronenmikroskopische Untersuchungen zur Pockenkrankheit des Karpfen. Z Naturforsch B 19:675–682
- ✦ Schubert GH (1966) The infective agent in carp pox. Bull Off Int Epizoot 65:1011–1022
- ✦ Sonstegard RA, Sonstegard KS (1978) Herpesvirus-associated epidermal hyperplasia in fish (carp). IARC Sci Publ 24:863–868
- ✦ Steinhagen D, Kruse P, Neukirch M (1992) Virus-associated epidermal hyperplasia in golden ide *Leuciscus idus melanotus*. Dis Aquat Org 13:225–229
- ✦ Thompson JD, Gibson TJ, Plewniak F, Jeanmougin F, Higgins DG (1997) The ClustalX windows interface: flexible strategies for multiple sequence alignment aided by quality analysis tools. Nucleic Acids Res 25:4876–4882
- Timur G (1991) A histological study of a carp pox (viral epithelioma) disease in Turkey. Bull Eur Assoc Fish Pathol 11:171–173
- ✦ Untergasser A, Cutcutache I, Koressaar T, Ye J, Faircloth BC, Remm M, Rozen SG (2012) Primer3—new capabilities and interfaces. Nucleic Acids Res 40:e115
- ✦ Waltzek TB, Kelley GO, Stone DM, Way K and others (2005) Koi herpesvirus represents a third cyprinid herpesvirus (CyHV-3) in the family *Herpesviridae*. J Gen Virol 86: 1659–1667
- ✦ Waltzek TB, Kelley GO, Alfaro ME, Kurobe T, Davison AJ, Hedrick RP (2009a) Phylogenetic relationships in the family *Alloherpesviridae*. Dis Aquat Org 84:179–194
- ✦ Waltzek TB, Kurobe T, Goodwin AE, Hedrick RP (2009b) Development of a polymerase chain reaction assay to detect cyprinid herpesvirus 2 in goldfish. J Aquat Anim Health 21:60–67
- Wolf K (1988) Fish viruses and fish viral diseases. Cornell University Press, Ithaca, NY
- Yardimci B, Secer FS, Yavuzcan H (2009) Histopathological and electron microscopical evaluation of pox disease in carp (*Cyprinus carpio* L.). Ankara Univ Vet Fak Derg 56: 43–45

Editorial responsibility: Jeff Cowley,  
Brisbane, Queensland, Australia

Submitted: September 23, 2015; Accepted: October 3, 2016  
Proofs received from author(s): January 17, 2017