

Vascularized fibular graft for chronic osteomyelitis of humerus in a 10 years child

Belsare Kiran^{*}, Thakkar Shyam, Sharoff Lokesh and Parekh Aseem

Department of Orthopaedics, B.Y.L Nair Charitable Hospital & T.N Medical College, Mumbai central, Mumbai. Maharashtra, India, 400008

***Correspondence Info:**

Dr. Kiran Sudhakar Belsare,
Department of Orthopaedics,
B.Y.L Nair Charitable Hospital & T.N Medical College, Mumbai Central, Mumbai.
Maharashtra, India, 400008
E-mail: kiranbelsare98@gmail.com

Abstract

Introduction: Reconstruction of large skeletal defects secondary to osteomyelitis remains a challenging problem. Free vascularized bone can be used to reconstruct large skeletal defects greater than 6 cm or bone defects of smaller size that failed to heal with nonvascularized bone grafting. There are only few case reports which describe it in such a young age group.

Case report: We report a case of a 9 years male child with a right proximal humerus osteomyelitic defect treated with a vascularized fibular graft and plating with a 6 months follow up having a satisfactory functional outcome.

Conclusion: Free vascularized fibula transfer is an efficient technique for exceptional cases of multi-operated and aseptic resistant non-union with bone defect of the humerus. The indications for vascularized bone grafting are skeletal defects greater than 6 cm or smaller defects that have failed to heal with nonvascular bone graft with a reported success rate of 77%-90%.

Keywords: Osteomyelitis, vascularised fibular graft, skeletal defects

1. Introduction

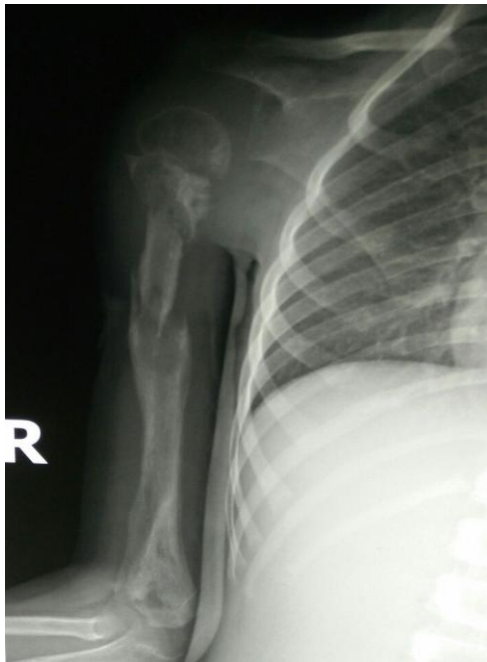
Reconstruction of large skeletal defects secondary to osteomyelitis remains a challenging problem. Osteomyelitis can result from a variety of etiologies; most often, it is a consequence of trauma to a long bone. Despite advances in antibiotic therapy, treatment of chronic osteomyelitis requires adequate surgical debridement, which can often lead to large soft tissue and bone loss. Free vascularized bone can be used to reconstruct large skeletal defects greater than 6 cm or bone defects of smaller size that failed to heal with nonvascularized bone grafting. The length, cortical strength, and anatomic configuration of the free vascular fibular graft makes it an ideal bone graft to bridge extremity defects, and it can be transferred with skin, fascia, and muscle to fill soft tissue defects in the recipient site. There are only few case reports which describe it in such a young age group.

2. Case history

A 9 years male child came to the orthopaedic OPD with a history of fall while playing followed by trauma to right (Rt) upper limb. On radiographs of the Rt humerus, an undisplaced lateral condyle fracture was seen for which an above elbow slab was given. Patient returned to the OPD after 1 week with gross swelling and erythema of the arm. Radiographs were repeated of the Rt humerus and osteomyelitis of the entire humerus was noted with extension to the shoulder and elbow joint (Fig. 1). Serum inflammatory markers were also raised. Emergency Rt shoulder and elbow arthrotomy was performed and k-wire fixation for the lateral condyle fracture was done. Culture was positive for *Pseudomonas* and antibiotics were started accordingly. Further debridement was done twice for persistent discharge from the wound within a period of 3 months after which the wound became healthy and there was no further discharge. Patient followed up after 8 months in OPD and repeat radiographs

showed a segmental defect of the proximal humeral metaphysis (Fig.2a & 2b). After a follow-up of 2 years, and on consultation with the microvascular surgeon, free vascularized fibular grafting along with proximal humerus plating was done (Fig. 3a & 3b). Post operative follow up of 6 months showed fibular graft was completely incorporated in the defect proximally and distally (Fig 4a & 4b). Patient has satisfactory function of the shoulder and elbow with good grip strength (Fig 5a & 5b).

Figure 1: Pain radiograph AP view of right humerus showing osteomyelitic changes involving the entire humerus



Figures 2a and 2b: Plain radiograph of the right humerus showing osteomyelitic bone defect.

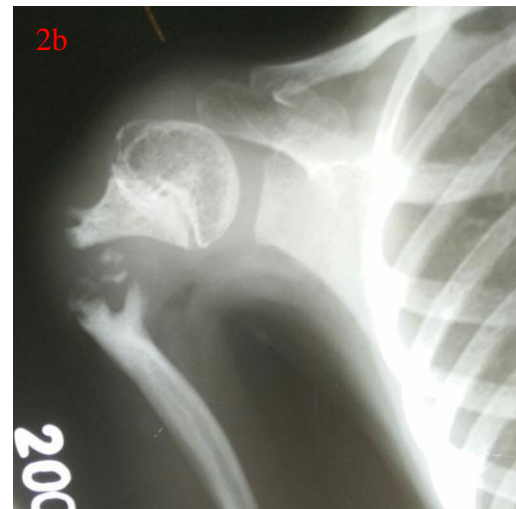
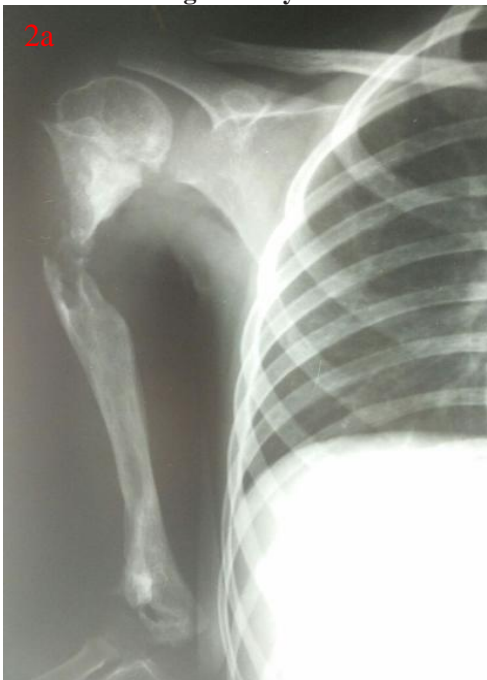
Figure 3a and 3b: Plain radiographs showing immediate postoperative status with plate *in situ*

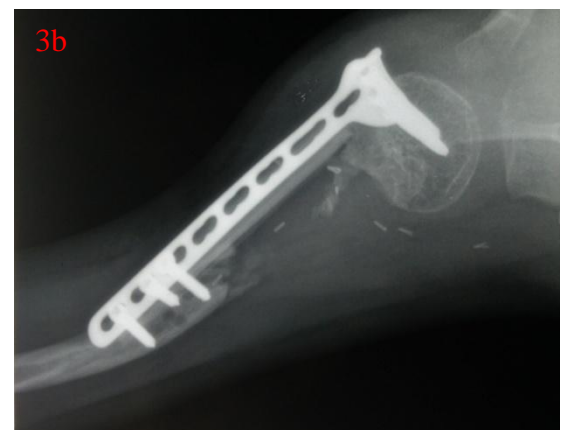
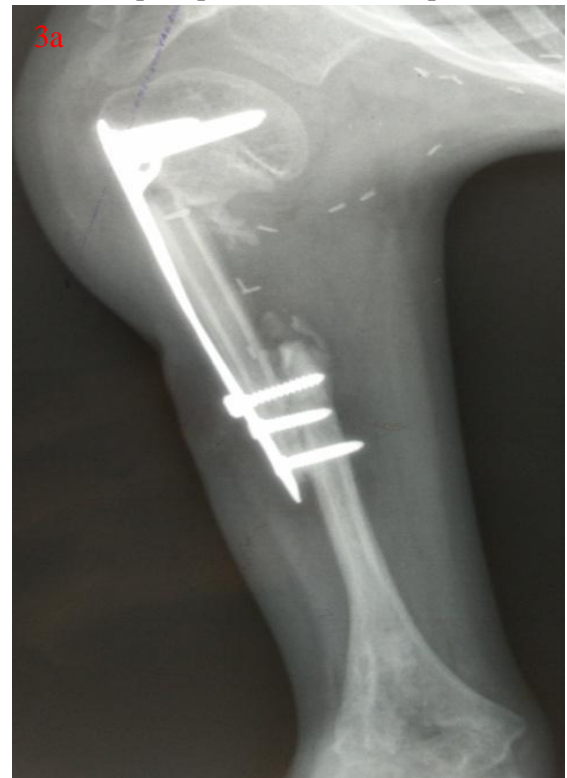
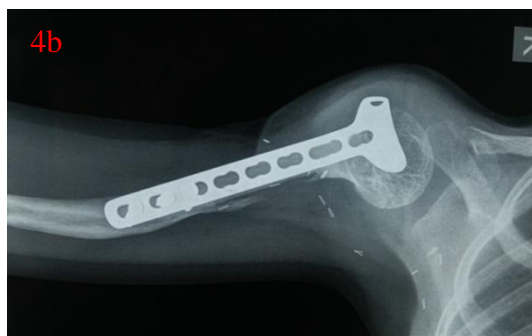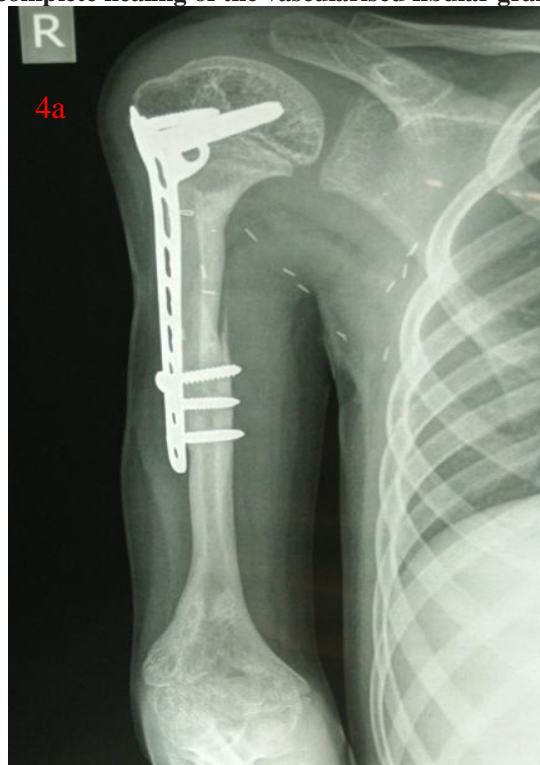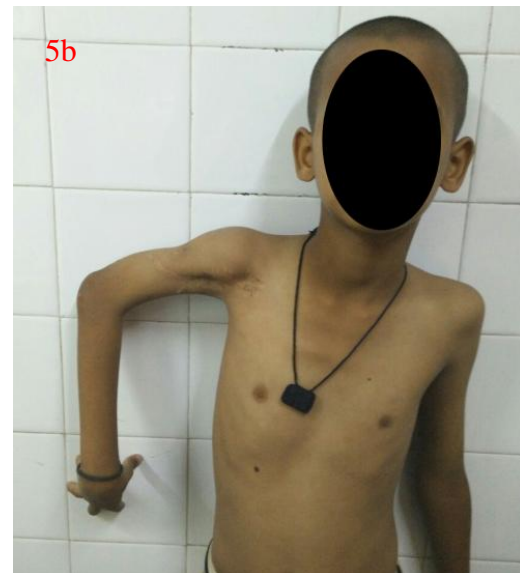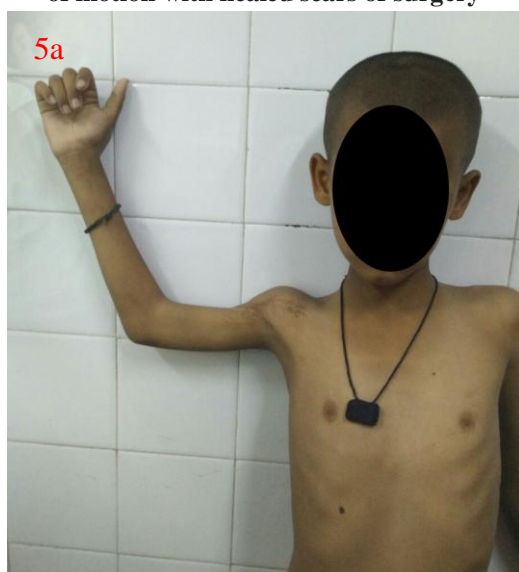Figure 4a and 4b: 6 months postoperative plain radiographs of the right humerus showing complete healing of the vascularised fibular graft



Figures 5a and 5b: Showing good shoulder range of motion with healed scars of surgery



3. Discussion

Surgical management of osteomyelitis is often challenging. Adequate surgical debridement decreases the bacterial load, removes dead necrotic tissues, and gives a chance for the host immune system and antibiotics to arrest infection. Adequate debridement may leave a large bony defect, or dead space. Appropriate management of dead space is essential to arrest the disease and for maintenance of the bone integrity. The objective of dead-space management is the replacement of dead bone and scar tissue with durable vascularized tissue. Complete wound closure should be attained whenever possible, and local tissue flaps or free flaps may be used to fill dead space [1].

Numerous surgical options can be used to treat fracture related humeral bone defects such as primary shortening, cancellous bone graft in one stage, cancellous bone graft in two stages (after induced membrane technique), pedicle bone transfer (free border of the scapula, 9th rib), periosteal free flap transfer or bone morphogenetic protein. Although non-vascularized bone grafting is effective in small bone defect with well-perfused soft tissues, they are less reliable when the gap defect is greater than 6 cm and when soft tissue vascularization is poor. Indeed, blood support is essential to increase bone healing and to avoid infection. Moreover, vascularized bone graft (VBG) provides higher biomechanical strength than non-vascularized techniques [2]. Defects less than 6 cm can be bridged with conventional autogenous bone grafts such as cortico-cancellous iliac crest graft. Defects greater than 6 cm will likely require distraction osteogenesis with Ilizarov frames or a vascularized bone graft. These grafts have become an important tool for the reconstructive surgeon dealing with the management

of long bone defects or difficult nonunions. They are especially important in the setting of osteomyelitis treatment because they combine the advantages of viable cancellous autograft with the stability of cortical analogues while leaving the nutrient blood supply intact. Indications for their use include skeletal defects more than 6 cm in length, defects associated with a poor soft tissue envelope, and in cases where smaller sized nonvascularized bone grafts have failed to incorporate.

Vascularized bone grafts incorporate into the recipient site through a different process than that of avascular grafts. The vascularized grafts bypass the process of creeping substitution, which involves necrosis of the graft, resorption, and new bone formation. They maintain their mass, architecture, and biomechanical strength. Furthermore, the transferred vascularized bone has the ability to hypertrophy, especially in the lower extremity because of increased mechanical loading. Available donor bones to be used for vascularized bone grafts include the fibula, ilium, scapula, and rib flaps. The fibula's length, straight configuration, cortical support, and composite tissue make it ideal for the reconstruction of segmental long bone defects. The vascularized fibular graft (VFG) can be used to reconstruct defects of up to 26 cm. Its size and relatively straight configuration allow it to be used within the humerus, forearm, clavicle, as well as in the tibia and femur. When considering use of a free osteocutaneous flap for reconstruction, it is important to evaluate carefully both the intended recipient site and the donor site for integrity and vascularity to ensure minimal morbidity and reconstructive success. Radiographs and three dimensional imaging of the recipient site is useful in determining the length of the bony defect and the amount of bone stock necessary for transfer. Determination of thickness and length of bone required will help in determining what donor site to choose if preparing for vascularized bone transfer. Smaller defects may be managed with cadaveric bone or bone substitutes depending on the recipient bed and use of adjunctive therapy (i.e., hyperbaric oxygen therapy) preoperatively and postoperatively.

In planning reconstruction of the limb after osteomyelitis debridement, the length and alignment of the limb should be considered so that any deformities can be addressed. In addition, an adequate vascular assessment prior to fibula transfer is performed, including the presence of adequate pulses in both the posterior tibial and dorsalis pedis arteries along with Doppler ultrasound to confirm adequate blood flow in the donor site. Any abnormal pulses or the presence of major trauma to the donor

site could imply variability in the vessels, and magnetic resonance angiography or conventional angiography is warranted. For the recipient limb, it is important to establish that the arteries and veins are of sufficient caliber. Consideration should also be given to the most appropriate method of fibular stabilization.

Depending on the defect length and location within the recipient bone, bony fixation devices such as transcortical screws, compression plates, intramedullary nails, and external fixation can be used. Finally, it is important to document the preoperative status of the common peroneal nerve at the donor site as injury to this nerve can occur during the course of fibular harvesting [3]. In 2009, Chhabra *et al* [3] reviewed 13 cases of chronic non-union of the humerus resulting from trauma or osteomyelitis treated with vascularized fibula transfer after failure of conventional treatment. Healing was obtained in 92% of patients in a mean time of 18 months. Vascularized fibular grafting offers the patient a great deal of benefit and also complications such as infection, recurrent non-union transient palsy of the radial nerve occur in only 7% to 10% of cases [4]. Stress fracture is a more common event (10 to 15%) [5]

4. Conclusion

According to our experience and the review of the literature, free vascularized fibula transfer is an efficient technique for exceptional cases of multi-operated and aseptic resistant non-union with bone defect of the humerus. This technique comes into competition with induced membrane technique. This significantly invasive procedure is not without risk but remains acceptable in salvage situation with a standardized procedure and experienced surgeon. Although other options are available for long bone osteomyelitis reconstruction, the VFG has remained our most valuable reconstructive option for the treatment of these defects. The indications for vascularized bone grafting are skeletal defects greater than 6 cm or smaller defects that have failed to heal with nonvascular bone graft. The VFG can be transferred with skin, fascia, and muscle to fill soft tissue defects. Reported success rates using the VFG to bridge skeletal defects from osteomyelitis range from 77 to 90%. Complications include anastomosis failure, donor-site morbidity, and fracture of the grafted bone.

Competing interests: The authors declare that they have no competing interest.

Consent: The patient has given the necessary consent for the case report to be published.

References

- [1] Jason H. Calhoun, M.M. Manring, Mark Shirtliff. Osteomyelitis of the long bones. *Semin Plast Surg*. 2009 May; 23(2): 59–72.
- [2] Kerfant N, Valenti P, Kilinc AS, et al. Free vascularized fibular graft in multi-operated patients for an aseptic non-union of the humerus with segmental defect: Surgical technique and results. *Orthop Traumatol Surg Res*. 2012 Sep; 98(5):603-7.
- [3] Chhabra AB, Golish SR, Pannunzio ME, et al. Treatment of chronic nonunions of the humerus with free vascularized fibula transfer: a report of thirteen cases. *J Reconstr Microsurg* 2009; 25:117—24.
- [4] Arai K, Toh S, Tsubo K, et al. Complications of vascularized fibula graft for reconstruction of long bones. *Plast Rec Surg* 2002; 7:2301-6.
- [5] Adani R, Delcroix L, Tarallo L, et al. Reconstruction of posttraumatic bone defects of the humerus with vascularized fibular graft. *J Shoulder Elbow Surg* 2008; 17(4):578—84.