

Case Report

Variations in Superior Pancreaticoduodenal Artery -A case report

S.S. Imran*¹ and Sarita Sylvia²

¹Associate Professor, Department of Anatomy, M.R. Medical College, Gulbarga, India

²Assistant Professor, Department of Anatomy, M.R. Medical College, Gulbarga, India

*Correspondence Info:

Dr. S.S. Imran

Associate Professor

Department of Anatomy,

M.R. Medical College.

Sedam Road, Gulbarga-585105 India

Email: drimranqazi@yahoo.com , uzairquadri@gmail.com

Abstract

The superior pancreaticoduodenal artery typically arises as the first branch of gastroduodenal artery, above the upper border of the head of the pancreas, and passes either above or behind the first part of duodenum. During the routine dissection in the department of Anatomy, This rare variation of superior pancreaticoduodenal artery was noticed in a male cadaver of approximately 50 years of age. In this case the superior pancreaticoduodenal artery showed variation in its branching pattern. The artery appeared more tortuous, wide and long. More details in this regard and clinical aspects will be discussed.

Keywords: Gastroduodenal artery, anastomosis, branching pattern

1. Introduction

The superior pancreaticoduodenal artery is one of the terminal divisions of the gastroduodenal artery at about the lower border of the first part of the duodenum, the other terminal branch being right gastroepiploic. The superior pancreaticoduodenal artery is usually double, one anterior and one posterior. They course along the concavity of the C shaped loop of the duodenum between the gut wall and the head of the pancreas. They anastomose with the anterior and posterior divisions of the inferior pancreaticoduodenal artery.

The second, third and fourth parts of the duodenum and part of the head of the pancreas are typically supplied primarily through two arterial arcades, an anterior and posterior one formed respectively by the union of anterior superior with anterior inferior and posterior superior with posterior inferior pancreaticoduodenal arteries¹.

2. Case Report

During dissection of abdomen for undergraduate students of past 2 batches about 25 bodies of both sexes were observed for any variation in the pancreaticoduodenal artery.

In the present study a male cadaver aged about 50 years old was having a very short celiac trunk and the gastroduodenal artery was directly arising from it. The common hepatic artery and the left gastric artery were also directly arising from the celiac trunk.

The superior pancreaticoduodenal artery is

- 1) Arising from the hepatic artery.
- 2) Long, tortuous and wide.
- 3) Diameter is equal to the splenic artery.

4) Giving multiple long and straight branches to the duodenum and lastly anastomosing with the inferior pancreaticoduodenal artery.

Hence the superior pancreaticoduodenal artery is single and not divided into anterior and posterior branches but continued as a single wide, tortuous artery at the junction of duodenum and head of the pancreas and supplying branches on anterior and posterior aspect and lower down anastomosing with inferior pancreaticoduodenal artery which is also simple and undivided.

3. Discussion

Knowledge of pancreatic arterial anatomy and arterial territory is important not only to perform pancreatic arterial intervention, but to read the pancreatic angiography, cross sectional images and while dealing with gastric and duodenal ulcers. Woodburne and Olsen found in 99.3%, Piersen in 96% and Petren in 100% Pancreaticoduodenal artery almost arises from the gastroduodenal artery and crosses in front of the common bile duct in Woodburne and Olsen's series by far the largest yet reported, this origin obtained in 92.6%².

The other origin which they found were from hepatic artery 2.7%, the superior mesenteric artery 3.4% and dorsal pancreatic 1.3%.

Bergman et al reported that dorsal pancreaticoduodenal arose from the splenic artery in 37%, celiac trunk in 33%, superior mesenteric artery in 21% and common hepatic artery in 8% of cases³. Michels reported few cases (2.5%) in 200 dissections with the gastroduodenal artery originating from the celiac trunk⁴.

Bertelli et al have demonstrated angiographically many possible different sources of the posterior superior pancreaticoduodenal A. (Superior pancreaticoduodenal a, proper hepatic a, right hepatic a, left hepatic a, superior mesenteric a, accessory a, and replaced right hepatic artery coming from the superior mesenteric artery)⁵.

Percentage of origin of pancreaticoduodenal Artery

| Name of the Author | Arising from Gastroduodenal artery. | Arising from Hepatic artery | Arising from superior mesenteric Artery | Arising from dorsal pancreatic artery |
|---------------------|-------------------------------------|-----------------------------|---|---------------------------------------|
| Woodburne and Olsen | 92.60% | 2.70% | 3.40% | 1.30% |

4. Conclusion

During pancreaticoduodenectomies or lymph node resection procedures, ligation of IPDA also requires special attention, because of high incidence of common trunk formation of the first jejuna and IPDA⁶.

The present study emphasizes the uncommon variations in the pancreaticoduodenal artery as it was arising from the hepatic artery, so it is a rare case because as per the previous investigators only 2.7% of the cases arises from the hepatic artery.

References

1. Gray's Anatomy- 2000 (Reprint), 38th Edn.
2. Woodburne R.T. and Olsen, LL. The arteries of the pancreas, Anat.Rec. 1951; 111:225-270
3. Michels NA, "Anatomical Variation of Arterial pancreatoduodenal arcades", *J. International college of surgeon* (1962),37: 13-40
4. Bergman RA, Thompson Sa, Afili K, Saadeh FA, Compendium of human Anatomic variations, Baltimore Munich, Urban & schwarzenberg. 1988: 79.
5. Bertelli E, Di Gregorio F, Bertelli L, Civeli L, Mosca S: The arterial blood supply of the pancreas A reviewII. The posterior superior superior pancreaticoduodenal artery, An anatomical & radiological study: *Surg Radiol Anat*, 1996;18(1) 1-9.
6. Murakami G, Hirata k, Takmura, Mukaiya M, HataF, Kitagawa S, Vascular antomy of pancreaticoduodenal region, *J Hepatobiliary pancreatic surg*, 1999;66; 55-88.

Figure No 1: Showing Superior Pancreaticoduodenal artery arising from Hepatic artery and showing its long, wide and tortuous nature.

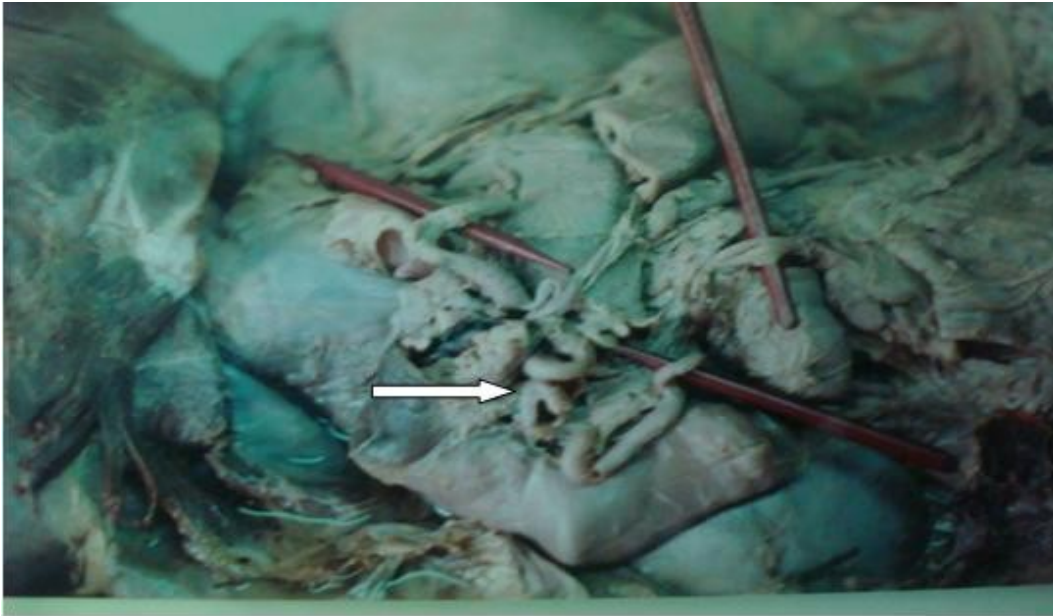


Figure No 2: Showing Superior Pancreatico duodenal artery giving long, straight and multiple branches to the duodenum.

