

Research Article

Histomorphometric study for volume proportion of certain parameters in placenta of pregnancy induced hypertension

Anup Shyamal^{*1}, A M Tarnekar², Poonam Shivkumar Verma³, Piyali Das⁴, Ahsan Ahmed⁵ and M R Shende⁶

¹Assistant Professor, Department of Anatomy, Calcutta National Medical College, Kolkata, West Bengal, India.

²Professor, Department of Anatomy, MGIMS, Sewagram, Maharashtra, India

³Professor & Head, Department of Gynaecology and Obstetrics, MGIMS, Sewagram, Maharashtra, India

⁴Assistant Professor, Department of Physiology, Calcutta National Medical College, Kolkata, West Bengal, India.

⁵Consultant Anaesthesiology, Medica Super Speciality Hospital, Kolkata, West Bengal, India.

⁶Professor & Head, Department of Anatomy, MGIMS, Sewagram, Maharashtra, India

*Correspondence Info:

Dr. Anup Shyamal

Assistant Professor,

Department of Anatomy,

Calcutta National Medical College, Kolkata, West Bengal, India.

Email: drashyamal@gmail.com

Abstract

Introduction: placenta is vital link between mother and fetus. The organ for pregnancy serves as exchange membrane and hormone synthesizing apparatus for both mother and fetus. All physiological processes occurring in fetus or mother are reflected on placenta. Pregnancy induced hypertension is such a co-morbid condition which affects mother and fetus as well as placenta.

Aim and objective: To study the desired histomorphometrical parameters in control and experimental (PIH) group of placentae after staining with Hematoxylin & Eosin(H/E) and Masson's trichrome to find out the statistical relevance of the comparative findings.

Material and method: Forty (40) control and forty (40) experimental placentae (PIH) were collected and processed for routine histological techniques. Paraffin sections were stained with routine H/E and Masson's trichrome stain. Light microscopy for histological and histomorphometrical study was performed to obtain volume proportion of fibrinoid degeneration and microscopic calcification.

Observation: volume proportion of fibrinoid degeneration and microscopic calcification were significantly increased in PIH cases in comparison to control.

Conclusion: Like other diseases the PIH also affects the structural and functional unit of placenta. The changes appear to be compensatory to hypoxia and altered metabolism in tissue space.

Key Words: Volume Proportion. Fibrinoid Degeneration. Microscopic Calcification. Placenta. PIH.

1. Introduction

Placenta is the organ belonging to the developing mammalian conceptus which is never incorporated in the body of foetus but it is vital to the well-being of the baby in the womb and it offers protective, nutritional, respiratory, synthetic and excretory functions. Thus it exists as a vital link between mother and developing fetus¹.

Placenta is basically chorionic tissue and trophoblasts are the representative cells. Hence trophoblasts are responsible for a successful outcome of pregnancy- a healthy baby and healthy mother, at the completion of intra-uterine life^{2,3,4,5,6}.

The outcome of pregnancy depends on many factors. One such factor is the health and wellbeing of mother throughout pregnancy. Any deviation from normal physiology would adversely affect not only the mother and foetus but the other gestational tissues as well^{1 and 7}.

Rise of blood pressure during pregnancy (gestational hypertension or pregnancy induced hypertension- 'PIH') is one of the most common causes of altered physiological process in pregnancy⁶.

The diagnosis of gestational hypertension is made in women whose blood pressure reaches 140/90 mm Hg or greater for the first time during pregnancy⁶. A number of hypotheses have been proposed to explain the aetiology of PIH. According to Sibai (2003) those are

1. Abnormal trophoblastic invasion of uterine vessels.
2. Immunological intolerance between maternal and foeto-placental tissues.
3. Maternal mal-adaptation to cardiovascular or inflammatory changes of normal pregnancy.
4. Dietary deficiencies.
5. Genetic influences⁶.

There are very few scientific works in support of such hypotheses. Since placenta acts as a mirror to the disease process in mother and fetus or both we decided to study gross and microscopic placental structure in PIH.

2. Material and Methods

Approval of 'Institutional Human Ethics Committee' was duly obtained before starting the work.

2.1 The chief study material was placenta

Forty (40) placentae were collected from Institutional labour room immediately after term delivery of mothers having uneventful antenatal period as control. Another forty (40) placentae were collected after term delivery of pregnant mothers who had clinically proven hypertension (pregnancy induced hypertension- PIH).

Inclusion criteria for all subjects:

Age of mother between 20 to 38 years¹⁰

Specific inclusion criterion for subjects enrolled as cases (experimental):

Clinically proven hypertension in antenatal (beyond 20 weeks of gestation) or in intranatal period.

Inclusion criteria for Subjects enrolled as controls (normal pregnancy)

- Subjects free from any pre existing clinical disorder.
- Uneventful antenatal period

Exclusion criteria for Subjects enrolled as experiment:

Hypertension with other gestational disorders, pre-existing hypertension, subjects having still birth, gross congenital anomalies in baby, complicated vaginal delivery, emergency lower segment caesarean section, invasive procedure during gestation.

Preparation for examination of placenta:

The intact sample of placenta was kept for one week in 10% formal saline for fixation and hardening so as to make it suitable for cutting into 2-3 cm pieces for further routine histological processing followed by section cutting, staining, microscopy and microphotography.

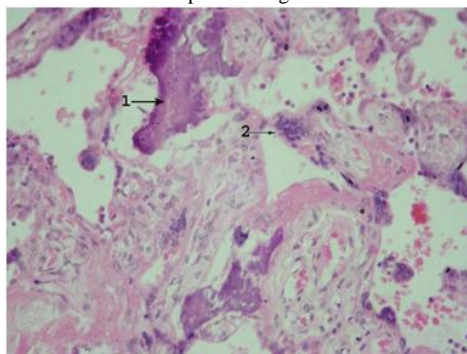
2.2 Method of light microscopy (Based on Hamilton and Boyd, 1970)

The stained slides of placentae of two groups were examined under binocular light microscope under different magnifications. Light microscopy was performed under different magnifications (X 100 with low power and X 400 in high power) under self illuminated binocular microscope. Hematoxylin and Eosin (H/E) staining was performed routinely while Masson's trichrome as special stain. In each slide all the serial sections were observed under microscope.

2.3 Identification under microscope

Areas of microscopic calcification:

Amorphous discrete basophilic matter present in villi of term placenta signifies calcification .

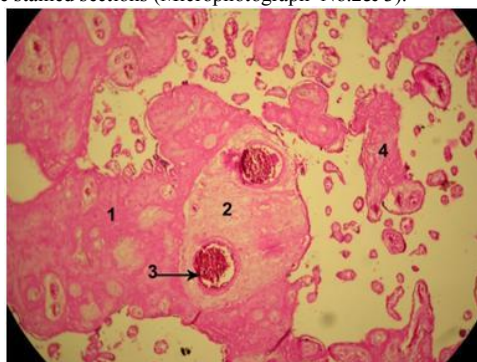


Micro photograph No 1. Calcification(microscopic): 400X. H/E stain. (Experiment)

1. Calcification 2. Syncytial knot

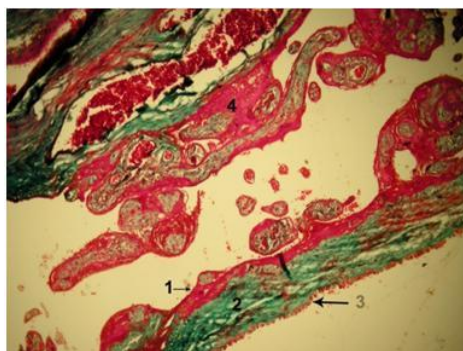
Areas of fibrinoid degeneration:

The eosinophilic homogeneous amorphous or fine lamellar or fibrillary or hyalinised substance seen in H/E stained sections around the villi (perivillous), within the vilus (intra villous), within the basal plate (Nitabuch's stria, many times referred to as maternal floor infarct), adjoining intervillous space and chorionic plate (Langhans stria) or rarely adjoining intervillous space and basal plate (Rohr's stria). It appears red in Masson's trichrome stained sections (Microphotograph No.2& 3).



Micro photograph No 2. Structure of diffuse fibrinoid degeneration in sections of villi and inter- Villous space of placenta 400X. H/E stain. (Experiment)

1. Fibrinoid degeneration 2. Old infarct
3. Fetal vessel 4. Fibrinoid



Micro photograph No 3. Features of Chorionic plate, villus and inter- Villous space of placenta 100 X Masson's trichrome stain (experiment)

- | | |
|-------------------------------|--------------------------------------|
| 1. Langhans stria (fibrinoid) | 2. Collagen fiber at Chorionic plate |
| 3. Amnion | 4. Fibrinoid at inter- villous space |

2.4 Method of histo-morphometry

Calculation of volume proportion: (Based on Delesse principle, 1848)

This method was applicable for calculation of the parameters like VP of terminal villi, VP of fibrinoid degeneration and VP of Calcification. This figure gives the proportion of the placental area occupied by a particular parameter. This is expressed in percent.

Following formula was used for determination of volume proportion

$$V_p = \frac{h}{h+m}$$

Vp- volume proportion of the given parameter

h- number of intersecting points of square grid hitting the selected object m- number of points falling elsewhere (h+ m was never above 100 as the total number of points in our graticule was 100).

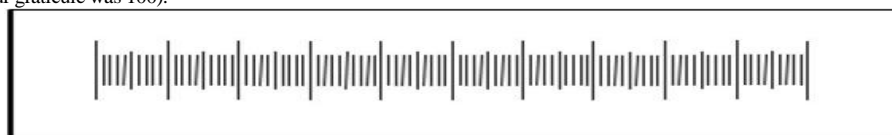

Figure 1: Low power view of linear graticule

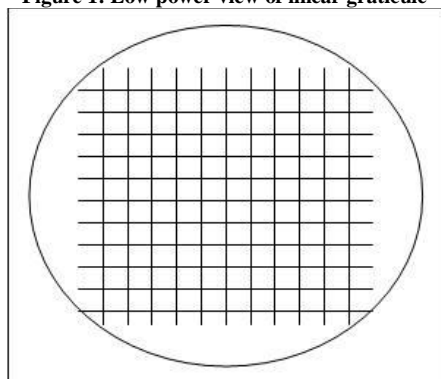


Figure 2 : Schematic Diagram showing Haugh's graticule used for Histomorphometric study

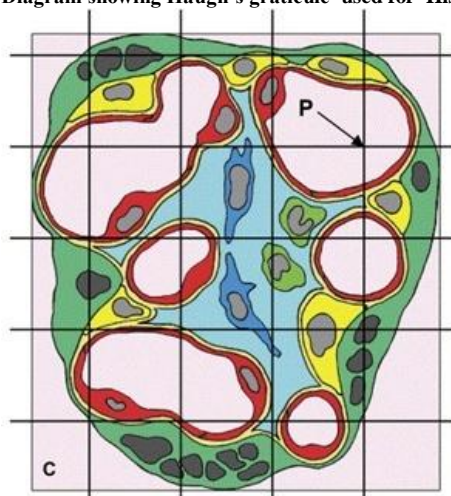


Figure No.3: showing the utilization of square graticule for calculation of volume proportion

Five fields of ten sections of each placenta were examined (50 fields of each placenta) for determination of volume proportion of a given parameter. For each placenta the average value of the desired parameter was obtained from these 50 fields and recorded in Table No. I.

2.5 Method for Statistical analysis

All the parameters judged for histo-morphometry were subjected to statistical analysis by comparing the data of case (experimental group) versus control and then the difference was assessed for statistical significance using student's 't' test.

3. Observation and results

3.1 Histomorphometry

The sections were studied under light microscope with the help of square and linear graticules.

Table No.I: Histomorphometry of placenta in both groups

Sample no	Vp FD		Vp CA	
	C	E	C	E
1	34.56	40.50	5.50	5.50
2	34.55	41.25	0	5.45
3	34.26	42.50	0	4.55
4	32.50	43.5	0	5.35
5	33.51	41.45	0	5.25
6	34.45	45.12	0	5.36
7	34.12	42.25	0	4.98
8	33.25	42.25	0	4.65
9	34.25	41.50	0	5.14
10	34.50	41.45	0	5.11
11	34.45	41.28	5.11	5.10
12	34.28	42.10	5.10	6.01
13	34.10	42.24	0	5.25
14	34.24	42.30	0	5.34
15	34.30	41.36	0	4.28
16	34.36	42.23	0	4.28
17	33.23	41.42	0	4.96
18	34.42	41.29	4.96	5.19
19	34.29	42.15	0	5.24
20	35.15	41.56	0	5.36
21	34.56	43.10	0	5.27
22	33.10	40.12	0	4.35
23	33.12	42.16	0	4.95
24	34.16	42.25	0	5.13
25	32.25	41.10	5.13	5.20
26	43.10	41.26	0	5.28
27	34.26	41.28	0	5.05
28	34.28	42.23	0	5.26
29	34.23	42.29	0	4.35
30	35.29	42.17	0	4.25
31	34.17	42.14	0	4.19
32	33.14	40.25	0	4.58
33	32.25	40.30	0	5.50
34	33.30	41.30	0	5.32
35	34.32	41.10	0	4.26
36	34.10	42.10	0	3.98
37	32.13	41.25	0	5.21
38	34.25	42.00	0	4.23
39	34.50	41.96	0	4.85
40	34.25	42.05	0	4.61

Vp FD: volume proportion of fibrinoid degeneration.

Vp CA: volume proportion of microscopic calcification.

C- Control. E : Experiment

Table No.II: Analysis of combined Histomorphometric features of placenta of both groups

Table No.II:

	Vp FD		Vp CA	
	C	E	C	E
Max	43.1	45.12	5.5	6.01
Min	32.13	40.12	0	3.98
P	< 0.05		<0.05	

Vp FD : volume proportion of fibrinoid degeneration

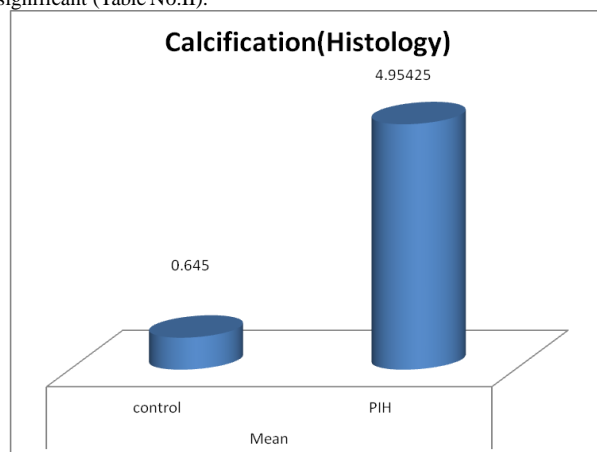
Vp CA : volume proportion of microscopic calcification

C : Control

E : Experiment

a) Volume proportion of microscopic calcification – (Table. No. I,II and Graph No 1):

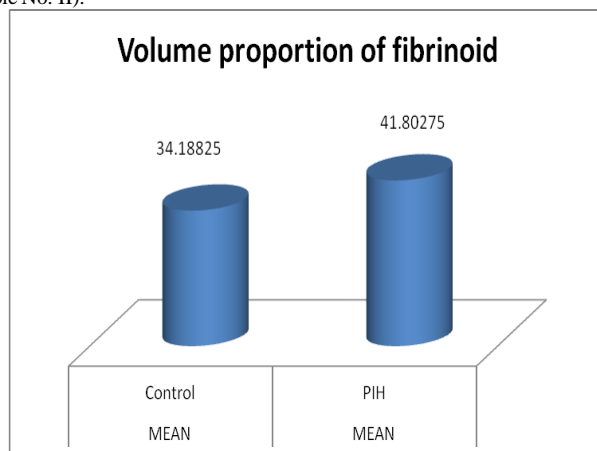
The control placenta were showing the mean volume proportion of calcification 0.645 and the figure in PIH placenta was 4.954. The increased calcification in PIH cases was statistically significant (Table No.II).



Graph No 1. Mean volume proportion of microscopic calcification of placenta of both groups (control and experiment)

b) Volume proportion of fibrinoid degeneration- (Table. No. I,II and Graph No:2

The average volume proportion of fibrinoid degeneration of control was 34.18825 and that of PIH was 41.80275. The lower values of PIH placenta were statistically significant (Table No. II).



Graph No:2. Mean volume proportion of fibrinoid degeneration in Placenta of both groups (control and experiment)

4. Discussion

There was evidence of fibrinoid material in control and experimental placental tissue. So we quantified the fibrinoid by taking the volume proportion of fibrinoid in whole placental tissue in both groups and found a significant increase in experimental group (Table No. I and II and Graph No.1.). SALEH and DKHIL (2008) observed large plaques of fibrin in intervillous space and on the syncytiotrophoblast (ST) covering of adjoining villi of the placenta of pre eclampsia⁸.

They stated that due to altered metabolism of syncytiotrophoblast and cytotrophoblast (CT) in hypoxic condition there was increased fibrinoid degeneration around villi. Udainia *et al* (2004) and Majumdar S *et al* (2005) also reported the predominance of the areas of fibrinoid degeneration in PIH placenta^{9 and 10}.

The basic hypothesis that the changes occurring in the villi were compensatory to hypoxic condition induced by PIH was supported by an increase in surface area of the terminal villi. Though the weight, volume, diameter and central thickness of experimental group of placenta was reduced and there was much more increased fibrinoid material in such placenta the trophoblastic cell proliferation and increase of villous diameter compensated these to some extent. This allowed greater exchange of materials from intervillous space to foetal blood vessels of the villi through syncytiotrophoblast (ST). Zacutti (1992) opined that mosaicism of the placenta probably led to placental insufficiency and ultimately to foetal growth retardation, thus creating a vicious cycle¹¹.

Our gross finding of calcification in placenta was confirmed by microscopy. The calcified areas were more evident in experimental cases. Calcification could be seen in even those placenta where there was no evidence of calcification in gross examination. We found a statistically significant increase of calcification in experimental group of placenta (Table No. II and Graph 2).

On histochemical study Mangal *et al* (2005) had proved that in PIH cases the placental Alkaline Phosphatase synthesis was increased by syncytiotrophoblast. Presence of this enzyme is clearly implicated in those areas where active calcium deposition has to occur. Hence our finding of increased calcification supports the result of Mangal *et al* (2005)¹².

5. Conclusions

The present study suggests that the gestational hypertension does cause structural and micro-structural changes in placenta which are negatively affecting the mass and surface area of placenta along with microscopic changes reactionary and compensating the hypoxia.

References

1. Boyd J D and Hamilton W J. Trophoblasts In: The Human Placenta 1970; (Mc Milan Press LTD): pp 140-167.
2. Sadler T W. Third Month to Birth: The Fetus and Placenta. In: Langman's Medical Embryology. 2009; 11th Edition (Lippincott William and Wilkins Publ.): pp 91-112.
3. Standring S. Implantation and Placentation. In: Gray's Anatomy the Anatomical Basis of Clinical Practice. 2008; 40th Edition (Churchill Livingstone Publ.): pp 175-182.
4. Ross M H and Pawlina W. Female Reproductive System. In: Histology A Text and Atlas with Correlated Cell and Molecular Biology. 2005; 5th Edition (Lippincott Williams and Wilkins Publ.): 796-827.
5. Ham Arthur W. Female Reproductive System. In: Histology. 1969; 6th Edition (J B Lippincott Company Igaku Shoin Ltd Philadelphia and Toronto): pp 907-919.
6. Cunningham F G, Hauth C J, Leveno J K, Gilstrap L, Bloom L S and Wenstrom D K. Hypertensive Disorders in Pregnancy In: Williams Obstetrics. 2005; 22nd edition (Mc Graw-Hill Medical Publishing Division) p: 761.
7. Lewis S H and Benirschke K. Placenta. In: Histology for Pathologists. Stacey E. Mills. 2007; 3rd Edition (Lippincott Williams and Wilkins Publ.): pp 1095-1126.
8. Reda Awadallah SALEH and Mohamed Abdel Monem DKHIL. Structural changes of placenta in preeclamptic patients (Light and Electron microscopy). *Turk Journal of Medical Sciences* 2008; 38(3):219-225.
9. Udainia A, Bhagwat S S and Mehta C D. Relation between Placental Surface Area, Infarction and Foetal Distress in Pregnancy Induced Hypertension with its Clinical Relevance. *Journal of the Anatomical Society of India* 2004; 53 (1): 27-30.
10. Majumdar S, Dasgupta H, Bhattacharya K, Bhattacharya A. A Study of Placenta In Normal and Hypertensive Pregnancies. *Journal of Anatomical Society of India* 2005; 54 (2) : 1-9.
11. Zacutti A, Borruto F, Bottacci G, Giannoni M L, Manzina and Pallini M, Umbilical blood flow and placental pathology Clinical experiment *Obstet Gynecol* 1992; 19(1):63-69.
12. Mangal A, Shrivastava P, Gaur U, Jain A, Goyal U and, Rath G. Histochemical Analysis of Placental Alkaline Phosphatase in Hypertensive Disorders complicating Pregnancy. *Journal of Anatomical Society of India* 2005; 54 (2):28-33.