

RESEARCH ARTICLE



A novel contiguous deletion involving *NDP*, *MAOB* and *EFHC2* gene in a patient with familial Norrie disease: bilateral blindness and leucocoria without other deficits

BEI JIA¹, LIPING HUANG¹, YAOYU CHEN², SIPING LIU¹, CUIHUA CHEN¹, KE XIONG³, LANLIN SONG¹, YULAI ZHOU², XINPING YANG^{4,5*} and MEI ZHONG^{1*}

¹ The Center for Prenatal and Hereditary Disease Diagnosis, Department of Obstetrics and Gynecology, Nanfang Hospital, Southern Medical University, Guangzhou 510515, People's Republic of China

² Department of Regeneration Medicine, School of Pharmaceutical Science, Jilin University, Changchun 130021, People's Republic of China

³ Department of Ophthalmology, ⁴ Center for Genetic and Developmental Systems Biology, and ⁵ Laboratory of Systems Neuroscience, Department of Obstetrics and Gynecology, Nanfang Hospital, Southern Medical University, Guangzhou 510515, People's Republic of China

*For correspondence. E-mail: Xinping Yang, yangxinping@smu.edu.cn; Mei Zhong, zhongmei@smu.edu.cn.

Received 15 November 2016; revised 25 March 2017; accepted 31 March 2017; published online 18 December 2017

Abstract. Contiguous microdeletions of the Norrie disease pseudoglioma (*NDP*) region on chromosome Xp11.3 have been widely confirmed as contributing to the typical clinical features of Norrie disease (ND). However, the precise relation between genotype and phenotype could vary. The contiguous deletion of *NDP* and its neighbouring genes, *MAOA/B* and *EFHC2*, reportedly leads to syndromic clinical features such as microcephaly, intellectual disability, and epilepsy. Here we report a novel contiguous microdeletion of the *NDP* region containing the *MAOB* and *EFHC2* genes, which causes eye defects but no cognitive disability. We detected a deletion of 494.6 kb at Xp11.3 in both the proband and carrier mother. This deletion was then used as the molecular marker in prenatal diagnosis for two subsequent pregnancies. The deletion was absent in one of the foetuses, who remain without any abnormalities at 2 years of age. The proband shows the typical ocular clinical features of ND including bilateral retinal detachment, microphthalmia, atrophic irides, corneal opacification, and cataracts, but no symptoms of microcephaly, intellectual disability, and epilepsy. This familial study demonstrates that a deficiency in one of two *MAO* genes may not lead to psychomotor delay, and deletion of *EFHC2* may not cause epilepsy. Our observations provide new information on the genotype–phenotype relations of *MAOA/B* and *EFHC2* genes involved in the contiguous deletions of ND.

Keywords. Norrie disease; *NDP* gene; *MAOB* gene; *EFHC2* gene; genomic microarray; contiguous deletion syndrome.

Introduction

Norrie disease (ND) is a rare, X-linked, recessive genetic disease (OMIM: 310600). It is a neurodevelopmental disorder mainly characterized by congenital blindness due to early proliferative deficiency and subsequent bilateral degenerative changes in neuroretina. The clinical ocular features of ND include retinal detachment, accumulation

of immature retinal cells, corneal opacities, cataracts, and atrophic irides. About half of ND patients with ocular signs have intellectual disability, and 75–90% of patients show progressive sensorineural hearing loss (Aponte *et al.* 2009; Nikopoulos *et al.* 2010; Pelcastre *et al.* 2010; Smith *et al.* 2012). These typical ND phenotypes are caused by mutations in Norrie disease pseudoglioma (*NDP*) gene (Chen *et al.* 1993). It encodes for the secreted cysteine-rich protein norrin, which in turn functions as a growth factor regulating retinal vascular development (Wang *et al.*

Bei Jia and Liping Huang contributed equally to this work.

2012; Zuercher *et al.* 2012; Deng *et al.* 2013). Norrin has a length of 133 residues, with a cysteine-knot domain spanning residue 32 to residue 133. The mutations that disrupt the cysteine-knot motif correspond to severe retinal dysgenesis, and noncysteine mutations can cause other *NDP*-related retinopathies (Wu *et al.* 2007). It was reported that the ND related mutations include point mutation in the coding region, intragenic deletion or inset, mutation of splicing site, deletion or insertion of CT repeat sequence in the 5' terminal noncoding region, and large fragment deletion of *NDP* gene (Smith *et al.* 2012). A previous report identified the phenotypes associated with a point mutation (L13R) in 46 affected members of a ND family: all had the ocular abnormalities of typical ND, 45% showed moderate or severe intellectual disability, and 78% had hearing loss occurring at different ages (Fuchs *et al.* 1994). Different contiguous deletions of the *NDP* gene and its neighbouring genes give rise to 'Norrie-plus syndromes' which show the typical clinical features of ND and various additional features. For example, patients harbouring deletions affecting *MAOA*, *MAOB*, and *NDP* genes display more severe neurological phenotypes, with profound psychomotor and verbal deficits (Gal *et al.* 1986; Donnai *et al.* 1988; Zhu *et al.* 1989; Berger *et al.* 1992; Collins *et al.* 1992; Chen *et al.* 1995; Schuback *et al.* 1995; Suarez-Merino *et al.* 2001; Staropoli *et al.* 2010). If contiguous deletions span genomic regions containing *MAOA*, *MAOB*, *NDP* and *EFHC2* genes, the clinical features reportedly include bilateral retinal detachment, severe psychomotor disability, and myoclonic epilepsy (Rodriguez-Revenga *et al.* 2007). Deletion of both *MAOA* and *MAOB* leads to severe psychomotor disabilities in patients (Sims *et al.* 1989; Rodriguez-Revenga *et al.* 2007; Whibley *et al.* 2010; Saito *et al.* 2014). Although patients with contiguous deletions spanning *EFHC2* and other genes show epilepsy (Suarez-Merino *et al.* 2001; Gu *et al.* 2005; Rodriguez-Revenga *et al.* 2007; Staropoli *et al.* 2010), there is no direct evidence to prove that deletion of *EFHC2* gene could lead to epilepsy. In addition, neurologic symptoms including intellectual disabilities, seizures, behaviour disturbances were not only displayed in patients with these contiguous gene deletions as described above, but also in patients and families with point mutations in *NDP* gene (Smith *et al.* 2012). Thus, the genotype-phenotype relation clearly varies in patients with Norrie-plus syndromes. In this report, we present a novel contiguous deletion of *MAOA*, *MAOB*, and *NDP* with affected family members displaying only ocular findings: bilateral blindness with leucocoria.

Materials and methods

Family status and clinical phenotype manifestations

The proband (figure 1, III-1) was the first child born to healthy parents at full-term (figure 1, II-2 and II-3) and

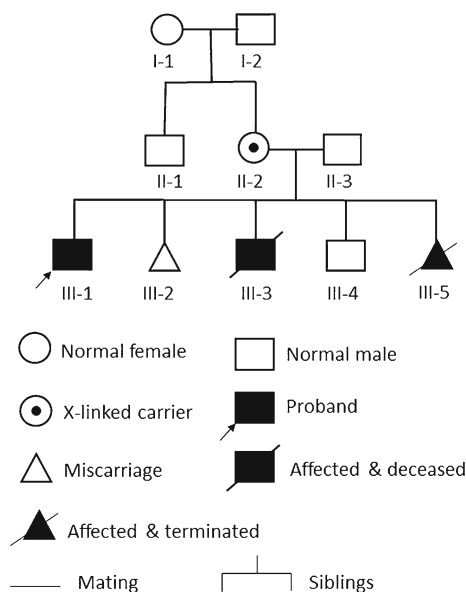


Figure 1. The pedigree with ND. The three-generation pedigree: III-1, proband; III-2, miscarriage; III-3, affected and died at 26th day; III-4, healthy male born after prenatal genetic diagnosis; III-5, male foetus harbouring the deletion terminated after genetic counselling; II-2, carrier mother; II-3, normal father.

the delivery was without incident. At birth, both the eyes of the proband obviously display congenital malformations and deformations (figure 2a). At five months of age, ophthalmological evaluation revealed bilateral retinal detachment, microphthalmia, corneal opacification, disappearance of the anterior chamber, atrophic irides, and cataracts. At the age of eight, the anterior-to-posterior diameter was 13.6 mm in the right eye and 13.4 mm in the left. Meanwhile, ophthalmic ultrasonography showed many bright spots in the vitreous body and a mass near the bottom of the optic disc in each eye, as well as high echo membranous ridge associated with the optic papilla, indicating double amotio retinae (figure 2b, data of left eye). The child showed clinical features of typical ND, with normal hearing, normal somatic growth and development, but without mental disability or epileptic seizures. The Wechsler Intelligence Scale for Children scale gave an intelligence quotient (IQ) of 107, and the Infants-Junior High School Students' Social Life ability test score was normal.

The second offspring of the couple (figure 1, III-2) was miscarried at 80 days of pregnancy. The third (III-3) was born at full term with an uncomplicated delivery, and the infant was blind at birth, with bilateral leucocoria, weak voice, and shortness of breath. Fiberoptic laryngoscopy revealed dysplasia of the laryngeal cartilage. Microphthalmia and vitreous hypertrophy with retinal detachment were detected by ophthalmic ultrasound. The child died of pulmonary bleeding caused by pneumonia at day 26 after birth. For the fourth and fifth foetuses, prenatal diagnosis was performed at Nanfang Hospital, Guangzhou.

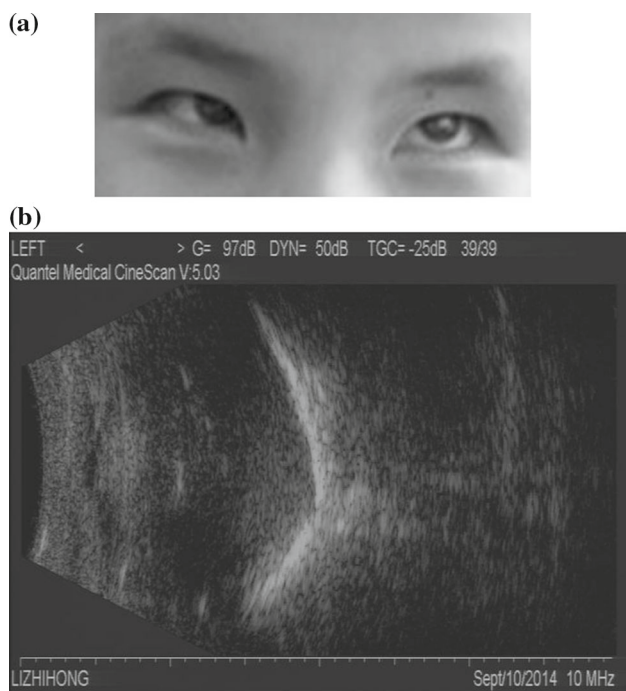


Figure 2. The Ophthalmic photograph and ultrasonogram of the proband. (a) Ophthalmic photograph of the proband. (b) Ophthalmic ultrasonography of the proband showing a shrunken eyeball, bright spots in the vitreous body, and a mass near the optic disc.

The fourth offspring (III-4) underwent genetic diagnosis at 24 weeks of pregnancy, and was diagnosed to be normal. He is currently healthy without ND. Recently, the couple presented with a fifth pregnancy (III-5). The prenatal diagnosis was carried out at 12 weeks of gestation and revealed the same genetic deletion as the proband. All participants gave written informed consent for the related information.

Single-nucleotide polymorphism (SNP) array and polymerase chain reaction (PCR)

Blood samples from the proband and the parents, 10 mL of amniotic fluid from the fourth offspring (centrifuged at 10,000 G for 2 min), and chorionic villi from the fifth offspring were collected for preparation of genomic DNA (gDNA). Extraction of the gDNA was carried out using the UltraClean BloodSpin DNA Isolation kit (MO BIO Laboratories, USA) and UltraClean Tissue & Cells DNA Isolation kit (MO BIO Laboratories, USA). PCR amplifications of exonic *NDP* regions were undertaken for molecular cytogenetic analysis. A SNP array, (HumanCytoSNP-12 DNA Analysis Bead-Chip Kit; Illumina, USA) was then used to screen for microdeletions of the X chromosome in the proband, parents, and fetuses. All testing was carried out according to the manufacturer instructions. Downstream data analysis was done using GenomeStudio software (Illumina).

The deletion was confirmed by quantitative-PCR (Q-PCR), with three pairs of primers located in *MAOB*, *NDP* and *EFHC2* genes, using the FastStart Universal SYBR Green Master kit (Roche, Basel, Switzerland) on the 7500 Real-Time PCR System (Applied Biosystems, Foster City, USA). The primer sequences for *EFHC2*-exon1: forward: 5'-CGTCTCCAGGCAACGTG-3'; reverse: 5'-CCTCCAGGAGAGTCTGCG-3'; the primer sequences for *MAOB*-exon1: forward: 5'-GAGGCCAGAA AACGGAG-3'; reverse: 5'-CCAGGCAGCCACCTGTC-3'; the primer sequences for *NDP*-exon2: forward: 5'-GGATCCTAGGAGGTGAAGCC-3'; reverse: 5'-TGGC TTCTTGCTGTTTCTG-3'.

Results

We carried out SNP array in the proband to look for microdeletions on the X-chromosome; we discovered a novel microdeletion of 494.6 kb on Xp11.3 (ChrX: 43721710-44216310). Loss of heterozygosity in this region was also detected in the proband's mother (figure 3a, II-2), but no deletion was detected at this region in amniotic fluid of the first sibling foetus (figure 3a, III-4). Looking into this region in the reference genome sequence (National Center for Biotechnology Information, human GRCh37/hg19), we found it encompasses three genes: *NDP*, *EFHC2* and the first exon of *MAOB* (figure 3b). We then performed q-PCR amplifications on *MAOB*, *NDP*, and *EFHC2* to confirm the contiguous deletion of the three genes in the proband (III-1) and in the carrier mother (figure 4, II-2), but not in the father (figure 4, II-3) or the fourth offspring (figure 4, III-4). The same microdeletion was detected in the chorionic villi of the fifth offspring (figure 3a, III-1 and III-5). Taken together, our results confirm that a microdeletion of 494.6 kb at Xp11.3 is the causal event for the phenotypes seen in this family with Norrie disease.

Discussion

Based on previous reports, the 'plus' clinical features of ND with contiguous deletions of *NDP*, *MAOA*, *MAOB*, and *EFHC2* include profound psychomotor disabilities, reduced somatic growth, delayed development, microcephaly, cardiovascular abnormalities, myoclonus, epileptic seizures, and immunodeficiency (Gal *et al.* 1986; Sims *et al.* 1989; Zhu *et al.* 1989; Chen *et al.* 1992; Collins *et al.* 1992; Schuback *et al.* 1995; Rodriguez-Revena *et al.* 2007). However, the genotype-phenotype relation has not been completely elucidated. Deletions in *NDP* gene are considered to be responsible for the typical clinical features of ND, while deletions in *MAOA* and *MAOB* together are responsible for the profound psychomotor disabilities seen with this disease (Sims *et al.* 1989; Zhu *et al.* 1989; Collins *et al.* 1992; Chen *et al.* 1995; Schuback *et al.* 1995; Suarez-Merino *et al.* 2001; Rodriguez-Revena *et al.* 2007;

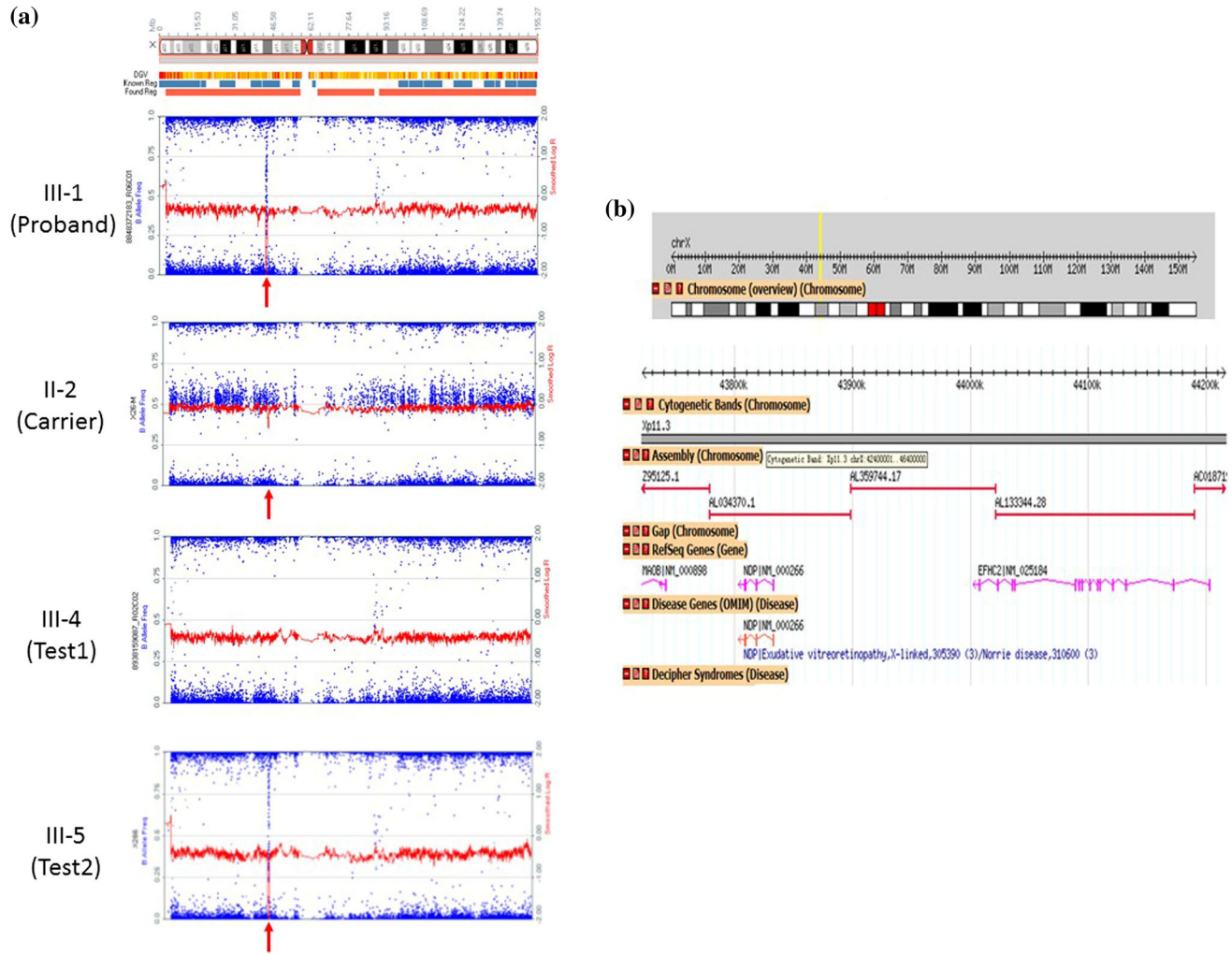


Figure 3. Prenatal genetic diagnosis for molecular cytogenetic variation. (a) Characterization of chromosome X in the proband, mother, and two foetuses by scanning copy-number variations through SNP array. The proband has a microdeletion of 494.6 kb at Xp11.3 (ChrX: 43721710-44216310; III-1, red arrow). The mother has a loss of heterozygosity at this region (II-2, red arrow). The foetus in the first genetic test (III-4, test 1) is normal, and the foetus in the second test (III-5, test 2) harbours the microdeletion. (b) Genomic region ChrX: 43721710-44216310. The deleted region is shown in red on the X chromosome (top). The *MAOB*, *NDP*, and *EFHC2* genes are shown in pink, with both introns and exons.

Staropoli et al. 2010; Saito et al. 2014). We found that our proband inherited a causal deletion of a region at Xp11.3 from his mother. This deletion contained *MAOB*, *NDP* and *EFHC2* genes, but not *MAOA*. Interestingly, the proband we report here shows the typical clinical features of ND, but none of the above ‘plus-features’ of the Norrie-plus syndromes. The clinical features of severe psychomotor disability and microcephaly are reportedly seen in all of the Norrie-plus syndromes that feature microdeletion of both *MAOA* and *MAOB* genes together with *NDP* gene (Gal et al. 1986; Donnai et al. 1988; Zhu et al. 1989; Collins et al. 1992; Chen et al. 1995; Schuback et al. 1995; Suarez-Merino et al. 2001; Rodriguez-Revilla et al. 2007; Staropoli et al. 2010). Nevertheless, the probands lack these clinical features, suggesting that the ‘plus-features’ are determined by the complementary roles of *MAOA*

and *MAOB*. This theory is also supported by a study of *MAOA/B* single-knockout and double-knockout mice (Bortolato et al. 2013). Lenders et al. (1996) observed borderline mental retardation and an abnormal behavioural phenotype in patients with selective *MAOA* deficiency and a severe mental retardation in patients with combined *MAOA* and *MAOB* deficiency and Norrie disease. In contrast, *MAOB*-deficient patients exhibit neither abnormal behaviour nor mental retardation (Lenders et al. 1996).

Notably, seizure is an atypical clinical feature of ND, with the microdeletion encompassing *NDP*, *MAOA*, *MAOB* and *EFHC2* (Rodriguez-Revilla et al. 2007). It has been suggested that the underlying causal event for seizure could be deletion of *EFHC2* gene, based on the knowledge of mutations of its homolog, *EFHC1*, in

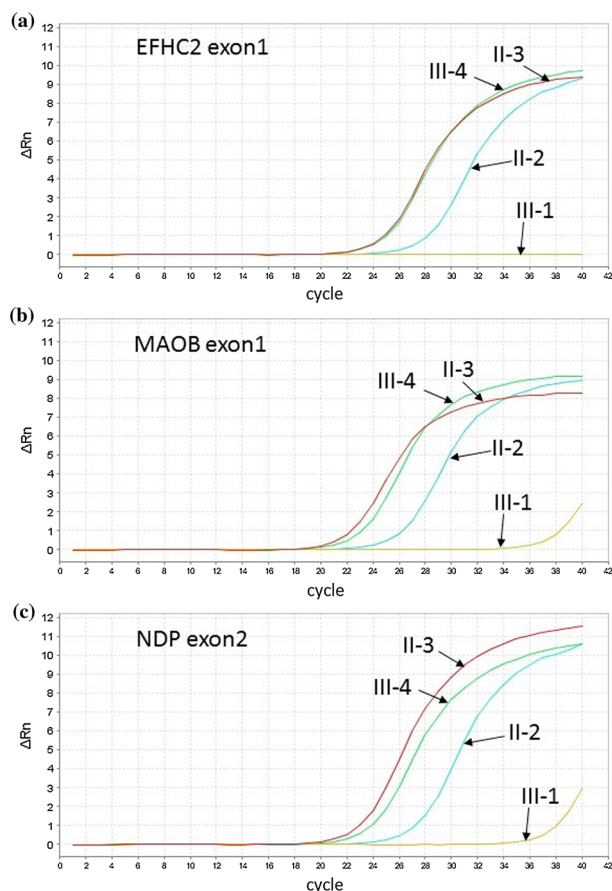


Figure 4. Validation of the microdeletion using q-PCR amplification. (a) *EFHC2* exon 1. (b) *MAOB* exon 1. (c) *NDP* exon 2. The arrows indicate the amplification curves on the DNA from II-2 (mother), II-3 (father), III-1 (proband) and III-4 (foetus).

epilepsy patients (Suzuki *et al.* 2004) and the association of an SNP in *EFHC2* with epilepsy (Gu *et al.* 2005). Gu and others reported a tentative relation between the S430Y polymorphism of *EFHC2* gene in patients suffering from juvenile myoclonic epilepsy, an idiopathic generalized epilepsy syndrome (IGE), and epilepsy. However, a recent study discovered that no relation between S430Y polymorphism in *EFHC2* gene and idiopathic generalized epilepsy present (Berrin *et al.* 2015). In our case, the proband did not have seizures, even though the deleted region contained the full-length *EFHC2* gene. The underlying mechanism of the finding requires further study.

In summary, this is the first observation that microdeletion of 494.6 kb at Xp11.3 (ChrX: 43721710-44216310) can result in ND phenotype. Based on the case of our observation, contiguous deletion with only one of the *MAO* genes (*MAOB*) may not cause psychomotor disability, and deletion of *EFHC2* may not contribute to epilepsy. This information could be helpful in fostering a deeper understanding of the phenotypic variants of microdeletional patients with ND. Further research should look closely into the genotype–phenotype relation.

Acknowledgements

We thank the family members who accepted to participate in this study. This work was supported by Science and Technology Programme of Guangdong Province (no. 2015B050501006), Chinese National Science Foundation (no. 81571097), The Ph.D. Start-up Fund of Natural Science Foundation of Guangdong Province (no. 2015A030310026), President Foundation of Nanfang Hospital, Southern Medical University (no. 2013C013, 2015Z004) and Academy Foundation of Nanfang Hospital, Southern Medical University (no. 2013018, 2013044).

References

- Aponte E. P., Pulido J. S., Ellison J. W., Quiram P. A. and Mohny B. G. 2009 A novel NDP mutation in an infant with unilateral persistent fetal vasculature and retinal vasculopathy. *Ophthalmic Genet.* **30**, 99–102.
- Berger W., Meindl A., van de Pol T. J., Cremers F. P., Ropers H. H., Doerner C. *et al.* 1992 Isolation of a candidate gene for Norrie disease by positional cloning. *Nat. Genet.* **1**, 199–203.
- Berrin T., Hikmet Y., Gülşen V., Ferda B., Erdal B. and Ece O. 2015 No relation between *EFHC2* gene polymorphism and idiopathic generalized epilepsy. *Afr. Health Sci.* **15**, 1204–1210.
- Bortolato M., Godar S. C., Alzghoul L., Zhang J., Darling R. D., Simpson K. L. *et al.* 2013 Monoamine oxidase A and A/B knockout mice display autistic-like features. *Int. J. Neuropsychopharmacol.* **16**, 869–888.
- Chen Z. Y., Sims K. B., Coleman M., Donnai D., Monaco A., Breakefield X. O. *et al.* 1992 Characterization of a YAC containing part or all of the Norrie disease locus. *Hum. Mol. Genet.* **1**, 161–164.
- Chen Z. Y., Battinelli E. M., Fielder A., Bunday S., Sims K., Breakefield X. O. and Craig I. W. 1993 A mutation in the Norrie disease gene (NDP) associated with X-linked familial exudative vitreoretinopathy. *Nat. Genet.* **5**, 180–183.
- Chen Z. Y., Denney R. M. and Breakefield X. O. 1995 Norrie disease and MAO genes: nearest neighbors. *Hum. Mol. Genet.* **4**, 1729–1737.
- Collins F. A., Murphy D. L., Reiss A. L., Sims K. B., Lewis J. G., Freund L. *et al.* 1992 Clinical, biochemical, and neuropsychiatric evaluation of a patient with a contiguous gene syndrome due to a microdeletion Xp11.3 including the Norrie disease locus and monoamine oxidase (MAOA and MAOB) genes. *Am. J. Med. Genet.* **42**, 127–134.
- Deng C., Reddy P., Cheng Y., Luo C. W., Hsiao C. L. and Hsueh A. J. 2013 Multi-functional norrin is a ligand for the LGR4 receptor. *J. Cell. Sci.* **126**, 2060–2080.
- Donnai D., Mountford R. C. and Read A. P. 1988 Norrie disease resulting from a gene deletion: clinical features and DNA studies. *J. Med. Genet.* **25**, 73–78.
- Fuchs S., Xu S. Y., Caballero M., Salcedo M., La O. A., Wedemann H. and Gal A. 1994 A missense point mutation (Leu13Arg) of the Norrie disease gene in a large Cuban kindred with Norrie disease. *Hum. Mol. Genet.* **3**, 655–656.
- Gal A., Wieringa B., Smeets D. F., Bleeker-Wagemakers L. and Ropers H. H. 1986 Submicroscopic interstitial deletion of the X chromosome explains a complex genetic syndrome dominated by Norrie disease. *Cytogenet. Cell Genet.* **42**, 219–224.
- Gu W., Sander T., Heils A., Lenzen K. P. and Steinlein O. K. 2005 A new EF-hand containing gene EFHC2 on Xp11.4: tentative evidence for association with juvenile myoclonic epilepsy. *Epilepsy Res.* **66**, 91–98.
- Lenders J. W., Eisenhofer G., Abeling N. G., Berger W., Murphy D. L., Konings C. H. *et al.* 1996 Specific genetic deficiencies

- of the A and B isoenzymes of monoamine oxidase are characterized by distinct neurochemical and clinical phenotypes. *J. Clin. Invest.* **97**, 1010–1019.
- Nikopoulos K., Venselaar H., Collin R. W., Riveiro-Alvarez R., Boonstra F. N., Hooymans J. M. *et al.* 2010 Overview of the mutation spectrum in familial exudative vitreoretinopathy and Norrie disease with identification of 21 novel variants in FZD4, LRP5, and NDP. *Hum. Mutat.* **31**, 656–666.
- Pelcastre E. L., Villanueva-Mendoza C. and Zenteno J. C. 2010 Novel and recurrent NDP gene mutations in familial cases of Norrie disease and X-linked exudative vitreoretinopathy. *Clin. Experiment. Ophthalmol.* **38**, 367–374.
- Rodriguez-Revenga L., Madrigal I., Alkhalidi L. S., Armengol L., Gonzalez E., Badenas C. *et al.* 2007 Contiguous deletion of the NDP, MAOA, MAOB, and EFHC2 genes in a patient with Norrie disease, severe psychomotor retardation and myoclonic epilepsy. *Am. J. Med. Genet. A* **143**, 916–920.
- Saito M., Yamagata T., Matsumoto A., Shiba Y., Nagashima M., Taniguchi S. *et al.* 2014 MAOA/B deletion syndrome in male siblings with severe developmental delay and sudden loss of muscle tonus. *Brain Dev.* **36**, 64–69.
- Schuback D. E., Chen Z. Y., Craig I. W., Breakefield X. O. and Sims K. B. 1995 Mutations in the Norrie disease gene. *Hum. Mutat.* **5**, 285–292.
- Sims K. B., de la Chapelle A., Norio R., Sankila E. M., Hsu Y. P., Rinehart W. B. *et al.* 1989 Monoamine oxidase deficiency in males with an X chromosome deletion. *Neuron* **2**, 1069–1076.
- Smith S. E., Mullen T. E., Graham D., Sims K. B. and Rehm H. L. 2012 Norrie disease: extraocular clinical manifestations in 56 patients. *Am. J. Med. Genet. A* **158**, 1909–1917.
- Staropoli J. F., Xin W. and Sims K. B. 2010 Co-segregation of Norrie disease and idiopathic pulmonary hypertension in a family with a microdeletion of the NDP region at Xp11.3-p11.4. *J. Med. Genet.* **47**, 786–790.
- Suarez-Merino B., Bye J., McDowall J., Ross M. and Craig I. W. 2001 Sequence analysis and transcript identification within 1.5 MB of DNA deleted together with the NDP and MAO genes in atypical Norrie disease patients presenting with a profound phenotype. *Hum. Mutat.* **17**, 523.
- Suzuki T., Delgado-Escueta A. V., Aguan K., Alonso M. E., Shi J., Hara Y. *et al.* 2004 Mutations in EFHC1 cause juvenile myoclonic epilepsy. *Nat. Genet.* **36**, 842–849.
- Wang Y., Rattner A., Zhou Y., Williams J., Smallwood P. M. and Nathans J. 2012 Norrin/Frizzled4 signaling in retinal vascular development and blood brain barrier plasticity. *Cell* **151**, 1332–1344.
- Whibley A., Urquhart J., Dore J., Willatt L., Parkin G., Gaunt L. *et al.* 2010 Deletion of MAOA and MAOB in a male patient causes severe developmental delay, intermittent hypotonia and stereotypical hand movements. *Eur. J. Hum. Genet.* **18**, 1095–1099.
- Wu W. C., Drenser K., Trese M., Capone Jr A. and Dailey W. 2007 Retinal phenotype-genotype correlation of pediatric patients expressing mutations in the Norrie disease gene. *Arch. Ophthalmol.* **125**, 225–230.
- Zhu D. P., Antonarakis S. E., Schmeckpeper B. J., Diergaarde P. J., Greb A. E. and Maumenee I. H. 1989 Microdeletion in the X-chromosome and prenatal diagnosis in a family with Norrie disease. *Am. J. Med. Genet.* **33**, 485–488.
- Zuercher J., Fritzsche M., Feil S., Mohn L. and Berger W. 2012 Norrin stimulates cell proliferation in the superficial retinal vascular plexus and is pivotal for the recruitment of mural cells. *Hum. Mol. Genet.* **21**, 2619–2630.

Corresponding editor: S. GANESH