

Original Article

Eight-year experience with the intraoperative frozen section examination of sentinel lymph node biopsy for breast cancer in a North-Italian university center

Carla Cedolini^{1*}, Serena Bertozzi^{1*}, Luca Seriau^{1*}, Ambrogio P Londero², Serena Concina¹, Federico Cattin¹, Onelio Geatti³, Carla Di Loreto⁴, Andrea Risaliti¹

¹Clinic of Surgery, University of Udine, Italy; ²Clinic of Obstetrics and Gynecology, University of Udine, Italy; ³Department of Nuclear Medicine, Az. Osp.-Univ. "Santa Maria della Misericordia", Udine, Italy; ⁴Institute of Pathology, University of Udine, Italy. *Equal contributors.

Received October 31, 2013; Accepted November 15, 2013; Epub December 15, 2013; Published January 1, 2014

Abstract: Sentinel lymph node biopsy (SLNB) completely changed the impact of breast surgery on patients psycho-physical wellness, reducing morbidity associated with complete axillary lymph node dissection (CALND) while granting an adequate breast cancer staging. We reviewed our experience with the SLNB in a University Clinic. We collected data about all breast cancer patients submitted to SLNB from 2002 to 2010, and analyzed them with R (version 2.15.2), considering significant $p < 0.05$. We performed 615 SLNBs on 607 patients, with a mean age of 59.86 (± 10.76). Sentinel node detection rate resulted 99.7%, with a mean number of biopsied nodes of 1.64 (± 0.67), axillary localization in 98% of cases, and negative intraoperative histological finding in the 86.2% of cases. Prevalence of ITCs, micrometastasis, macrometastasis and pericapsular metastasis resulted respectively 0.6%, 4.9%, 7.5% and 8.8%. Among women who received CALND, mean number of examined nodes was 16.36 (± 6.19) and mean number of metastatic non-sentinel nodes was 0.97 in case of micrometastasis, 2.65 in case of macrometastasis, and up to 9.88 when pericapsular invasion was described. To conclude, our data confirm the role of nodal metastasis size in the prediction of non-sentinel node involvement, but further studies are required in order to better assess the role of ITCs and micrometastasis in the diagnostic and therapeutic management of breast cancer, with the final aim to reduce the surgical complications of axilla demolition when unnecessary.

Keywords: Breast cancer, breast invasive cancer, sentinel lymph node biopsy, sentinel lymph node, micrometastasis

Introduction

Lymph node status, together with tumor size, represents one of the most important prognostic factors in breast cancer, and before the introduction of the sentinel lymph node biopsy (SLNB), in the absence of less invasive techniques, complete axillary lymph node dissection (CALND) represented a gold standard for breast cancer staging and treatment.

Since its routinely introduction in our population in 2002 and the increase of its prevalence with the spread of the organized mammographic screening in our region [1, 2], SLNB procedure progressively replaced unnecessary CALND in case of node-negative breast cancer

and completely changed the impact of axillary surgery on patients psycho-physical wellness, preventing the possible lymphatic complications associated with CALND while granting an adequate breast cancer staging [3].

Interestingly, even the management of node-positive disease has currently become argument of great debate, with the introduction of a new lymph node size-based metastasis classification [4, 5]. In particular, patients with sentinel node macrometastasis were observed to have a worse overall survival than those with micrometastasis or node-negative patients [6, 7], whereas the management of isolated tumor cells (ITCs) still remains controversial [8].

8-year experience with the sentinel lymph node

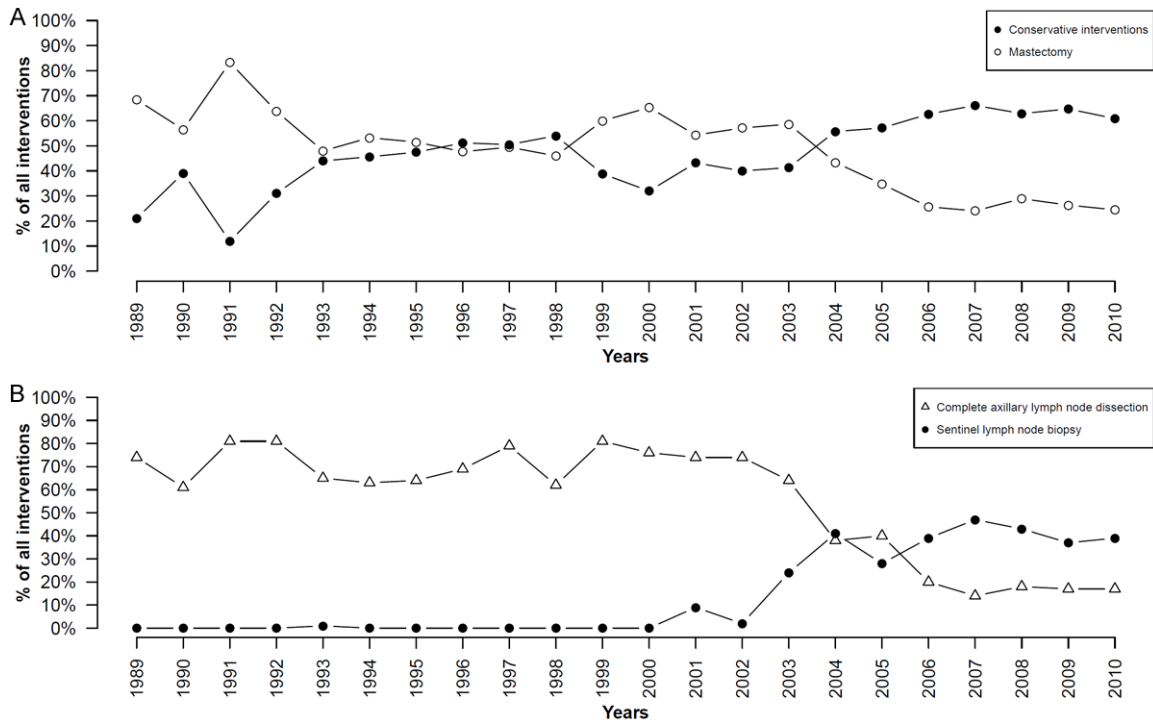


Figure 1. Prevalence of conservative and demolitive interventions on the breast (A) and of SLNBs and CALNDs (B) from 1989 to 2010.

In this study we reviewed the management and outcome of all SLNBs performed from 2002 to 2010 in our Clinic, in order to better clarify the correlation of quantitative and qualitative sentinel node involvement with non-sentinel node status, and the role of ITCs, micrometastasis, macrometastasis and perinodal extracapsular metastasis in the prediction of non-sentinel nodes neoplastic involvement.

Materials and methods

We collected data about all patients who underwent SLNB in our Clinic of Surgery between January 2002 and December 2010, focusing on cancer histotype, eventual multifocality (>1 neoplastic focus within the same breast quadrant) and multicentricity (>1 neoplastic focus located in different breast quadrants), cancer localization (breast side and quadrant), type of intervention on the breast (breast conservative surgery or mastectomy), excised sentinel nodes number, metastatic sentinel nodes number, sentinel lymph nodes localization (axilla or internal mammary chain or both). Among patients submitted to CALND, we considered also the definitive number of excised and posi-

tive nodes, and the prevalence of macrometastases (>2 mm), micrometastases (0.2-2 mm), ITCs (<0.2 mm), and perinodal extracapsular metastasis (defined as the presence of neoplastic cells in the perinodal axillary fat tissue).

All considered patients underwent subdermal injection of 2.5 ml of human serum albumin macroaggregate (particle size 0.1-0.8 mm) labeled with 74 mBq 99 m-technetium (mobile radiotracer) 3 to 24 hours before surgery. In case of non-palpable lesions, injection was performed in the peri-lesional area during the placement of wire hook by ultrasound or stereotactic mammography when appropriate; in case of palpable lesions, subdermal injection was performed directly on the peri-lesional area or around the areola; finally, in case of previous, surgical, diagnostic, excisional biopsy, injection was performed immediately under the recent scar. Then, routine control lymphoscintigraphy (in both the anterior and oblique projections) was performed 3 hours after radiotracer injection, and eventually repeated at 18 and 24 hours in case of doubtful or no apparent radiotracer uptake. In cases of difficult scintigraphic lymph node visualization, a fluorode-

8-year experience with the sentinel lymph node

Table 1. Breast cancer characteristics

	Absolute number (615)	Prevalence
Number of neoplastic foci		
Unifocal	582	94.60%
Multifocal	20	3.30%
Multicentric	13	2.10%
Breast side		
Left	335	54.50%
Right	280	45.50%
Breast quadrant		
Superior (upper-outer, upper-inner, between superiors)	335	54.50%
Inferior (inferior-inner, inferior-outer, between inferiors)	136	22.10%
External	80	13.00%
Central	64	10.40%
Histotype		
Non special type (ex invasive ductal carcinoma)	415	67.50%
Intraductal neoplasia	134	21.80%
Invasive lobular carcinoma	52	8.50%
Invasive ductal and lobular carcinoma	14	2.30%

Table 2. Sentinel and non-sentinel lymph nodes characteristics

	Absolute number (615)	Prevalence
Sentinel node location		
Axilla	603	98.05%
Axilla + Internal mammary chain	6	0.98%
Internal mammary chain	5	0.81%
Intramammary	1	0.16%
Number of biopsied sentinel nodes		
1	388	63.09%
2	187	30.41%
3	36	5.85%
4	2	0.33%
no sentinel node detected	2	0.33%
Intraoperative histological finding		
Negative for metastasis (NOi-)	526	85.53%
ITCs (NOi+)	4	0.65%
Micrometastasis (N1mi)	30	4.88%
Macrometastasis (N1)	46	7.48%
Pericapsular metastasis	8	1.30%
Secondary CALND		
Not performed	529	86.02%
Performed	86	13.98%
for metastatic sentinel node	84	13.66%
for identification failure of the sentinel node	2	0.33%

Intraoperative detection of the sentinel node was guided by a hand-held gamma probe and the complete removal of hot nodes was ensured by exclusion of any residual radioactivity on the resection bed before wound closure. Every SLNB was performed directly or under the supervision of the same breast specialist who operates in our Clinic. In case of multiple radioactive nodes, every node was biopsied with a radioactivity >10% of the most radioactive one [9], but the number of resected nodes was limited to three, as a greater number is not demonstrated to increase SLNB accuracy [10].

Every excised sentinel node was then submitted to intraoperative, histological examination of 20 hematoxylin-eosin-stained, 0.15 mm-sized, frozen sections, as well as to immunohistochemical evaluation of three random sections to search an eventual positivity for cytokeratins. Thereafter, sentinel lymph node definitive histological examination consisted in the accurate evaluation of 2-mm-spaced, hematoxylin-eosin-stained sections [11] and immunohistochemical evaluation of a random portion of the considered node for cytokeratins [12].

Secondary CALND was always performed under

oxyglucose-positron emission tomography-CT (FDG-PET-CT) scan was also acquired.

the same anesthesiologic time in case of sentinel node positivity for macrometastases or

Table 3. Lymph node metastasis characteristics in patients who underwent secondary CALND

	Absolute number (86)	Prevalence
Number of positive nodes / Number of biopsied sentinel nodes		
1 / 1	39	45.35%
2 / 2	13	15.12%
3 / 3	1	1.16%
1 / 2	22	25.58%
1 / 3	6	6.98%
2 / 3	3	3.49%
sentinel node not found	2	2.32%
Metastatic non-sentinel nodes after CALND		
0	47	54.70%
1	16	18.60%
2	8	9.30%
3 to 10	5	5.80%
>10	10	11.60%

micrometastases [13, 14], while ITCs did not receive further interventions [14, 15]. In case of neoplastic infiltration of an internal mammary chain sentinel node, CALND was also indicated. Follow up of patients who received CALND included yearly mammography and breast ultrasound examination, and that of patients who underwent only SLNB consisted in yearly breast mammography, breast and axillary ultrasound examination for the first 5 years after intervention.

Statistical analysis was performed using R (version 2.15.2) and considering significant $p < 0.05$. Univariate analysis was performed by t-test in case of continuous variables and chi-square test or Fisher exact test in case of categorical variables.

Results

During the study period we performed 615 SLNBs on 607 patients (8 cases of bilateral disease), with a mean age of 59.86 (± 10.76). For what concerns their intervention on the breast, 153 women underwent mastectomy (24.9%) and 462 quadrantectomy (75.1%), 73 of which associated with intra-operative radio-therapy (IORT) (11.8%). **Figure 1** shows the increasing trend of conservative breast surgery in our Clinic since 1989 (**Figure 1A**), accompanied by an increasing trend of SLNB prevalence with a consistent decrease of CALND prevalence (**Figure 1B**).

As expected, the most prevalent breast cancer histotype resulted the invasive ductal carcinoma (67.5%, 18.6% of which with extensive intraductal component), followed by the intraductal neoplasia (21.8%) (**Table 1**). Breast cancer was unifocal in 94.6% (582/615) of cases, multifocal in 3.3% (20/615) and multicentric in 2.1% (13/615). The most frequent location of neoplastic lesions was the left breast (54.5% vs 45.5%, $p < 0.05$), and

in particular the superior quadrants due to their greater parenchymal representation (54.5%, $p < 0.05$), followed by inferior quadrants (22.1%), external (13%) and central (10.4%) ones.

Sentinel node detection rate resulted 99.7%, and the two cases of failed sentinel node identification by SLNB received prophylactic CALND which resulted negative for lymph node metastasis. Mean number of biopsied nodes was 1.64 (± 0.67), being detected in the majority of cases only one lymph node (63.25%), and in 30.41% of cases two nodes (**Table 2**). Sentinel node was found in the homolateral axilla in 98% (603/615) of cases, whereas in 5 cases was detected among the internal mammary chain nodes, in 6 cases had a double location in the axilla and the internal mammary chain, and in only one case resulted from intramammaries.

SLNB resulted negative in the 86.2% of cases, among which four sentinel nodes presented ITCs (0.6%). On the other hand, SLNB was positive for macrometastasis or micrometastasis respectively in the 7.5% and 4.9% of cases, and pericapsular invasion was found in the 8.8% of patients. Then, 14% of patients underwent secondary CALND, mostly due to metastatic sentinel node, but also two prophylactic CALND were performed in case of identification failure of the sentinel node. No extra-axillary sentinel node resulted metastatic and consequently required CALND. Among women who received CALND,

Table 4. Non-sentinel lymph node characteristics in patients who underwent secondary CALND

	Cases	Negative NSNs	Positive NSNs	Mean positive NSNs*	Mean positive NSNs**	Median	Range
Micrometastasis	30	21	9	0.97	3.22	2	1-13
Macrometastasis	46	22	24	2.65	5.08	2	1-26
Pericapsular metastasis	8	2	6	9.88	13.17	14.5	1-22

NSN = non-sentinel node; *mean referred to the whole number of CALNDs; **mean referred to the number of CALNDs with metastatic non-sentinel nodes.

60 underwent conservative breast surgery (69.8%) and 20 radical mastectomy (30.2%). No woman undergoing CALND was offered intra-operative radio-therapy (IORT), due to our institutional policy for which sentinel node metastasis represent an absolute exclusion criteria for IORT.

Taking into consideration only women who received secondary CALND, mean number of excised sentinel nodes was 1.63 (± 0.70) and mean number of metastatic ones was 1.18 (± 0.47). In particular, in 53 cases (61.6%) all excised sentinel nodes were metastatic, while in 22 only half of them showed neoplastic infiltration (**Table 3**). By definitive histological examination, mean number of resected nodes was 16.36 (± 6.19) with a mean number of metastatic non-sentinel lymph nodes of 0.97 in case of micrometastasis by SLNB, 2.65 in case of macrometastasis, and up to 9.88 when pericapsular invasion was described (**Table 4**). Overall, 47 (54.7%) CALNDs excluded any other metastasis among non-sentinel lymph nodes, 16 (18.6%) found out one single non-sentinel metastatic node, but 10 (11.6%) revealed a massive metastatic involvement (>10) among non-sentinel nodes (**Table 3**).

Discussion

Sentinel node detection rate resulted 99.7%, with a mean number of biopsied nodes of 1.64 (± 0.67), axillary localization in 98% of cases, and negative intraoperative histological finding in the 86.2% of cases. Prevalence of ITCs, micrometastasis, macrometastasis and pericapsular metastasis resulted respectively 0.6%, 4.9%, 7.5% and 8.8%. Among women who received CALND, mean number of resected nodes was 16.36 (± 6.19) and mean number of metastatic non-sentinel nodes was 0.97 in case of micrometastasis, 2.65 in case of macrometastasis, and up to 9.88 when pericapsular invasion was described.

Since 2002, breast conservative surgery experienced in our Clinic a progressive increase with a consistent decrease of mastectomies, probably due to the more accurate preoperative staging, including also breast MRI for a better evaluation of disease extension and the research of eventual multifocality/multicentricity [16]. In the same period, an increase of SLNBs was also observed, with a first peak in 2002 after its routinely introduction and a second peak in 2007 after the spread of the organized mammographic screening in our region and the consequent numeric increase of early breast cancers [1, 2].

Sentinel node detection rate resulted 99.7%, and thus greater than values reported by the current literature [17, 18]. Among reasons of low SLN detection failure there was probably the routine use of general anesthesia less frequently associated with procedure failure than local anesthesia [17]. Furthermore, during the same intervention were always performed axilla and breast surgery. And in our opinion this is the result of the great multidisciplinary cooperation and technical competence achieved by our equipped in SLNB procedure. In particular, it is extremely important for us to correctly detect the sentinel lymph node at the beginning of every breast intervention, in order to have it quickly examined before completing breast demolition and, when required, reconstruction time, in the perspective of reducing both operative time and the number of interventions required.

Intraoperative histological examination of the sentinel node revealed micrometastasis in the 4.88% of cases and ITCs in 0.65%, being this last a very low prevalence if compared with other authors. In fact, the prevalence of micrometastasis and ITCs by SLNB varies in the literature respectively between 2% and 23% [2, 7, 13, 19-22] and between 8.9% and 10.6% [2, 19, 23]. And actually, frozen-section histologi-

cal examination is recognized to have a higher false negative rate [24], with a sensitivity of 83.3% for macrometastasis, 40% for micrometastasis, and only 18.2% for ITCs [25].

For what concerns the clinical significance of ITCs and micrometastasis, the size of lymph node metastasis is demonstrated to directly correlate with the probability of non-sentinel lymph node involvement, which is about 4 to 19% in case of ITCs [15, 23, 26, 27], 0 to 80% in case of micrometastasis [15, 23, 26, 27], and 46 to 80% in case of macrometastasis [23, 26]. In accordance with the most authors, we did not indicate CALND in case of ITCs [14, 15] and our four patients with ITCs are still disease-free at a median follow up of 47 months.

On the other hand, the literature is very controversial about the role of micrometastasis [13-15, 28-31]. In fact, Wasif and colleagues found out a 20.9% risk of upstaging of micrometastasis after CALND, with a prevalence of N1, N2 and N3 at the definitive histological examination of respectively 18.6%, 2.2% and 0.1% [13], but no significant difference was observed about 5-ys-OS between micrometastatic patients and node-negative ones [7, 20, 23]. In our population, micrometastatic sentinel nodes always indicated CALND with a positive non-sentinel node finding in the 30% of cases.

Along with the size of lymph node metastasis, also perinodal extracapsular metastatic invasion represents an important predictive factor for non-sentinel node metastasis [32-35]. And in our population, a mean of even 10 non-sentinel nodes resulted metastatic in case of sentinel node pericapsular invasion.

Prediction of non-sentinel node neoplastic involvement is becoming an always more important challenge, and many authors have tried to identify patients eligible for omitting CALND after positive SLNB and consequently to prevent in the future unnecessary CALND in patients at low-risk of axillary recurrence [36, 37]. In this perspective, the ACOSOG Z0011 and IBCSG 23-01 trials, which compared patients with positive sentinel node with or without consequent CALND, demonstrated no significant differences between the two groups in terms of both disease-free and overall survival [38]. In addition, the NSABBP B-04 trial demonstrated that metachronous CALND by

axillary recurrence after SLNB did not compromise overall survival in comparison with synchronous CALND by non-sentinel node involvement suspicion [19]. Moreover, some studies concluded that both whole-breast irradiation and systemic adjuvant treatment result comparable with CALND in case of small-volume lymph node metastasis [29, 30].

The weakness of our study is its retrospective design. On the other hand, its strength is the great number of SLNBs considered and the reliability of the procedure, which has been performed by the same team in the whole study period in a very well standardized manner.

In conclusion, further studies are required in order to better assess the role of ITCs and micrometastasis in the diagnostic and therapeutic management of breast cancer, with the final aim to reduce the surgical complications of axilla demolition when unnecessary, even considering that in the literature metachronous "salvage" CALND or more aggressive adjuvant treatments seem to be comparable with synchronous CALND in terms of overall survival.

Acknowledgements

This work was partly supported by University of Udine.

Disclosure of conflict of interest

None.

Address correspondence to: Dr. Carla Cedolini, Clinic of Surgery, University of Udine, p.le SSMM Misericordia 15, 33100 Udine, Italy. E-mail: dr.ber-tozzi@gmail.com; Ambrogio P Londero, Clinic of Obstetrics and Gynecology, University of Udine, Italy. E-mail: ambrogio.londero@gmail.com

References

- [1] Driul L, Bernardi S, Bertozzi S, Schiavon M, Londero AP, Petri R. New surgical trends in breast cancer treatment: conservative interventions and oncoplastic breast surgery. *Minerva Ginecol* 2013 Jun; 65: 289-296.
- [2] Bernardi S, Bertozzi S, Londero AP, Giacomuzzi F, Angione V, Dri C, Carbone A, Petri R. Nine years of Experience with the Sentinel Lymph Node Biopsy in a Single Italian Center: A Retrospective Analysis of 1,050 Cases. *World J Surg* 2012 Apr; 36: 714-722.
- [3] Dabakuyo TS, Fraisse J, Causeret S, Gouy S, Padeano MM, Loustalot C, Cuisenier J,

- Sauzedde JM, Smail M, Combier JP, Chevillote P, Rosburger C, Boulet S, Arveux P, Bonnetain F. A multicenter cohort study to compare quality of life in breast cancer patients according to sentinel lymph node biopsy or axillary lymph node dissection. *Ann Oncol* 2009 Aug; 20: 1352-1361.
- [4] Ollila D, Stitzenberg K. Breast cancer sentinel node metastases: histopathologic detection and clinical significance. *Cancer Control* 2001; 8: 407-414.
- [5] Riber-Hansen R, Nyengaard J, Hamilton-Dutoit S, Steiniche T. Stage migration after minor changes in histologic estimation of tumor burden in sentinel lymph nodes: the protocol trap. *Cancer* 2009; 15: 2177-2187.
- [6] Huvos A, Hutter R, Berg J, Hutter R. *Ann Surg* 1971; 1: 672-679.
- [7] Chen SL, Hoehne FM, Giuliano AE. The prognostic significance of micrometastases in breast cancer: a SEER population-based analysis. *Ann Surg Oncol* 2007 Dec; 14: 3378-3384.
- [8] Leidenius MHK, Vironen JH, Heikkilä PS, Joensuu H. Influence of isolated tumor cells in sentinel nodes on outcome in small, node-negative (pT1N0M0) breast cancer. *Ann Surg Oncol* 2010 Jan; 17: 254-262.
- [9] Lynch M, Jackson J, Kim J, Leeming R. Optimal number of radioactive sentinel lymph nodes to remove for accurate axillary staging of breast cancer. *Surgery* 2008; 144: 525-531.
- [10] Kidd S, Keto J, Tran H, Fitzgerald T. First three sentinel lymph nodes accurately stage the axilla in breast cancer. *Am Surg* 2009; 75: 253-256.
- [11] Viale G, Maiorano E, Mazzarol G, Zurrida S, Galimberti V, Luini A, Renne G, Pruneri G, Maisonneuve P, Veronesi U. Histologic detection and clinical implications of micrometastases in axillary sentinel lymph nodes for patients with breast carcinoma. *Cancer* 2001; 92: 1378-1384.
- [12] Giobuin S, Kavanagh D, Myers E, Doherty A, Quinn C, Crotty T, Evoy D, McDermott E. The significance of immunohistochemistry positivity in sentinel nodes which are negative on haematoxylin and eosin in breast cancer. *Eur J Surg Oncol* 2009; 35: 1257-1260.
- [13] Wasif N, Maggard MA, Ko CY, Giuliano AE. Underuse of axillary dissection for the management of sentinel node micrometastases in breast cancer. *Arch Surg* 2010; 145: 161-6.
- [14] Lyman GH, Giuliano AE, Somerfield MR, Benson AB 3rd, Bodurka DC, Burstein HJ, Cochran AJ, Cody HS 3rd, Edge SB, Galper S, Hayman JA, Kim TY, Perkins CL, Podoloff DA, Sivasubramanian VH, Turner RR, Wahl R, Weaver DL, Wolff AC, Winer EP; American Society of Clinical Oncology. American Society of Clinical Oncology guideline recommendations for sentinel lymph node biopsy in early-stage breast cancer. *J Clin Oncol* 2005; 23: 7703-20.
- [15] Joseph KA, El-Tamer M, Komenaka I, Troxel A, Ditkoff BA, Schnabel F. Predictors of nonsentinel node metastasis in patients with breast cancer after sentinel node metastasis. *Arch Surg* 2004 Jun; 139: 648-651.
- [16] Del Frate C, Borghese L, Cedolini C, Bestagno A, Puglisi F, Isola M, Soldano F, Bazzocchi M. Role of pre-surgical breast MRI in the management of invasive breast carcinoma. *Breast* 2007 Oct; 16: 469-481.
- [17] Bernardi S, Bertozzi S, Londero AP, Angione V, Petri R, Giacomuzzi F. Prevalence and risk factors of the intraoperative identification failure of the sentinel lymph node in patients affected by breast cancer. *Nucl Med Commun* 2013; 34: 664-673.
- [18] Straver ME, Meijnen P, van Tienhoven G, van de Velde CJH, Mansel RE, Bogaerts J, Duez N, Cataliotti L, Klinkenbijn JHG, Westenberg HA, van der Mijle H, Snoj M, Hurkmans C, Rutgers EJ. Sentinel node identification rate and nodal involvement in the EORTC 10981-22023 AMAROS trial. *Ann Surg Oncol* 2010 Jul; 17: 1854-1861.
- [19] Weaver D, Le U, Dupuis S. Metastasis detection in sentinel lymph nodes: comparison of a limited widely spaced (NSABP protocol B-32) and a comprehensive narrowly spaced paraffin block sectioning strategy. *Am J Surg Pathol* 2009; 33: 1583-9.
- [20] Gobardhan PD, Elias SG, Madsen EVE, Bongers V, Ruitenberg HJM, Perre CI, van Dalen T. Prognostic value of micrometastases in sentinel lymph nodes of patients with breast carcinoma: a cohort study. *Ann Oncol* 2009 Jan; 20: 41-48.
- [21] van der Heiden-van der Loo M, Bezemer PD, Hennipman A, Siesling S, van Diest PJ, Bongers V, Peeters PH. Introduction of sentinel node biopsy and stage migration of breast cancer. *Eur J Surg Oncol* 2006; 32: 710-14.
- [22] van Rijk MC, Peterse JL, Nieweg OE, Oldenburg HS, Rutgers EJ, Kroon BB. Additional axillary metastases and stage migration in breast cancer patients with micrometastases of submicrometastases in sentinel lymph nodes. *Cancer* 2006; 107: 467-71.
- [23] Hansen NM, Grube B, Ye X, Turner RR, Brenner RJ, Sim MS, Giuliano AE. Impact of micrometastases in the sentinel node of patients with invasive breast cancer. *J Clin Oncol* 2009 Oct; 27: 4679-4684.
- [24] Tille J, Egger J, Devillaz M, Vlastos G, Pelte F. Frozen section in axillary sentinel lymph nodes for diagnosis of breast cancer micrometastasis. *Anticancer Res* 2009; 29: 4711-4716.

- [25] Khalifa K, Pereira B, Thomas V, Mokbel K. The accuracy of intraoperative frozen section analysis of the sentinel lymph nodes during breast cancer surgery. *Int J Fertl Womens Med* 2004; 49: 208-211.
- [26] Kim T, Giuliano AE, Lyman GH. Lymphatic mapping and sentinel lymph node biopsy in early-stage breast carcinoma: a metaanalysis. *Cancer* 2006 Jan; 106: 4-16.
- [27] Noguchi M. Avoidance of axillary lymph node dissection in selected patients with node-positive breast cancer. *Eur J Surg Oncol* 2008 Feb; 34: 129-134.
- [28] Weaver DL. Pathology evaluation of sentinel lymph nodes in breast cancer: protocol recommendations and rationale. *Mod Pathol* 2010 May; 23 Suppl 2: S26-S32.
- [29] Pernas S, Gil M, Benítez A, Bajen MT, Climent F, Pla MJ, Benito E, Guma A, Gutierrez C, Pisa A, Urruticoechea A, Pérez J, Gil Gil M. Avoiding axillary treatment in sentinel lymph node micrometastases of breast cancer: a prospective analysis of axillary or distant recurrence. *Ann Surg Oncol* 2010 Mar; 17: 772-777.
- [30] Reed J, Rosman M, Verbanac KM, Mannie A, Cheng Z, Tafra L. Prognostic implications of isolated tumor cells and micrometastases in sentinel nodes of patients with invasive breast cancer: 10-year analysis of patients enrolled in the prospective East Carolina University/Anne Arundel Medical Center Sentinel Node Multi-center Study. *J Am Coll Surg* 2009 Mar; 208: 333-340.
- [31] Rutledge H, Davis J, Chiu R, Cibull M, Brill Y, McGrath P, Samayoa L. Sentinel node micrometastasis in breast carcinoma may not be an indication for complete axillary dissection. *Mod Pathol* 2005 Jun; 18: 762-768.
- [32] Yegiyants S, Romero LM, Haigh PI, DiFronzo LA. Completion axillary lymph node dissection not required for regional control in patients with breast cancer who have micrometastases in a sentinel node. *Arch Surg* 2010 Jun; 145: 564-569.
- [33] Cserni G, Burzykowski T, Vinh-Hung V, Kocsis L, Boross G, Sinkó M, Tarján M, Bori R, Rajtár M, Tekle E, Maráz R, Baltás B, Svébis M. Axillary sentinel node and tumour-related factors associated with non-sentinel node involvement in breast cancer. *Jpn J Clin Oncol* 2004 Sep; 34: 519-524.
- [34] Degnim AC, Griffith KA, Sabel MS, Hayes DF, Cimmino VM, Diehl KM, Lucas PC, Snyder ML, Chang AE, Newman LA. Clinicopathologic features of metastasis in nonsentinel lymph nodes of breast carcinoma patients. *Cancer* 2003 Dec; 98: 2307-2315.
- [35] Van Zee KJ, Manasseh DME, Bevilacqua JLB, Boolbol SK, Fey JV, Tan LK, Borgen PI, Cody HS 3rd, Kattan MW. A nomogram for predicting the likelihood of additional nodal metastases in breast cancer patients with a positive sentinel node biopsy. *Ann Surg Oncol* 2003 Dec; 10: 1140-1151.
- [36] Delpech Y, Bricou A, Lousquy R, Hudry D, Jankowski C, Willecocq C, Thoury A, Loustalot C, Coutant C, Barranger E. The Exportability of the ACOSOG Z0011 Criteria for Omitting Axillary Lymph Node Dissection After Positive Sentinel Lymph Node Biopsy Findings: A Multi-center Study. *Ann Surg Oncol* 2013; 20: 2556-2561.
- [37] Galimberti V, Chifu C, Rodriguez Perez S, Veronesi P, Intra M, Botteri E, Mastropasqua M, Colleoni M, Luini A, Veronesi U. Positive axillary sentinel lymph node: is axillary dissection always necessary? *Breast* 2011 Oct; 20 Suppl 3: S96-S98.
- [38] Giuliano AE, McCall L, Beitsch P, Whitworth PW, Blumencranz P, Leitch AM, Saha S, Hunt KK, Morrow M, Ballman K. Locoregional recurrence after sentinel lymph node dissection with or without axillary dissection in patients with sentinel lymph node metastases: the American College of Surgeons Oncology Group Z0011 randomized trial. *Ann Surg* 2010 Sep; 252: 426-32; discussion 432-3.