

Case Report

Incidental finding of a giant asymptomatic right atrial tumor

Thomas Strecker¹, Abbas Agaimy², Peter Zelzer³, Michael Weyand¹, David Lukas Wachter²

¹Center of Cardiac Surgery, ²Institute of Pathology, ³Department of Cardiology, Friedrich-Alexander-University Erlangen-Nuremberg, Germany

Received May 3, 2014; Accepted June 24, 2014; Epub June 15, 2014; Published July 1, 2014

Abstract: Primary cardiac tumors are very rare, atrial myxoma being the most common benign tumor of the heart. They may present with a great variety of incidental asymptomatic masses to severe life-threatening cardiovascular complications necessitating emergency surgery. Here we report the diagnostic evaluation and successful surgical resection of such a giant cardiac tumor which was found on a routine medical check-up in a 62-year-old patient. Histology confirmed diagnosis of unusually huge myxoma. This article demonstrates it's necessary to include cardiac tumors in the differential diagnosis of subtle and non-specific cardiothoracic symptoms.

Keywords: Cardiac tumors, myxoma, echocardiography, surgery, pathology

Introduction

Primary cardiac tumors are very rare. Their frequency in old autopsy studies ranged from 0.001 to 0.03% [1, 2]. About three-fourths of cardiac tumors are benign, atrial myxoma being the most common benign tumor of the heart [1, 2]. They may present with a wide variety of incidental asymptomatic masses to severe life-threatening cardiovascular complications necessitating emergency surgery [3, 4]. Here we present the diagnostic evaluation and successful surgical resection of such a huge cardiac tumor which was found on a routine medical check-up in a 62-year-old patient. Histology confirmed diagnosis of unusually huge myxoma.

Case presentation

A 62-year-old Caucasian woman with an unclear right atrial (RA) mass was referred to our hospital for further diagnostic evaluation. The huge mass was incidentally detected by abdominal ultrasonography at a preventive medical check-up. The patient had been in her usual state of good health with only slightly progressive chest pain associated with mild occasional little dyspnea.

Physical examination upon admission to hospital was unremarkable. The patient presented a blood pressure of 120/60 mm Hg and a heart rate of 60 beats per minute. Transthoracic echocardiography (TTE) revealed a large mobile right atrial mass (maximum diameter: 41 x 46 mm) within the lateral wall, but also involving parts of the inferior wall (**Figure 1A**). The TTE showed no impairment of either left or right ventricular systolic function. The heart valves appeared normal without significant signs of regurgitations or stenosis. Furthermore, selective coronary angiography was performed; there was only a minor, but not significant stenosis of the left anterior artery.

The patient was taken to the operating theatre, where a median sternotomy was performed and cardiopulmonary bypass was installed via aorto-bicaval cannulation with normothermia. After opening of the RA, the implantation of the tumor could be seen at the lateral wall, the tumor did not reach the tricuspid valve (**Figure 1B**). The large retractile, sessile tumor mass was successfully excised. The defect in the RA was directly closed. Subsequently, the patient was weaned from cardiopulmonary bypass without any signs of cardiac failure. The woman was extubated on the operating day and trans-

Giant right atrial tumor

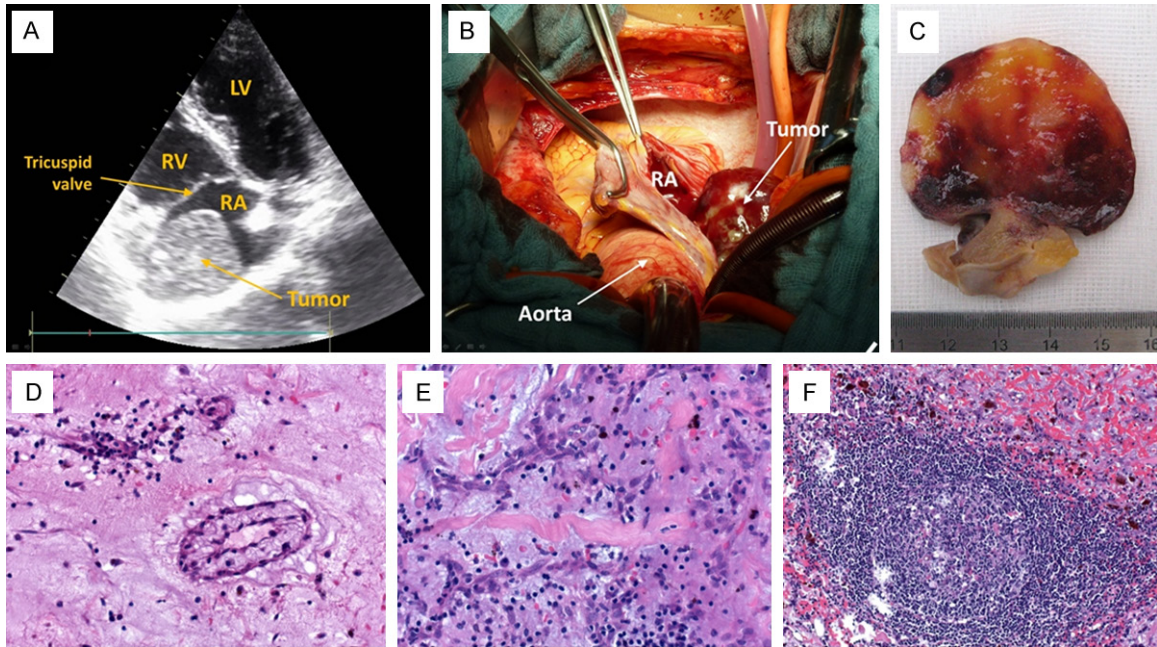


Figure 1. A: Transthoracic echocardiography revealed a large mobile mass (41 x 46 m) attached to the lateral wall of the right atrium. B: Intraoperative photograph showing the giant right atrial heterogeneous mass. The tumor also infiltrates parts of the inferior wall. C: Glistening cut surface of the tumor with predominantly deep red and sometimes pale yellow color. D: The tumor cells occasionally formed ring-like structures around primitive vessels. E: The macroscopically paler areas corresponded to heavily collagenized and inflamed stroma. F: Especially at the base of the tumor a prominent lymphofollicular reaction with admixed siderophages was seen.

ferred back to the regular care on postoperative day 2. Before leaving the hospital on day 14 after surgery, TTE showed a normal left and right ventricular function with an ejection fraction of 60%, well-functioning heart valves and no pericardial effusions.

Pathological findings

Macroscopically a 4.8 cm measuring, glistening, pedunculated and bosselated tumor attached to the atrial endocardium was seen. The cut surface of the tumor showed myxoid tissue with marked variation in color with predominantly deep red hemorrhagic areas admixed with pale yellow to white patches with focal calcifications (**Figure 1C**). Histologically the tumor consisted of a myxoid matrix in which spindled and sometimes stellate tumor cells without atypia were seen. The tumor cells sometimes formed ring-like structures around primitive vessels (**Figure 1D**). In some areas, the stroma was heavily collagenized (**Figure 1E**) and a prominent lymphofollicular reaction was evident at the periphery of the tumor (**Figure 1F**). Siderophages were also seen within stroma.

Discussion

The clinical symptoms of the various cardiac tumors are very often non-specific, and they usually present themselves insidiously that their diagnostic and surgical management is often delayed [5]. Reported symptoms include dyspnea, chest pain, syncope, arrhythmias and pericardial effusions with tamponade as well as intracardiac blood flow obstruction, peripheral embolization with systemic deficits or sudden death [5, 6]. Few cardiac tumors induce no symptoms and become evident as incidental [7].

The radiological evaluation of these cardiac neoplasms has been greatly facilitated by the development of noninvasive cardiac imaging [8, 9]. Echocardiography, CT and MRT are the most useful diagnostic tools in the assessment of cardiac tumors, which in almost all cases precisely locates the tumor and defines its extent and thus resectability [2]. In the majority of cases, cardiac tumors require operative excision to prevent potentially life-threatening complications; only a few cases may be unresect-

able because of their large size, and only tumor debulking may be possible in such cases [5].

Although the long-term prognosis of asymptomatic tumors is often good, fatal histories have been reported for untreated symptomatic tumors. Therefore, if a cardiac tumor is found to cause symptoms, indication for operation should be liberal [10].

In summary, this case illustrates nicely the uncommon presentation of a primary cardiac tumor (myxoma) that may achieve huge size, yet remaining almost asymptomatic. Thus it is mandatory to include cardiac tumors in the differential diagnosis of subtle and non-specific cardiothoracic symptoms.

Acknowledgements

We acknowledge support by Deutsche Forschungsgemeinschaft and Friedrich-Alexander-Universität Erlangen-Nürnberg (FAU) within the funding program Open Access Publishing.

Disclosure of conflict of interest

None.

Address correspondence to: Dr. Thomas Strecker, Center of Cardiac Surgery, Friedrich-Alexander-University Erlangen-Nuremberg, Krankenhausstraße 12, 91054 Erlangen, Germany. Tel: +49-9131-85-37023; Fax: +49-9131-85-32768; E-mail: thomas.strecker@uk-erlangen.de

References

- [1] Burke AP, Virmani R. Cardiac myxoma: A clinicopathologic study. *Am J Clin Pathol* 1993; 100: 671-80.
- [2] Agaimy A, Strecker T. Left atrial myxoma with papillary fibroelastoma-like features. *Int J Clin Exp Pathol* 2011; 4: 307-11.
- [3] Vaideeswar P, Gupta R, Mishra P, Lanjewar C, Raut A. Atypical cardiac myxomas: a clinicopathologic analysis and their comparison to 64 typical myxomas. *Cardiovasc Pathol* 2012; 21: 180-7.
- [4] Selkane C, Amahzoune B, Chavanis N, Raisky O, Robin J, Ninet J, Obadia JF. Changing management of cardiac myxoma based on a series of 40 cases with long-term follow-up. *Ann Thorac Surg* 2003; 76: 1935-8.
- [5] Strecker T, Röscher J, Weyand M, Agaimy A. Primary and metastatic cardiac tumors: imaging characteristics, surgical treatment, and histopathological spectrum: a 10-year-experience at a German heart center. *Cardiovasc Pathol* 2012; 21: 436-43.
- [6] Yang TY, Tsai JP, Chang CH, Kuo JY, Hung CL. Giant right atrial myxoma with pulmonary trunk dislodgement causing intermittent tricuspid obliteration and clinical manifestations of right heart failure. *Echocardiography* 2011; 28: E183-6.
- [7] Yuce M, Dagdelen S, Ergelen M, Eren N, Caglar N. A huge obstructive myxoma located in the right heart without causing any symptom. *Int J Cardiol* 2007; 114: 405-6.
- [8] Grebenc ML, Rosado de Christenson ML, Burke AP, Green CE, Galvin JR. Primary cardiac and pericardial neoplasms: radiologic-pathologic correlation. *Radiographics* 2000; 20: 1073-103.
- [9] Jellis C, Hunter A, Sutton R. Multimodal imaging of an atrial myxoma. *Cardiovasc Pathol* 2009; 18: 379-80.
- [10] Courtis J, Marani L, Amuchastegui LM, Rodeiro J. Cardiac lipoma: a rare cause of right-to-left interatrial shunt with normal pulmonary artery pressure. *J Am Soc Echocardiogr* 2004; 17: 1311-4.