

## Oral Carnosine Supplementation Prevents Vascular Damage in Experimental Diabetic Retinopathy

Frederick Pfister<sup>1\*</sup>, Eva Riedl<sup>1\*</sup>, Qian Wang<sup>1</sup>, Franziska vom Hagen<sup>1</sup>, Martina Deinzer<sup>2</sup>, Martin Conrad Harmsen<sup>3</sup>, Grietje Molema<sup>3</sup>, Benito Yard<sup>1</sup>, Yuxi Feng<sup>1</sup> and Hans-Peter Hammes<sup>1</sup>

<sup>1</sup>5th Medical Department, University Medicine Mannheim, University of Heidelberg, Mannheim, <sup>2</sup>Institute of Clinical Chemistry, University Medicine Mannheim, University of Heidelberg, Mannheim, <sup>3</sup>Department of Pathology and Medical Biology, University Medical Center Groningen, University of Groningen, Groningen,

\*These authors equally contributed to the paper

### Key Words

Carnosine • Diabetic retinopathy • ROS • AGE • Ang-2 • Hsp-27 • Pericytes • Vasoregression • Neuroglia

### Abstract

**Backgrounds/Aims:** Pericyte loss, vasoregression and neuroglial activation are characteristic changes in incipient diabetic retinopathy. In this study, the effect of the antioxidant and antiglycating dipeptide carnosine was studied on the development of experimental diabetic retinopathy. **Materials/Methods:** STZ-induced diabetic Wistar rats were orally treated with carnosine (1g/kg body weight/day). Retinal vascular damage was assessed by quantitative morphometry. Retinal protein extracts were analyzed for markers of oxidative stress, AGE-formation, activation of the hexosamine pathway and changes in the expression of Ang-2, VEGF and heat shock proteins Hsp27 and HO-1. Glial cell activation was analyzed using Western blot analysis and immunofluorescence of GFAP expression and retinal neuronal damage was histologically examined. **Results:** Oral carnosine treatment prevented retinal vascular damage after 6 months of experimental hyperglycemia. The protection was not caused by ROS- or AGE-inhibition, but

associated with a significant induction of Hsp27 in activated glial cells and normalization of increased Ang-2 levels in diabetic retinas. A significant reduction of photoreceptors in retinas of carnosine treated animals was noted. **Conclusion:** Oral carnosine treatment protects retinal capillary cells in experimental diabetic retinopathy, independent of its biochemical function. The vasoprotective effect of carnosine might be mediated by the induction of protective Hsp27 in activated glial cells and normalization of hyperglycemia-induced Ang-2.

Copyright © 2011 S. Karger AG, Basel

### Introduction

Diabetic retinopathy (DR) is the most prevalent microvascular complication of diabetes and a leading cause of blindness in people at working age [1]. Incipient stages are characterized by progressive vasoregression, initiated by loss of retinal pericytes and endothelial degeneration. Resulting basement membrane tubes are free of cell nuclei and no longer perfused leading to focal tissue hypoxia [2]. Subsequent endothelial cell proliferation results in microaneurysm formation and hypercellularity of retinal vessels. In parallel, retinal capillaries show a break-

### KARGER

Fax +41 61 306 12 34  
E-Mail [karger@karger.ch](mailto:karger@karger.ch)  
[www.karger.com](http://www.karger.com)

© 2011 S. Karger AG, Basel  
1015-8987/11/0281-0125\$38.00/0

Accessible online at:  
[www.karger.com/cpb](http://www.karger.com/cpb)

Prof. Dr. med. Hans-Peter Hammes  
5th Medical Department, University Medicine Mannheim, University of Heidelberg,  
Theodor-Kutzer-Ufer 1-3, D-68167 Mannheim (Germany)  
Tel. +49-621-383-2663, Fax +49-621-383-2663  
E-Mail [hp.hammes@umm.de](mailto:hp.hammes@umm.de)

down of the blood-retinal-barrier [3, 4]. Resulting from increased mitochondrial oxidative stress, several downstream mechanisms have been proposed to mediate hyperglycemia-induced cell damage, including increased flux through the hexosamine pathway, activation of PKC-pathway and increased formation of AGEs [5]. Experimental inhibitors targeting these pathways have been tested in animals. Of note, some efficiently inhibited the formation of acellular capillaries as the most predictive retinal lesion whereas others were either not successful in preventing DR or work only in combination with other compounds [6-10].

Carnosine, a naturally occurring dipeptide primarily produced in skeletal muscle and the central nervous system acts as both, a scavenger of ROS and an inhibitor of AGE production [11, 12]. Carnosine is synthesized from  $\beta$ -alanine and histidine and is specifically degraded by serum-carnosinase (CN-1). Growing evidence suggests a role of the carnosine-carnosinase system in the pathogenesis of diabetic complications [13]. As recently demonstrated by Janssen et al., CN-1 is involved in the susceptibility of diabetic patients to develop diabetic nephropathy [14]. Patients with a genotype that determines low secretion efficiency and subsequent low enzyme activity in blood were protected from DN, suggesting a genetical determination of kidney protection in diabetic patients. Furthermore, the data indicate that the substrate of CN-1, carnosine might be beneficial in relation to diabetic complications. Experimentally, it has been demonstrated that carnosine reduces lipid oxidation in kidneys and inhibits glucose-induced proliferation of mesangial cell [15, 16]. Furthermore, accumulation of extracellular matrix and upregulation of profibrotic TGF- $\beta$  is preventable by carnosine in cultured human podocytes and mesangial cells, suggesting that carnosine is a protective factor in diabetic nephropathy [14]. Moreover, carnosine might also be involved in other diabetic complications. In diabetic db/db and Balb/ca mice, carnosine substitution improved glucose metabolism and in STZ-diabetic mice it delayed the onset of diabetic neuropathy [17, 18]. A protective potential of carnosine has been demonstrated in diabetic cataractogenesis. Carnosine eye drops protected from hyperglycemia-induced cataract formation in STZ-induced diabetic rats. Thus, it has been suggested that carnosine is a potent agent for therapy of senile cataracts and diabetic ocular complications [19, 20].

However, the therapeutic potential of carnosine in the treatment of DR has not been tested yet. Increased oxidative stress, based on hyperglycemia-induced mitochondrial overproduction of reactive oxygen species, has

been identified as the common denominator of vascular damage. Glial cell activation and neuronal cell death are implicated in the development of DR [3, 21, 22]. Carnosine is one of the most abundant antioxidants in the brain, and in the retina, it is present in retinal neurons and Mueller glia [23-27]. As the dipeptide inhibits the synthesis of microglial inflammatory and oxidative stress mediators, its implication in the prevention of neuronal apoptotic cell death is conceivable. As a further beneficial action, carnosine induces the expression of heat shock proteins in mucosal cells and protects against excitotoxic cell death independently of its effects on reactive oxygen species in brain neurons [28-31]. Hsps are upregulated in activated neuroglia of diabetic animals and Hsp-inducers such as bimoclolmol have demonstrated preventive effects in experimental diabetic neuropathy and in early retinal damage in diabetic animals [32, 33].

In the light of these data, it is conceivable that carnosine has protective potentials on DR. We assessed vascular damage, hyperglycemia-induced biochemical changes, changes in the expression of VEGF, Ang-2 and Hsp, glial cell activation and neuronal damage in retinas of STZ-induced diabetic rats with oral carnosine treatment.

## Materials and Methods

### *Animals, diabetes induction and carnosine treatment*

The care and experimental use of all animals in the study were in accordance with institutional guidelines and in compliance with the Association for Research in Vision and Ophthalmology (ARVO) statement. Male Wistar rats were purchased (Harlan Winkelmann GmbH, Borcheln, Germany) and housed in a 12h light/dark cycle with free access to food and drinking water. Animals were randomly divided into a non-diabetic (NC) and a diabetic group (DC). Rats of the diabetic group were rendered diabetic by i.v. injection of STZ, (45 mg/kg body weight diluted in citrate buffer, pH 4.5 (Roche, Mannheim, Germany)). Animals were considered diabetic if blood glucose levels remained over 250 mg/dl. Animals of the diabetic group were randomly selected to receive carnosine in the daily water (1 gram carnosine/kilogram body weight/day (Flamma S.p.a., Chignolo d'Isola, Italy)) beginning one week after diabetes induction. Blood glucose level and body weight were monitored regularly (ACCU Check Comfort, Nr.63877, Roche Diagnostics, Mannheim, Germany). Eyes of each individual animal of all groups were inspected for cataract formation by two independent investigators after 6 weeks, 3 months and 6 months of hyperglycemia. Lenticular opacity was graded macroscopically as clear or dense. After sacrifice at 2 weeks, 3 and 6 months of hyperglycemia, respectively, eyes were obtained from deeply anesthetized animals and immediately frozen at -80°C until further analysis or fixed in 4% formalin. Blood samples were col-

lected for the determination of glycosylated haemoglobin concentration by affinity chromatography at the end of the study (MicromatII™; Bio-Rad Laboratories GmbH, Munich, Germany). After two weeks of treatment, carnosine concentration in retinal tissue was measured fluorometrically by high-performance liquid chromatography (HPLC) as previously described [14,34].

#### *Retinal digest-preparations and quantitative retinal morphometry*

We performed quantitative retinal morphometry in retinal digest preparations to evaluate capillary endothelial cell and pericyte numbers. In brief, eyes were fixed in 4% formaldehyde for at least 1 day. Next, retinas were isolated and incubated in distilled water at 37°C for 30min. Then, retinas were treated with a digestion solution (3% trypsin dissolved in 0.2M Tris-HCL (pH7.4) solution for 2-3 hours at 37°C). After washing under a dissection microscope the isolated retinal vasculature was dried on glass slides and stained with periodic acid-Schiff reagent and Meyer's hematoxylin (1:2, Merck, Darmstadt, Germany). Endothelial cell and pericyte numbers were quantified in 10 randomly selected areas (magnification 400x) in a circular area of the middle third of 6 retinas per group, using an image analyzing system (CUE-2; Olympus Optical, Hamburg, Germany). Cell numbers were relativized to the retinal capillary area (numbers of cells per mm<sup>2</sup> of capillary area) of each quantified field by software (AnalySIS®, Soft Imaging System GmbH, Muenster, Germany).

#### *Biochemical changes, growth factors and heat-shock proteins*

Retinal proteins were extracted in a lysis buffer containing 125 mM NaCl, 10 mM EDTA, 25 mM Hepes, 10 mM Na<sub>3</sub>VO<sub>4</sub>, 0.5 % deoxycholic acid, 0.1 % SDS, 1% Triton-X-100 and a cocktail of protein inhibitors (Complete Mini tablets, Roche Diagnostics, USA). The lysates were homogenized by trituration with 20-, 22-, 25- and 27-gauge needles and insoluble material was removed by centrifugation at 10000 rpm/min for 10 minutes at 4° C. Supernatants were collected and protein concentrations were measured by Bradford assay (Bio-Rad Laboratories GmbH, Munich, Germany). Prior to separation on 10% SDS PAGE gel, protein extracts (10-30 µg) were boiled for 5min at 100° C in 5 % beta-mercaptoethanol containing Laemmli buffer (Bio-Rad Laboratories GmbH, Munich, Germany). After separation, proteins were electrophoretically transferred to a PVDF membrane (Roche, Mannheim, Germany) using a semi-dry blotting system at ~ 0.7 mA/cm<sup>2</sup> for 1.5hrs. Membranes were incubated with 5 % non-fat dry milk dissolved in TBS containing 0.1% Tween 20 (Sigma-Aldrich, Steinheim, Germany) for 1 h at room temperature to block unspecific binding and then incubated with primary antibodies overnight at 4°C: mouse monoclonal NT (0.8 µg/ml in TBS/T, ALX-804-204, Alexis® Biochemicals, Axxora Deutschland GmbH, Germany), MG-H1 (1:2000 in 5% milk in TBS/T, [35]), mouse monoclonal O-Linked N-Acetylglucosamine (1:2000 in 5% milk in TBS/T, ab2739, Abcam, Cambridge, UK), goat polyclonal Ang-2 (1:500 in TBS/T, sc-7017, Santa Cruz Biotechnology, Heidelberg, Germany), monoclonal anti-rat VEGF (1:250 in TBS/T, MAB564, R&D Sys-

tems, Wiesbaden, Germany), goat polyclonal Hsp27 (1:500 in 5% milk in TBS/T, sc-1048, Santa Cruz Biotechnology) and goat polyclonal GFAP (1:500 in 5% milk in TBS/T, sc-6170, Santa Cruz Biotechnology). The blots were incubated with appropriate horseradish peroxidase (HRP)-conjugated secondary antibody (DAKO Cytomation, Hamburg, Germany) diluted in 5% milk/TBS/Tween 20 solution for 1hr at room temperature. Antibody binding was visualized by enhanced chemiluminescence (Perkin Elmer, Boston, MA, USA). For loading control, membranes were stripped and re-probed with antibodies against GAPDH (GAPDH antibody – Loading Control, ab9484, Abcam). Intensity of specific bands was measured by densitometry using the ImageJ 1.36b software and means of the absolute values of each group were expressed relative to non-diabetic controls.

Levels of HO-1 in retinal lysates were measured by using ELISA kit systems (StressXpress HO-1 (Rat) ELISA kit, EKS-810A, Stressgen Bioreagents, Kampenhout, Belgium). For the ELISA, half frozen retinas were homogenized by trituration in 150 µl PBS. The homogenates were frozen at -20 °C over night and after centrifugation at 10000 rpm/min, the supernatant was collected and protein concentration was measured by Bradford assay (Bio-Rad Laboratories GmbH, Munich, Germany). Retinal lysates were further diluted 1:5 and directly used in the ELISA according to manufacturer's instructions. Recombinant rat HO-1 served as standard and the absorbance of all samples were analyzed in duplicate at 450 nm wavelength with a microplate reader.

#### *Immunofluorescence staining of GFAP and Hsp27*

3 micrometer paraffin sections were deparaffinized, rehydrated, microwaved (2x 5min at 500 Watt (W) and 2x 5min at 270 W) in citrate buffer (Glycerolgelatine and Di-sodium hydrogen phosphate dihydrate), and then treated with 1 % BSA and 0.5 % Triton-100 in PBS for 30min at room temperature. Subsequently, sections were incubated with rabbit anti GFAP (sc-6170, Santa Cruz biotechnology, Inc., Heidelberg, Germany) at a concentration of 1:200 in PBS (DAKO Cytomation, Hamburg, Germany) at 4°C overnight. After washing in PBS, sections were incubated with swine anti rabbit secondary antibody conjugated with TRITC at room temperature for 1 hour (DAKO Cytomation). For double staining, sections were further treated with antibodies against Hsp27 over night at 4°C (1:50 in PBS, sc-1048, Santa Cruz Biotechnology, Heidelberg, Germany), followed by appropriate secondary FITC-coupled antibodies (Dako Cytomation). After washes, sections were covered with 50 % glycerol and stainings were visualized with a fluorescence microscope (Leica Microsystems GmbH, Wetzlar, Germany).

#### *Histological examination of retinal paraffin sections*

Eyes fixed in 4% formalin over night were embedded in paraffin. 3-micrometer vertical sections around optic nerves were selected to be dewaxed and rehydrated, then stained with Periodic Acid Schiff's (PAS) and hematoxylin according to standard histological staining protocols. Analysis of number of cells in retinal nuclear layers was performed at the inner border of peripheral 1/3 retina by using a microscope (Leica

DM RBE, Bensheim, Germany) equipped with an analysis program (Leica IM50, Herrbrugg, Switzerland). Four images of each retina were taken for cell number quantification of the ganglion cell layer (GCL), inner nuclear layer (INL) and outer nuclear layer (ONL) at 200x magnification and number of cells were counted in an area of 100 micrometer retina length in GCL and 50 micrometer in INL and ONL.

#### Statistical analysis

All data are expressed as mean  $\pm$  SD. Data were evaluated by analysis of variance (ANOVA) with Tukey's posttests to show differences between the groups. A p-value less than 0.05 was considered as statistical significant.

## Results

### *Oral carnosine treatment did not affect the development of experimental hyperglycemia but increased retinal carnosine content in diabetic rats*

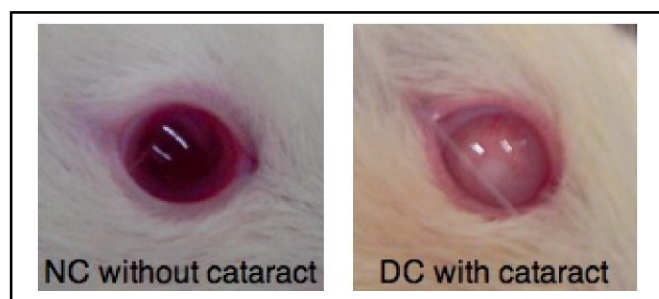
STZ-diabetic rats were orally treated with carnosine (1g/kg of body weight/day, DC+C) and metabolic parameters were compared to non-diabetic (NC) and diabetic rats without carnosine treatment (DC). STZ-induced diabetes led to stably elevated blood glucose levels and significantly reduced retinal carnosine content in DC (-31%,  $p < 0.05$  compared to NC), two weeks after diabetes induction (Table 1). In DC+C, retinal carnosine content was increased by 73% when compared to NC ( $p < 0.05$ ) and over 1.5-fold in comparison to DC ( $p < 0.05$ ). Carnosine treatment neither affected the onset or the progression of STZ-induced hyperglycemia, nor the cessation of body weight development observed in DC. As summarized in Table 1, final body weights were significantly reduced in DC and DC+C at 3 and 6 months of hyperglycemia and blood glucose levels and HbA1c were significantly elevated in both diabetic groups. Carnosine treatment had no effect on metabolic control as body weights, final blood glucose levels and HbA1c did not differ between DC and DC+C (Tab. 1).

### *Oral carnosine treatment delayed cataract formation in diabetic animals*

Topical application of carnosine eye drops in the treatment of senile and diabetic cataract is currently under investigation. In this study, diabetic rats were treated systemically by oral carnosine intake and the formation of cataract was monitored. DC started to develop cataract after 1 month of hyperglycemia (Fig. 1). After 3 months of treatment, 31% of eyes of DC displayed cataract formation (10/32 lenses,  $p < 0.05$  compared to NC).

	NC (n=9-20)	DC (n=8-26)	DC+C (n=7-21)
Body weights (g)			
3 months	470.0 $\pm$ 32.8	296.3 $\pm$ 35.0 *	308.2 $\pm$ 39.0 *
6 months	521.7 $\pm$ 45.8	292.0 $\pm$ 32.9 *	333.0 $\pm$ 30.5 *
Glucose level (mg/dl)			
3 months	6.1 $\pm$ 1.8	32.8 $\pm$ 1.1 *	33.1 $\pm$ 0.7 *
6 months	5.8 $\pm$ 1.0	33.0 $\pm$ 0.8 *	32.4 $\pm$ 2.5 *
HbA1c (%)			
3 months	5.9 $\pm$ 0.4	13.7 $\pm$ 4.0 *	11.2 $\pm$ 2.7 *
6 months	6.0 $\pm$ 0.4	15.4 $\pm$ 2.2 *	16.5 $\pm$ 1.7 *
Retinal Carnosine content ( $\mu$ mol) (n=4)	0.74 $\pm$ 0.17	0.51 $\pm$ 0.02 *	1.28 $\pm$ 0.57 * <sup>#</sup>

**Table 1.** Metabolic data and retinal carnosine content of non-diabetic (NC), diabetic (DC) and diabetic rats substituted with carnosine (DC+C). Carnosine treatment did not affect the development of experimental diabetes. Endogenous carnosine levels are reduced in diabetic retinas and oral carnosine treatment restored retinal carnosine content. \*= $p < 0.05$  compared to non-diabetics, #= $p < 0.05$  compared to diabetics. NC: non-diabetic, DC: diabetic, DC+C: diabetic with carnosine.

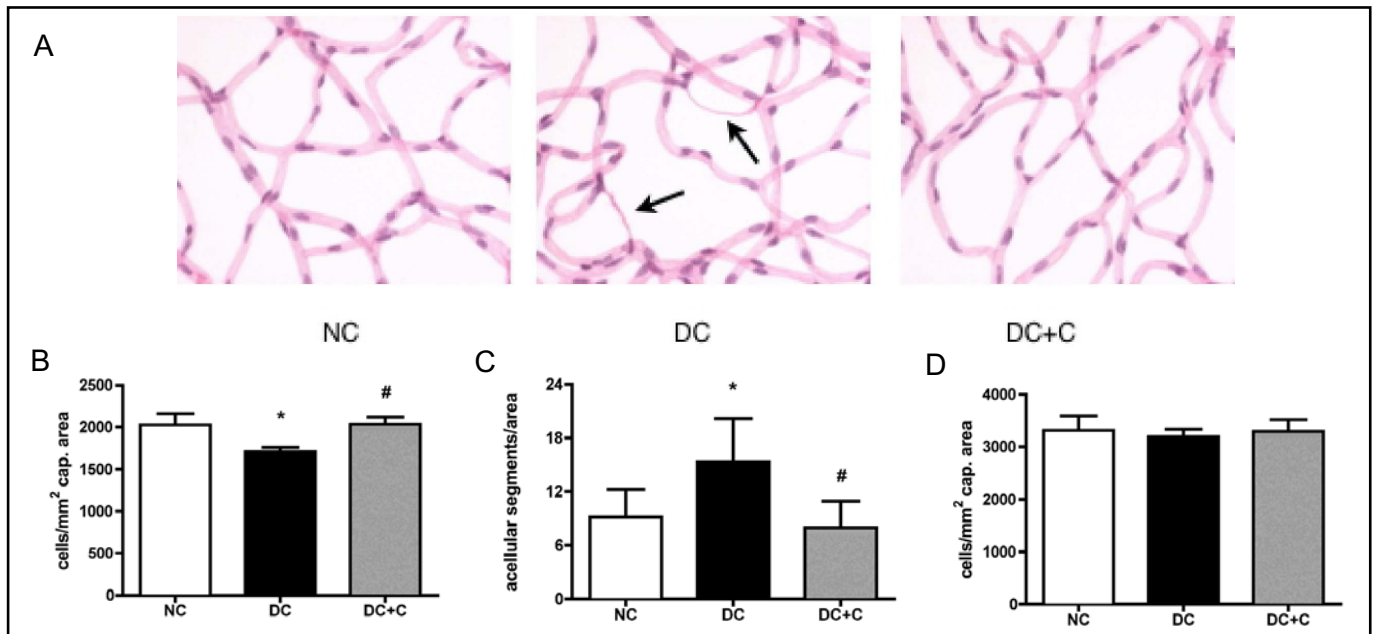


**Fig. 1.** Representative pictures of eyes of a non-diabetic (left picture) and a diabetic rat (right picture) 1.5 months after diabetes induction. Note clear lens of non-diabetic (NC) and opacity in lens of diabetic (DC) animals.

In contrast, lenses of DC+C were free of cataract formation (0/18 lenses affected by cataract formation,  $p < 0.05$  vs DC) after 3 months. At 6 months of diabetes duration, 93% of the lenses of DC (28/30 lenses,  $p < 0.05$  compared to NC) and 78% of the lenses of DC+C suffered from cataract formation (14/18,  $p < 0.05$  compared to NC, DC vs. DC+C not significant).

### *Carnosine treatment prevents vascular damage in diabetic retinas*

Pericyte loss and vasoregression are hallmarks of experimental DR. In our study, retinal pericyte numbers were reduced by 16 % (NC vs. DC: 2026  $\pm$  136 and 1707  $\pm$  50 cells per mm<sup>2</sup> of capillary area,  $p < 0.05$ , Fig.2B) and vasoregression profiles were increased by 66% (NC vs. DC: 9.2  $\pm$  3.1 and 15.3  $\pm$  4.8 acellular segments per retinal area,  $p < 0.05$ , Fig. 2A, C) in retinas of DC after 6 months. Carnosine treatment prevented both, loss of retinal pericytes (DC vs. DC+C: 1707  $\pm$  50 and 2031  $\pm$  91



**Fig. 2.** Quantitative retinal morphometry at 6 months of hyperglycemia. Pericyte numbers (B), numbers of vasoregression profiles (C) and endothelial cell numbers (D) were assessed in PAS-stained retinal digest preparations (A). Arrows in A indicate vasoregression profiles. We found significant loss of pericytes ( $p < 0.05$ ) and increased vasoregression profiles ( $p < 0.05$ ) in retinas of diabetic animals (DC) when compared to non-diabetic controls (NC). Carnosine treatment (DC+C) prevented hyperglycemia induced pericyte loss and vasoregression. Furthermore we found normal endothelial cells numbers in all studied groups, Data presented as mean  $\pm$  SD, \*= $p < 0.05$  compared to NC, #= $p < 0.05$  compared to DC.  $n = 6$  per group.

cells per mm<sup>2</sup> of capillary area,  $p < 0.05$ , NC vs. DC+C not significant, Fig. 2B) and hyperglycemia induced vasoregression (DC vs. DC+C:  $15.3 \pm 4.8$  and  $8.0 \pm 3.0$  acellular segments per retinal area,  $p < 0.05$ , NC vs. DC+C not significant, Fig. 2A, C). We found normal endothelial cell numbers in retinas of NC, DC and DC+C (NC:  $3317 \pm 268$ , DC:  $3198 \pm 142$  and DC+C:  $3299 \pm 217$  cells per mm<sup>2</sup> of capillary area, differences between groups not significant, Fig. 2D) after 6 months.

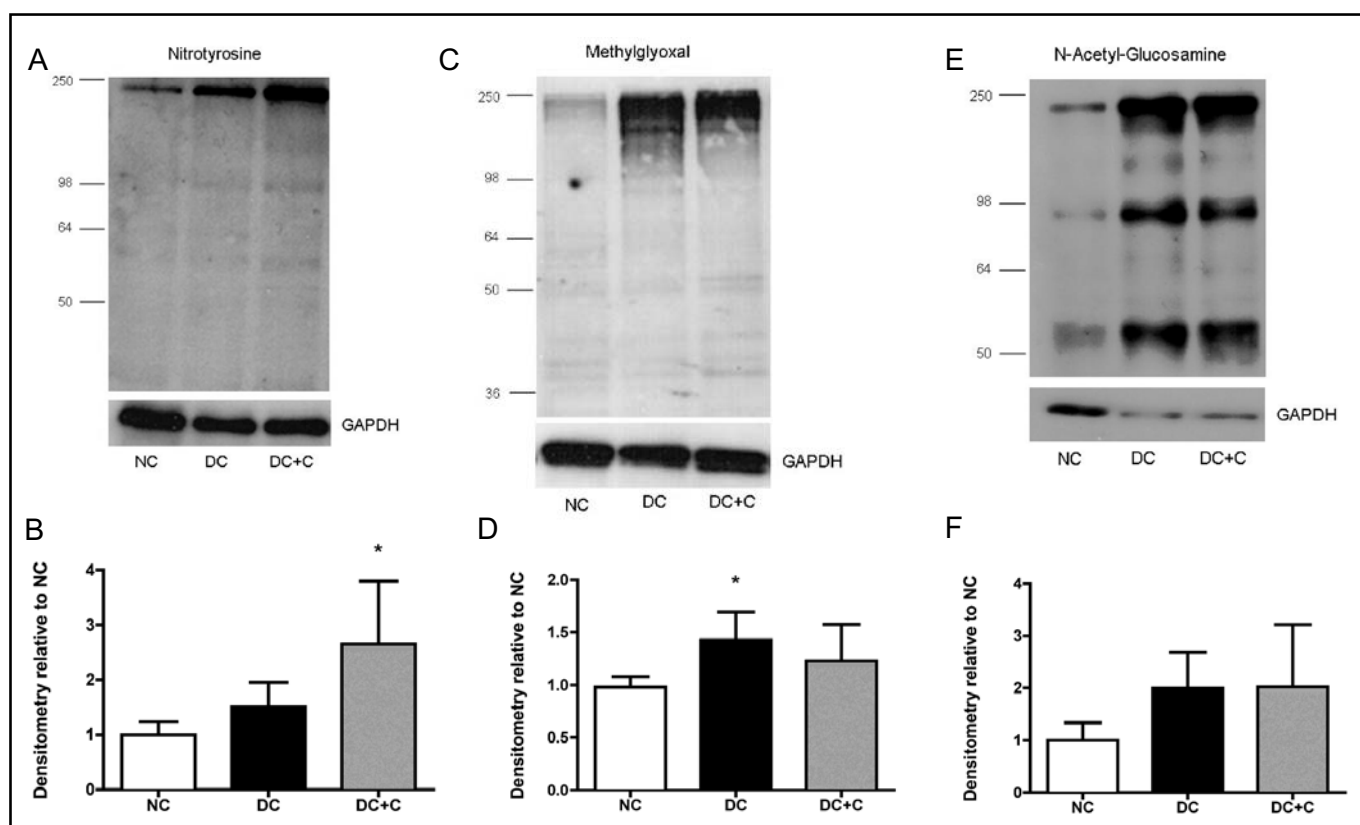
#### *Carnosine did not prevent biochemical changes in diabetic retinas*

To investigate whether carnosine treatment protected against oxidative stress in diabetic rat retinas, levels of nitrotyrosine (NT) were analysed in retinal lysates after 3 months of hyperglycemia. NT-modified proteins were insignificantly increased in retinas of DC when compared to NC (+51% compared to NC,  $p > 0.05$ , Fig. 3A, B) suggesting moderate increased nitrosative stress. In retinas of DC+C, NT levels were significantly elevated when compared to NC (+165% compared to NC,  $p < 0.05$ ), but did not differ between DC and DC+C (+75% compared to DC, DC vs. DC+C not significant, Fig. 3A, B). To evaluate the effect of carnosine on AGE production in diabetic retinas, we assessed levels of methylglyoxal (MG)-type AGEs in retinal protein extracts after 3 months

of hyperglycemia. MG levels were significantly increased in retinas of DC (+45% compared to NC,  $p < 0.05$ , Fig. 3C, D), but not in DC+C (+25% compared to NC,  $p > 0.05$ , Fig. 3C, D) and did not differ significantly between DC and DC+C (-14% compared to DC, DC vs. DC+C not significant, Fig. 3C, D). Furthermore, the effect of carnosine treatment on hyperglycemia-induced modification of retinal proteins by O-GlcNAc, as an indicator of hexosamine pathway activation was evaluated (Fig. 3E, F). Compared with retinas of NC, O-GlcNAc protein modification was increased by 100% in retinas of DC ( $p > 0.05$  compared to NC) and 102% in retinas of DC+C ( $p > 0.05$  compared to NC, DC vs. DC+C not significant).

#### *Carnosine treatment inhibited Ang-2 upregulation in diabetic retinas*

Chronic hyperglycemia modulates the expression of Ang-2 and VEGF, thereby inducing vascular damage in DR. In this study, we found no differences in the expression of Ang-2 in the studied groups at 3 months of hyperglycemia (differences between NC, DC and DC+C not significant, Fig. 4A, B). However, Ang-2 was significantly upregulated by 106% in retinas of DC after 6 months of hyperglycemia ( $p < 0.05$  compared to NC, Fig. 4C, D). Retinas of DC+C showed normalized Ang-2 levels after 6 months of experimental diabetes (-42% com-



**Fig. 3.** Representative examples (A, C, E) and quantification (B, D, F) of Western blots of nitrotyrosine (NT) as a marker of oxidative stress (A, B), methylglyoxal (MG)-type AGEs (C, D) and GlcNAc as a marker for hexosamine pathway activation (E, F). Retinal protein extracts of non-diabetic (NC), diabetic (DC) and diabetic rats treated with carnosine (DC+C) were analyzed after 3 months of hyperglycemia. In retinas of DC, levels of NT, MG and GlcNAc when compared to NC (\*  $p < 0.05$ ). Oral carnosine treatment had no effect on hyperglycemia-induced ROS-production, AGE-formation and activation of hexosamine pathway. Values were based on 4-6 different animals per group. Data presented as mean  $\pm$  SD, \* $p < 0.05$  compared to NC. GAPDH: protein loading control.

pared to DC,  $p > 0.05$ ; NC vs. DC+C not significant, Fig. 4C, D). Retinal VEGF levels were significant increase in retinas of DC compared to NC after 3 and 6 months (+127% and +78% compared to NC, respectively, both  $p < 0.05$  compared to NC, Fig. 4E-H). In retinas of DC+C, VEGF levels were increased by +47% compared to NC after 3 months of hyperglycemia (NC vs. DC+C and DC vs. DC+C not significant, Fig. 4E, F) and significantly elevated after 6 months (+96% NC vs. DC+C  $p < 0.05$ , Fig. 4G, H). After 6 months of hyperglycemia, we found no difference in VEGF expression between DC and DC+C (+10% compared to DC, DC vs. DC+C not significant, Fig. 4G, H).

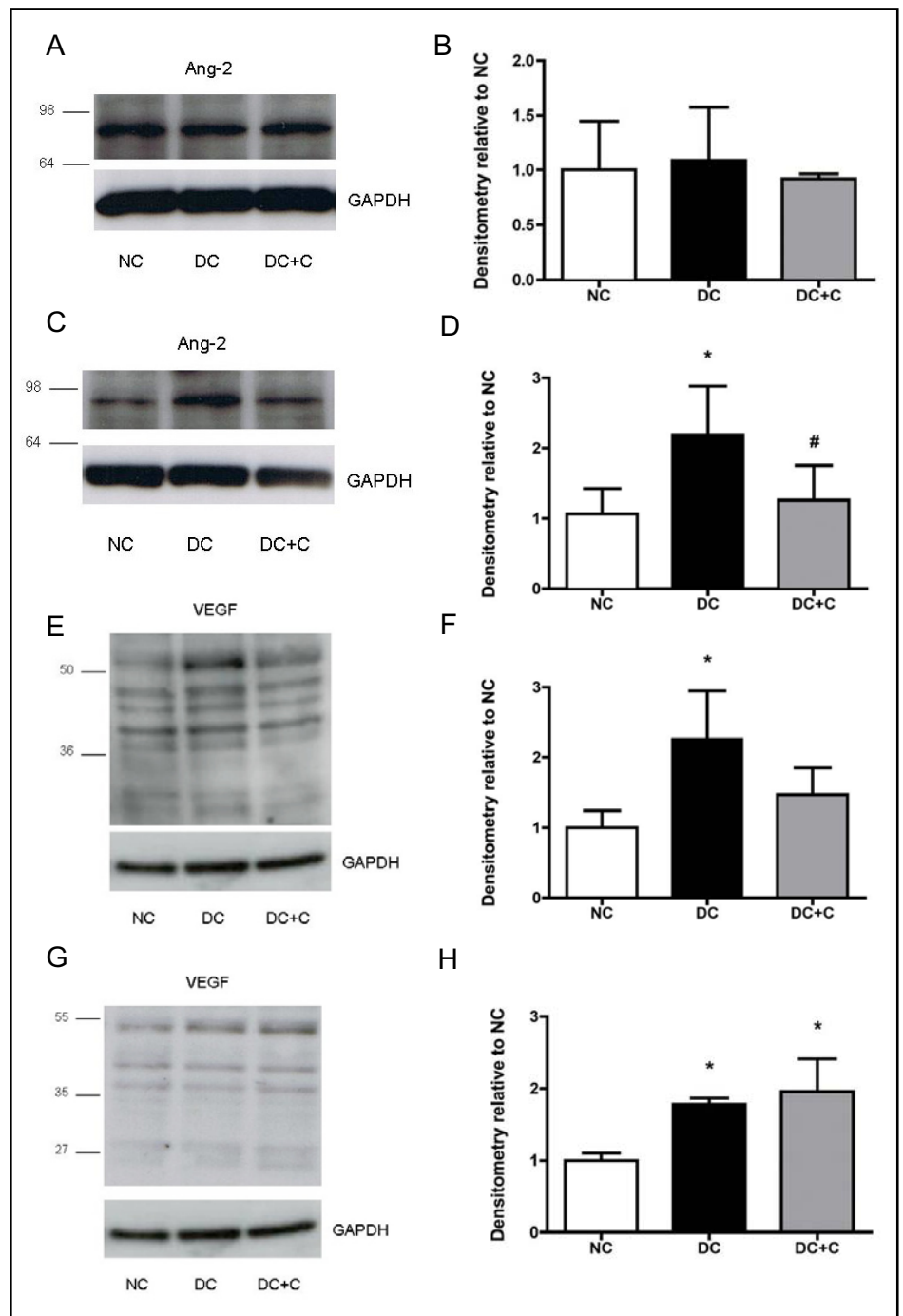
#### *Carnosine treatment induced retinal Hsp27 expression in diabetic retinas*

Carnosine treatment induces the expression of Hsp in other experimental models. Therefore, we investigated retinal protein expression levels of Hsp27 and HO-1 af-

ter 3 and 6 months. We found no changes in the expression of Hsp27 (+48% compared to NC, NC vs. DC not significant, Fig. 5A, B) and HO-1 (+90% compared to NC, NC: 0.28 ng/ml  $\pm$  0.17 and DC: 0.54 ng/ml  $\pm$  0.25, NC vs. DC not significant, Fig. 5C) in retinas of DC after 3 months of hyperglycemia. However, Hsp27 expression was significantly induced over 4-fold in retinas of DC+C when compared to NC ( $p < 0.05$  compared to NC, Fig. 5A, B) and by 257% in comparison to DC ( $p < 0.05$  compared to DC, Fig. 5A, B). In contrast, HO-1 expression was unaffected by carnosine treatment at 3 months of diabetes duration (+54% compared to NC, NC: 0.28 ng/ml  $\pm$  0.17 and DC+C: 0.43 ng/ml  $\pm$  0.19, NC vs. DC+C not significant, Fig. 5C) and no difference in HO-1 expression was observed between DC and DC+C (DC: 0.54 ng/ml  $\pm$  0.25 and DC+C: 0.43 ng/ml  $\pm$  0.19, DC vs. DC+C not significant, Fig. 5C) at this time point. After 6 months of hyperglycemia, expression of Hsp27 was increased by +360% ( $p < 0.05$  compared to NC, Fig. 5D, E)



**Fig. 4.** Representative examples (A, C, E, G) and quantification (B, D, F, H) of Western blots of Ang-2 (A-D) and VEGF (E-H). Retinal protein extracts of non-diabetic (NC), diabetic (DC) and diabetic rats treated with carnosine (DC+C) were analyzed after 3 months (A, B, E, F) and 6 months (C, D, G, H) of hyperglycemia. In retinas of DC, Ang-2 expression was upregulated after 6 months of hyperglycemia and VEGF levels were increased after 3 and 6 months. Carnosine treatment prevented upregulation of Ang-2 in diabetic retinas at 6 months of experimental diabetes and reduced retinal VEGF after 3 months. Values were based on 3-6 different animals per group. Data presented as mean  $\pm$  SD, \*  $p < 0.05$  compared to NC, #  $p < 0.05$  compared to DC. GAPDH: protein loading control.

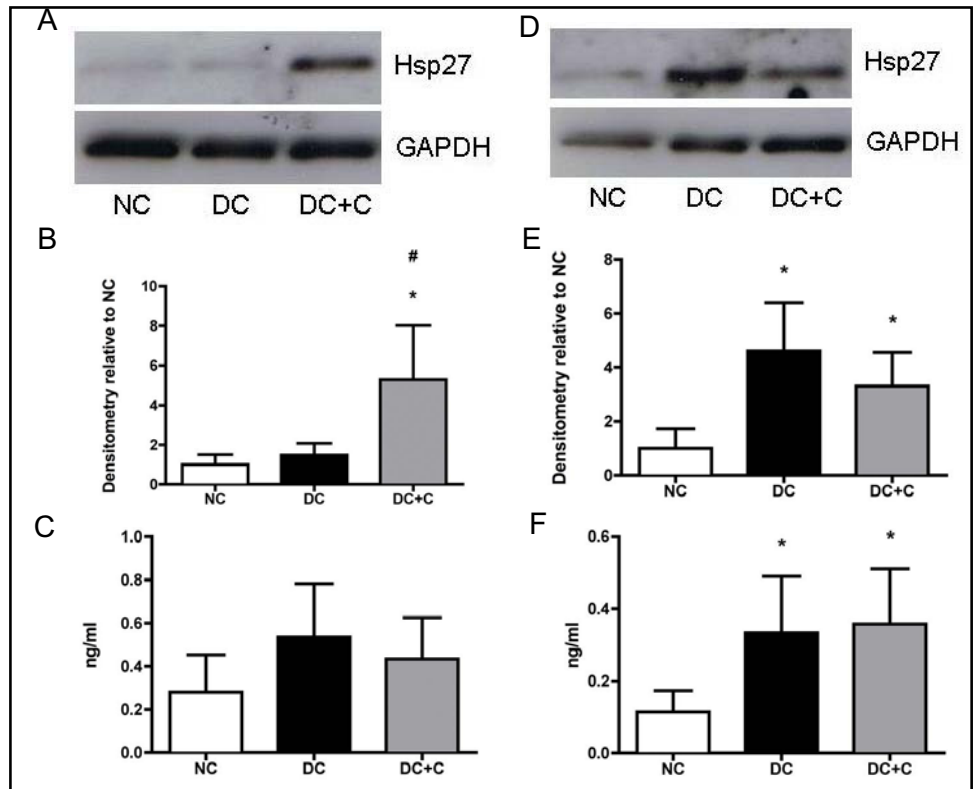


and HO-1 by +190% in DC when compared to NC (NC: 0.11 ng/ml  $\pm$  0.06 and DC: 0.33 ng/ml  $\pm$  0.16,  $p < 0.05$ , Fig. 5F). In retinas of DC+C, Hsp27 and HO-1 were also significantly increased (+230% and +212%, respectively, both  $p < 0.05$  compared to NC, HO-1 in NC: 0.11 ng/ml  $\pm$  0.06, HO-1 in DC: 0.36 ng/ml  $\pm$  0.15 and HO-1 in DC+C: 0.36  $\pm$  0.15, Fig. 5D- F), but carnosine treatment showed no further induction of Hsp27 and HO-1 protein when compared to of DC after 6 months (-28% and +7%, respectively, both DC vs. DC+C not significant, Fig. 5D- F).

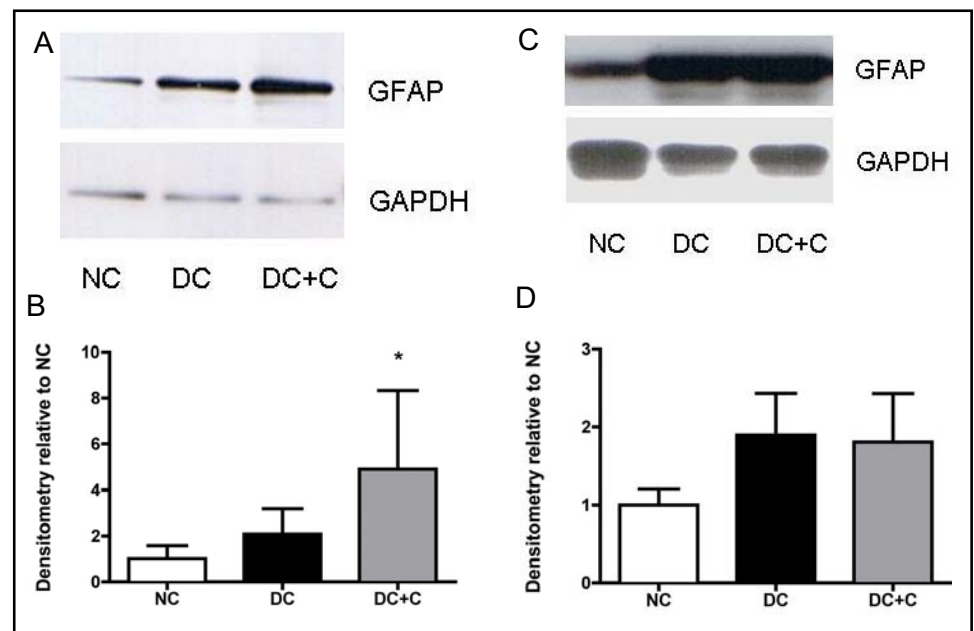
#### *Carnosine treatment induced Hsp27 expression in activated glial cells*

Glial activation accompanies vascular defects in the diabetic retina. In order to investigate the effect of hyperglycemia and carnosine treatment on the activation of retinal glial cells, immunoblots of retinal protein extracts probed against GFAP as a marker for glial cell activation were densitometrically analyzed. After 3 months of hyperglycemia, retinal GFAP expression was increased by 109% in retinas of DC ( $p > 0.05$  compared to NC) and upregulated by almost 4 fold in retinas of DC+C ( $p < 0.05$

**Fig. 5.** Illustration (A, D) and quantification (B, E) of Western blots of Hsp27 (A, B, D, E) and results obtained by ELISA system for HO-1 (C, F). Retinal protein extracts of non-diabetic (NC), diabetic (DC) and diabetic rats treated with carnosine (DC+C) were analyzed after 3 months (A-C) and 6 months (D-F) of hyperglycemia. In DC+C, Hsp27 was significantly upregulated after 3 months of hyperglycemia (A, B), whereas Hsp27 was significantly elevated in DC after 6 months when compared with non-diabetics controls (D, E). All diabetic retinas showed significantly increased levels of HO-1 after 6 months (F). Carnosine treatment had no effect on hyperglycemia-induced HO-1 expression in diabetic retinas. n=4-6 per group. Data presented as mean  $\pm$  SD, \*  $p < 0.05$  compared to NC, #  $p < 0.05$  compared to DC. GAPDH: protein loading control.



**Fig. 6.** Illustration (A, C) and quantification (B, D) of Western blots of GFAP as a marker of glial cell activation. Retinal protein extracts of non-diabetic (NC), diabetic (DC) and diabetic rats treated with carnosine (DC+C) were analyzed after 3 months (A, B) and 6 months (C, D) of hyperglycemia. As shown in Fig. 6 A and B, carnosine treatment led to a significant upregulation of GFAP in 3 months diabetic retinas. In retinas of DC, GFAP was slightly induced after 3 months (A, B), but significantly upregulated after 6 months of hyperglycemia (C, D). n=4-6 per group. Data presented as mean  $\pm$  SD, \*  $p < 0.05$  compared to NC. GAPDH: protein loading control.

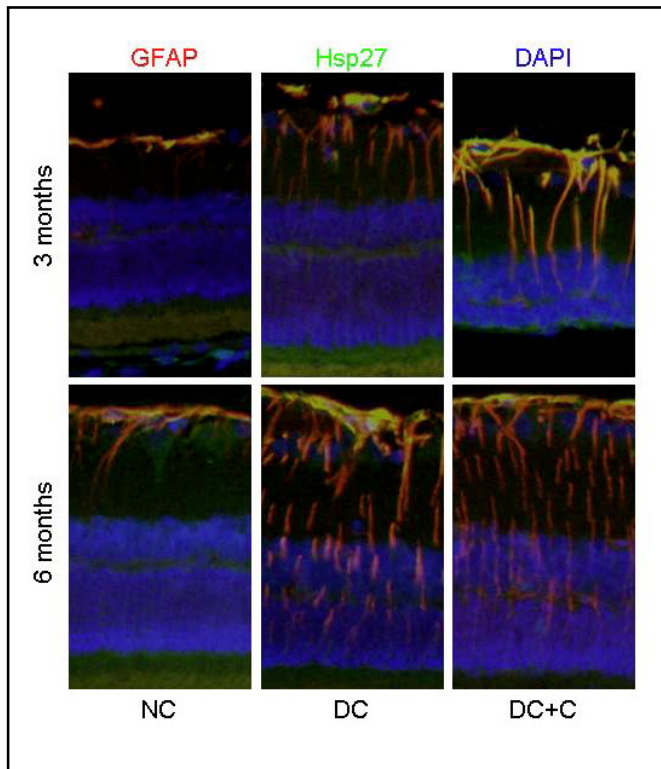


compared to NC, DC vs. DC+C not significant, Fig. 6A, B) when compared to NC. After 6 months of hyperglycemia, GFAP expression was slightly increased in retinas of DC (+77% compared to NC,  $p > 0.05$ , Fig. 6C, D) and upregulated by 80% in retinas of DC+C ( $p > 0.05$  compared to NC, DC vs. DC+C not significant) as shown in Figure 6 C and D.

In order to localize Hsp27 upregulation in the retina, retinal paraffin sections were stained for Hsp27, GFAP

as a glial marker and DAPI as nuclear marker. As depicted in Figure 7, carnosine induced upregulation of Hsp27 at 3 months of hyperglycemia was found in astrocytes and Muller cells throughout the entire retina. In accordance to our Western blot results, Hsp27 expression was slightly induced in DC after 3 months of hyperglycemia and highly expressed in retinal astrocytes and Muller cells after 6 months of DC, comparable to DC+C (Fig. 7).

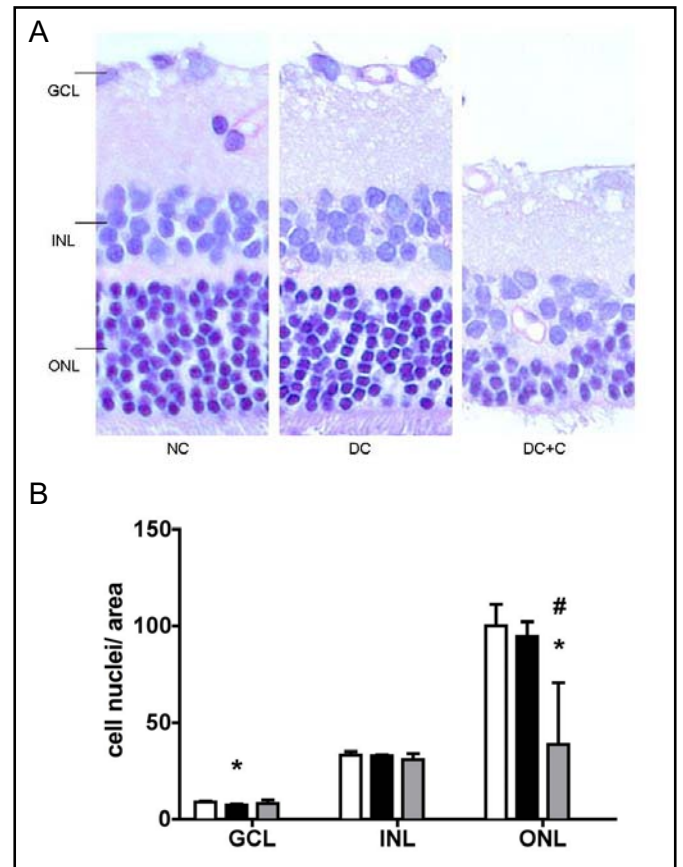




**Fig. 7.** Immunofluorescence staining of vertical paraffin sections of non-diabetic (NC), diabetic (DC) and diabetic rats treated with carnosine (DC+C) for GFAP (red) and Hsp27 (green) and DAPI as a nuclear marker (blue). Carnosine induced Hsp27 upregulation in GFAP-positive astrocytes and in Muller cells throughout the entire retina after 3 and 6 months, whereas retinas of DC showed upregulation of Hsp27 in GFAP-positive astrocytes and Muller cells after 6 months.  $n = 3$  per group. Original magnification 200x.

#### *Carnosine treatment induced loss of photoreceptor cells*

Neuronal cell loss has been observed as an early abnormality in diabetic retinas. The effect of experimental diabetes and oral carnosine supplementation on neuronal cells of the retina in this study was examined in PAS and hematoxylin stained paraffin section. We found a significant reduction of ganglion cell nuclei in retinas of DC at 3 months (-18% compared to NC, NC: 8.8 cell nuclei/area  $\pm 0.5$  and DC: 7.2 cell nuclei/area  $\pm 0.6$ ,  $p < 0.05$ , Fig. 8A, B) and a significant reduction in cell numbers and thickness of the outer nuclear layer in retinas of DC+C at 3 months of diabetes duration (-61% compared to NC



**Fig. 8.** Illustration (A) and quantification (B) of neuronal changes in PAS-stained paraffin sections of non-diabetic (NC), diabetic (DC) and diabetic rats treated with carnosine (DC+C) after 3 months of hyperglycemia. Numbers of cell nuclei were counted in each nuclear layer of the retina (GCL: ganglion cell layer, INL: inner nuclear layer, ONL: outer nuclear layer, white bars: NC, black bars: DC and grey bars: DC+C). In retinas of DC, numbers of cells in the GCL were significantly reduced (B). In retinas of DC+C, thickness and cell numbers of ONL are significantly reduced (A, B).  $n = 3-4$  per group. \*  $p < 0.05$  compared to NC, #  $p < 0.05$  compared to DC. Original magnification 400x.

and -59% compared to DC, NC: 100.2 cell nuclei/area, DC: 94.5 cell nuclei/area  $\pm 7.6$  and DC+C: 38.6 cell nuclei/area  $\pm 31.8$ ,  $p < 0.05$  compared to NC and DC, Fig. 8 A, B).

## Discussion

Growing evidence indicate a protective potential of carnosine in the treatment of diabetic complications. In this study, carnosine was tested in the prevention of experimental DR. We demonstrate that oral carnosine treatment delays the onset of hyperglycemia induced cata-

ract formation and prevents diabetes associated retinal vascular damage. These protective effects of carnosine were associated with induced expression of Hsp27 in activated retinal glial cells and prevention of hyperglycemia-induced upregulation of Ang-2. Interestingly, we could not confirm the antioxidative and antiglycating capacity of carnosine in this *in vivo* study. Furthermore, we show that high dose carnosine treatment led to a severe reduction in the number retinal photoreceptor cells.

In this study, carnosine completely prevented hyperglycemia-induced pericyte loss and vasoregression, demonstrating that carnosine directly or indirectly affects key steps in the cascade of pathological events in both, endothelial cells and pericytes. Retinal pericyte loss and the formation of non-perfused acellular capillaries are the cell-biological consequence of chronic hyperglycemic damage [2, 5]. A great body of evidence demonstrate that hyperglycemia induces an increased production of ROS, increases the formation of AGEs, which accumulate in microvascular cells *in vivo* and activates biochemical pathways, such as the hexosamine pathway [36]. On one side, these biochemical changes directly damage retinal cells by disturbed energy metabolism and modification of important intra- and extracellular proteins [37, 38]. On the other side, these highly active metabolic intermediates deregulate the expression of important angiogenic and inflammatory cytokines thereby indirectly damage retinal cells [39-41].

We recently provided evidence that upon direct cell toxicity of hyperglycemia upregulation of Ang-2 is implicated in diabetic pericyte loss and retinal vasoregression. Intravitreal injection of recombinant Ang-2 leads to pericyte loss and vasoregression in non-diabetic retinas and reduction of functional Ang-2 gene dose in a transgenic approach prevents vascular damage in diabetic retinas [42-44]. Consistent with previous observations, Ang-2 was significantly upregulated in diabetic retinas in this study. Interestingly, carnosine treatment normalized Ang-2 levels in diabetic retinas and this was associated with vascular protection. A number of factors have been described so far to be involved in the regulation of Ang-2, including hypoxia, tissue ischemia and growth factors such as VEGF [45-47]. It has been recently demonstrated that increased glucose flux in microvascular endothelial cells upregulates Ang-2 gene expression by increased modification of transcription complexes by MG and O-linked GlcNAc, but the specific mechanisms and localization of early Ang-2 upregulation in the diabetic retina are unclear [40]. Carnosine treatment neither affected protein modification by

MG-type AGEs nor by O-GlcNAc modification in diabetic retinas. Therefore, it is unlikely that carnosine treatment prevented Ang-2 upregulation in diabetic retinas due to its biochemical properties.

Carnosine is considered to be one of the most abundant naturally occurring antioxidant in the brain and its expression has been documented in specialized receptor neurons, neural progenitor cells and in glial cells distributed throughout the whole brain and spinal cord [48]. The exact function of carnosine in the CNS remains unknown, although a neuroprotective and neuromodulatory function has been advanced. In the retina, expression and function of carnosine and related dipeptides have been studied in less detail. The presence of carnosine has been demonstrated in photoreceptors and bipolar cells of amphibian retina, in a few ganglion cells and in endfoot processes of retinal Mueller cells [25-27]. Interestingly, carnosine treatment affected unspecified cells of the ganglion cell layer, Mueller cells throughout the entire retina and neurons of the outer retinal layers, suggesting a specific susceptibility of these cells to carnosine. However, glial cell activation indicated by upregulation of GFAP and Hsp are unspecific reactions occurring in several models of retinal damage, including DR [49, 50]. Therefore, carnosine-induced upregulation of Hsp27 in activated Mueller and glial cell after 3 months might also be an unspecific consequence to artificially increased carnosine levels and consequentially increased cellular stress.

As an important effect of the treatment, we demonstrate that cells of the outer nuclear layer were affected by carnosine treatment. Carnosine treated animals showed loss of photoreceptor cells. As mentioned, carnosine and related dipeptides localize to retinal photoreceptor cells and bipolar cells in various species and the appearance of carnosine-like immunoreactivity during retinal development is associated with the onset of visual function. In addition, a role as a neurotransmitter or neuromodulator in sensory systems has been proposed [25, 27, 51]. Therefore it seems likely that excessive supply of carnosine in this study led to misbalanced cross-talk of retinal neuronal cells and possibly even to cell damage in outer retinal neurons. Importantly, patients with homocarnosinosis, an inherited disorder, characterized by elevated levels of homocarnosine, carnosinuria and carnosinase deficiency suffer from photoreceptor degeneration [52]. In addition, there is increasing evidence that diabetic patients with outer retinal retinitis degenerative disorder pigmentosa have a reduced risk of the development of incipient DR [53, 54]. Likewise, it has been demonstrated that loss of the outer retina reduces the sever-

ity of experimental DR [55]. Therefore, we have to acknowledge that it might also be possible that the protective effect of carnosine found in this study is mediated by the influence of carnosine on non-vascular cells.

In conclusion, oral carnosine treatment in diabetic rats delays diabetic cataract formation and protects retinal capillaries from hyperglycemic damage. In parallel, carnosine treatment activates retinal glial cells and induces loss of outer retinal cell nuclei. Based on these findings it is obvious that further research is necessary to understand the role of carnosine in rodent and human retina and the potential use of carnosine in the treatment of DR and other diseases.

## Acknowledgements

This study was supported by Flamma S.p.a. (Chignolo d'Isola, Italy), grants from the German Diabetes-Association (DDG) and the Deutsche Forschungsgemeinschaft (DFG). F.P., E.R., F.v.H. and Q.W. are present or former graduate students of the international research training group (GRK 880 Vascular Medicine, Mannheim). Prof. Michael Brownlee, Albert Einstein College of Medicine, New York, N. Y. kindly supplied the anti-MG-H1 antibody. The authors thank Petra Bugert, Nadine Dietrich and Valerie Schwarz for their grateful technical support.

## References

- Klein R, Klein BE, Moss SE, Davis MD, DeMets DL: The wisconsin epidemiologic study of diabetic retinopathy. Iii. Prevalence and risk of diabetic retinopathy when age at diagnosis is 30 or more years. *Arch Ophthalmol* 1984;102:527-532.
- Hammes HP: Pericytes and the pathogenesis of diabetic retinopathy. *Horm Metab Res* 2005;37 Suppl 1:39-43.
- Barber AJ: A new view of diabetic retinopathy: A neurodegenerative disease of the eye. *Prog Neuropsychopharmacol Biol Psychiatry* 2003;27:283-290.
- Cogan DG, Toussaint D, Kuwabara T: Retinal vascular patterns. Iv. Diabetic retinopathy. *Arch Ophthalmol* 1961;66:366-378.
- Brownlee M: Biochemistry and molecular cell biology of diabetic complications. *Nature* 2001;414:813-820.
- Hammes HP, Ali SS, Uhlmann M, Weiss A, Federlin K, Geisen K, Brownlee M: Aminoguanidine does not inhibit the initial phase of experimental diabetic retinopathy in rats. *Diabetologia* 1995;38:269-273.
- Hammes HP, Bartmann A, Engel L, Wulfrath P: Antioxidant treatment of experimental diabetic retinopathy in rats with nicanartine. *Diabetologia* 1997;40:629-634.
- Kowluru RA, Tang J, Kern TS: Abnormalities of retinal metabolism in diabetes and experimental galactosemia. Vii. Effect of long-term administration of antioxidants on the development of retinopathy. *Diabetes* 2001;50:1938-1942.
- Millen AE, Klein R, Folsom AR, Stevens J, Palta M, Mares JA: Relation between intake of vitamins c and e and risk of diabetic retinopathy in the atherosclerosis risk in communities study. *Am J Clin Nutr* 2004;79:865-873.
- Stitt A, Gardiner TA, Alderson NL, Canning P, Frizzell N, Duffy N, Boyle C, Januszewski AS, Chachich M, Baynes JW, Thorpe SR: The age inhibitor pyridoxamine inhibits development of retinopathy in experimental diabetes. *Diabetes* 2002;51:2826-2832.
- Boldyrev A, Bulygina E, Leinsoo T, Petrushanko I, Tsubone S, Abe H: Protection of neuronal cells against reactive oxygen species by carnosine and related compounds. *Comp Biochem Physiol B Biochem Mol Biol* 2004;137:81-88.
- Hipkiss AR, Brownson C, Bertani MF, Ruiz E, Ferro A: Reaction of carnosine with aged proteins: Another protective process? *Ann N Y Acad Sci* 2002;959:285-294.
- Teufel M, Saudek V, Ledig JP, Bernhardt A, Boularand S, Carreau A, Cairns NJ, Carter C, Cowley DJ, Duverger D, Ganzhorn AJ, Guenet C, Heintzelmann B, Laucher V, Sauvage C, Smirnova T: Sequence identification and characterization of human carnosinase and a closely related non-specific dipeptidase. *J Biol Chem* 2003;278:6521-6531.
- Janssen B, Hohenadel D, Brinkkoetter P, Peters V, Rind N, Fischer C, Rychlik I, Cerna M, Romzova M, de Heer E, Baelde H, Bakker SJ, Zirie M, Rondeau E, Mathieson P, Saleem MA, Meyer J, Koppel H, Sauerhoefer S, Bartram CR, Nawroth P, Hammes HP, Yard BA, Zschocke J, van der Woude FJ: Carnosine as a protective factor in diabetic nephropathy: Association with a leucine repeat of the carnosinase gene cndp1. *Diabetes* 2005;54:2320-2327.
- Lee YT, Hsu CC, Lin MH, Liu KS, Yin MC: Histidine and carnosine delay diabetic deterioration in mice and protect human low density lipoprotein against oxidation and glycation. *Eur J Pharmacol* 2005;513:145-150.
- Jia H, Qi X, Fang S, Jin Y, Han X, Wang Y, Wang A, Zhou H: Carnosine inhibits high glucose-induced mesangial cell proliferation through mediating cell cycle progression. *Regul Pept* 2009;154:69-76.
- Sauerhofer S, Yuan G, Braun GS, Deinzer M, Neumaier M, Gretz N, Floege J, Kriz W, van der Woude F, Moeller MJ: L-carnosine, a substrate of carnosinase-1, influences glucose metabolism. *Diabetes* 2007;56:2425-2432.
- Kamei J, Ohsawa M, Miyata S, Tanaka S: Preventive effect of l-carnosine on changes in the thermal nociceptive threshold in streptozotocin-induced diabetic mice. *Eur J Pharmacol* 2008;600:83-86.
- Klein R, Lee KE, Knudtson MD, Gangnon RE, Klein BE: Changes in visual impairment prevalence by period of diagnosis of diabetes: The wisconsin epidemiologic study of diabetic retinopathy. *Ophthalmology* 2009;116:1937-1942.
- Babizhayev MA, Kasus-Jacobi A: State of the art clinical efficacy and safety evaluation of n-acetylcarnosine dipeptide ophthalmic prodrug. Principles for the delivery, self-bioactivation, molecular targets and interaction with a highly evolved histidyl-hydrazide structure in the treatment and therapeutic management of a group of sight-threatening eye diseases. *Curr Clin Pharmacol* 2009;4:4-37.
- Barber AJ, Lieth E, Khin SA, Antonetti DA, Buchanan AG, Gardner TW: Neural apoptosis in the retina during experimental and human diabetes. Early onset and effect of insulin. *J Clin Invest* 1998;102:783-791.
- Kern TS, Barber AJ: Retinal ganglion cells in diabetes. *J Physiol* 2008;586:4401-4408.

- 23 Fleisher-Berkovich S, Abramovitch-Dahan C, Ben-Shabat S, Apte R, Beit-Yannai E: Inhibitory effect of carnosine and n-acetyl carnosine on lps-induced microglial oxidative stress and inflammation. *Peptides* 2009;30:1306-1312.
- 24 Kusakari Y, Nishikawa S, Ishiguro S, Tamai M: Histidine-like immunoreactivity in the rat retina. *Curr Eye Res* 1997;16:600-604.
- 25 Panzanelli P, Cantino D, Sassoe-Pognetto M: Co-localization of carnosine and glutamate in photoreceptors and bipolar cells of the frog retina. *Brain Res* 1997;758:143-152.
- 26 Pognetto MS, Cantino D, Fasolo A: Carnosine-like immunoreactivity is associated with synaptic vesicles in photoreceptors of the frog retina. *Brain Res* 1992;578:261-268.
- 27 Pognetto MS, Panzanelli P, Fasolo A, Cantino D: Expression of carnosine-like immunoreactivity during retinal development in the clawed frog (*xenopus laevis*). *Brain Res Dev Brain Res* 1992;70:134-138.
- 28 Boldyrev A, Song R, Lawrence D, Carpenter DO: Carnosine protects against excitotoxic cell death independently of effects on reactive oxygen species. *Neuroscience* 1999;94:571-577.
- 29 Ohkawara T, Nishihira J, Nagashima R, Takeda H, Asaka M: Polaprezinc protects human colon cells from oxidative injury induced by hydrogen peroxide: Relevant to cytoprotective heat shock proteins. *World J Gastroenterol* 2006;12:6178-6181.
- 30 Ohkawara T, Takeda H, Kato K, Miyashita K, Kato M, Iwanaga T, Asaka M: Polaprezinc (n-(3-aminopropionyl)-l-histidinato zinc) ameliorates dextran sulfate sodium-induced colitis in mice. *Scand J Gastroenterol* 2005;40:1321-1327.
- 31 Mikami K, Otaka M, Watanabe D, Goto T, Endoh A, Miura K, Ohshima S, Yoneyama K, Sato M, Shibuya T, Segawa D, Kataoka E, Yoshino R, Takeuchi S, Sato W, Odashima M, Watanabe S: Zinc l-carnosine protects against mucosal injury in portal hypertensive gastropathy through induction of heat shock protein 72. *J Gastroenterol Hepatol* 2006;21:1669-1674.
- 32 Biro K, Jednakovits A, Kukorelli T, Hegedus E, Koranyi L: Bimoclolmol (brl-42) ameliorates peripheral neuropathy in streptozotocin-induced diabetic rats. *Brain Res Bull* 1997;44:259-263.
- 33 Biro K, Palhalmi J, Toth AJ, Kukorelli T, Juhasz G: Bimoclolmol improves early electrophysiological signs of retinopathy in diabetic rats. *Neuroreport* 1998;9:2029-2033.
- 34 Schonherr J: Analysis of products of animal origin in feeds by determination of carnosine and related dipeptides by high-performance liquid chromatography. *J Agric Food Chem* 2002;50:1945-1950.
- 35 Shinohara M, Thornalley PJ, Giardino I, Beisswenger P, Thorpe SR, Onorato J, Brownlee M: Overexpression of glyoxalase-i in bovine endothelial cells inhibits intracellular advanced glycation endproduct formation and prevents hyperglycemia-induced increases in macromolecular endocytosis. *J Clin Invest* 1998;101:1142-1147.
- 36 Yamagishi S, Fujimori H, Yonekura H, Tanaka N, Yamamoto H: Advanced glycation endproducts accelerate calcification in microvascular pericytes. *Biochem Biophys Res Commun* 1999;258:353-357.
- 37 Chen BH, Jiang DY, Tang LS: Advanced glycation end-products induce apoptosis involving the signaling pathways of oxidative stress in bovine retinal pericytes. *Life Sci* 2006;79:1040-1048.
- 38 Kowluru RA: Diabetic retinopathy: Mitochondrial dysfunction and retinal capillary cell death. *Antioxid Redox Signal* 2005;7:1581-1587.
- 39 Busik JV, Mohr S, Grant MB: Hyperglycemia-induced reactive oxygen species toxicity to endothelial cells is dependent on paracrine mediators. *Diabetes* 2008;57:1952-1965.
- 40 Yao D, Taguchi T, Matsumura T, Pestell R, Edelstein D, Giardino I, Suske G, Rabbani N, Thornalley PJ, Sarthy VP, Hammes HP, Brownlee M: High glucose increases angiotensin-2 transcription in microvascular endothelial cells through methylglyoxal modification of msn3a. *J Biol Chem* 2007;282:31038-31045.
- 41 Geraldes P, Hiraoka-Yamamoto J, Matsumoto M, Clermont A, Leitges M, Marette A, Aiello LP, Kern TS, King GL: Activation of pkc-delta and shp-1 by hyperglycemia causes vascular cell apoptosis and diabetic retinopathy. *Nat Med* 2009;15:1298-1306.
- 42 Hammes HP, Lin J, Wagner P, Feng Y, Vom Hagen F, Krzizok T, Renner O, Breier G, Brownlee M, Deutsch U: Angiotensin-2 causes pericyte dropout in the normal retina: Evidence for involvement in diabetic retinopathy. *Diabetes* 2004;53:1104-1110.
- 43 Pfister F, Feng Y, vom Hagen F, Hoffmann S, Molema G, Hillebrands JL, Shani M, Deutsch U, Hammes HP: Pericyte migration: A novel mechanism of pericyte loss in experimental diabetic retinopathy. *Diabetes* 2008;57:2495-2502.
- 44 Pfister F, Wang Y, Schreiter K, vom Hagen F, Altvater K, Hoffmann S, Deutsch U, Hammes HP, Feng Y: Retinal overexpression of angiotensin-2 mimics diabetic retinopathy and enhances vascular damages in hyperglycemia. *Acta Diabetol* 2010;47:59-64.
- 45 Simon MP, Tournaire R, Pouyssegur J: The angiotensin-2 gene of endothelial cells is up-regulated in hypoxia by a hif binding site located in its first intron and by the central factors gata-2 and ets-1. *J Cell Physiol* 2008;217:809-818.
- 46 Oh H, Takagi H, Suzuma K, Otani A, Matsumura M, Honda Y: Hypoxia and vascular endothelial growth factor selectively up-regulate angiotensin-2 in bovine microvascular endothelial cells. *J Biol Chem* 1999;274:15732-15739.
- 47 Tait CR, Jones PF: Angiotensins in tumours: The angiogenic switch. *J Pathol* 2004;204:1-10.
- 48 De Marchis S, Modena C, Peretto P, Migheli A, Margolis FL, Fasolo A: Carnosine-related dipeptides in neurons and glia. *Biochemistry (Mosc)* 2000;65:824-833.
- 49 Wang Q, Pfister F, Dorn-Beineke A, vom Hagen F, Lin J, Feng Y, Hammes HP: Low-dose erythropoietin inhibits oxidative stress and early vascular changes in the experimental diabetic retina. *Diabetologia* 2010;53:1227-1238.
- 50 Lewis GP, Fisher SK: Up-regulation of glial fibrillary acidic protein in response to retinal injury: Its potential role in glial remodeling and a comparison to vimentin expression. *Int Rev Cytol* 2003;230:263-290.
- 51 Jackson MC, Scollard DM, Mack RJ, Lenney JF: Localization of a novel pathway for the liberation of gaba in the human cns. *Brain Res Bull* 1994;33:379-385.
- 52 Sjaastad O, Berstad J, Gjesdahl P, Gjessing L: Homocarnosinosis. 2. A familial metabolic disorder associated with spastic paraplegia, progressive mental deficiency, and retinal pigmentation. *Acta Neurol Scand* 1976;53:275-290.
- 53 Arden GB: The absence of diabetic retinopathy in patients with retinitis pigmentosa: Implications for pathophysiology and possible treatment. *Br J Ophthalmol* 2001;85:366-370.
- 54 Arden GB, Wolf JE, Tsang Y: Does dark adaptation exacerbate diabetic retinopathy? Evidence and a linking hypothesis. *Vision Res* 1998;38:1723-1729.
- 55 de Gooyer TE, Stevenson KA, Humphries P, Simpson DA, Gardiner TA, Stitt AW: Retinopathy is reduced during experimental diabetes in a mouse model of outer retinal degeneration. *Invest Ophthalmol Vis Sci* 2006;47:5561-5568.