

Case Report

Xanthogranulomatous gastritis associated with actinomycosis: report of a case presenting as a large submucosal mass

Shogo Tajima^{1,2}, Michihiko Waki³, Akihiko Ohata⁴, Kenji Koda², Yasuhiko Maruyama⁴

¹Department of Pathology, Shizuoka Saiseikai General Hospital, Shizuoka, Japan; Departments of ²Pathology, ⁴Gastroenterology, Fujieda Municipal General Hospital, Shizuoka, Japan; ³Department of Cell Biology and Anatomy, Hamamatsu University School of Medicine, Shizuoka, Japan

Received October 29, 2014; Accepted December 22, 2014; Epub January 1, 2015; Published January 15, 2015

Abstract: Xanthogranulomatous gastritis (XGG) is a rarely encountered condition, and its causative mechanism is still unclear. Given that some types of xanthogranulomatous inflammation (XGI) are associated with pathogens, infection should be considered as a possible cause of XGG. Herein, we report a case of an 86-year-old woman presenting with a large, bleeding lesion resembling a submucosal tumor. Distal gastrectomy was performed, and the surgically resected specimen revealed a mass measuring 6 × 4.5 × 3 cm and appearing yellowish on the cut surface. Histopathological examination revealed a few *Actinomyces* “sulfur granules” and cellular composition characteristic of XGI, supporting a diagnosis of XGG associated with actinomycosis. Gastric actinomycosis is a rare condition and has not previously been reported in association with XGG, although rare cases of XGI associated with actinomycosis have been documented in other organs.

Keywords: Xanthogranuloma, actinomycosis, stomach

Introduction

Xanthogranulomatous inflammation (XGI) is a form of inflammation characterized by proliferative fibrous tissue intermingled with abundant foamy cells (lipid-laden macrophages) and other cells associated with acute and chronic inflammation. It is best known in the gallbladder [1] and kidney [2], but has also been reported in other organs. Gastrointestinal XGI is extremely rare [3] with less than 15 cases of xanthogranulomatous gastritis (XGG) reported to date in the English-language literature [4, 5]. In nearly all cases, XGG was initially misdiagnosed as a submucosal tumor (SMT) or advanced gastric carcinoma, and correct diagnosis was made postoperatively.

Actinomycosis, an infection caused by bacteria of the genus *Actinomyces*, may be encountered in various organs, manifesting as multiple abscesses in a dense fibrotic tissue [6, 7]. About 20 cases of gastric actinomycosis have been reported in the English-language litera-

ture [8]. In most cases, diagnosis was made by histopathological evaluation of a surgically resected specimen; however, a few cases were diagnosed endoscopically [9].

Herein, we describe the first reported case of XGG related to actinomycosis. Although it was preoperatively suspected to be an SMT, the accurate diagnosis was obtained by close examination of the surgically resected specimen.

Case report

An 86-year-old woman was hospitalized with melena. Upper gastrointestinal endoscopy revealed an SMT-like gastric mass with an ulcerated depression as the source of the bleeding (**Figure 1A, 1B**). She had no previous history of such a condition and no systemic symptoms except for mild fever (37.8°C). Laboratory studies revealed severe anemia (hemoglobin 5.0 g/dL) but no sign of inflammation (white blood cell count 6900/μL, C-reactive

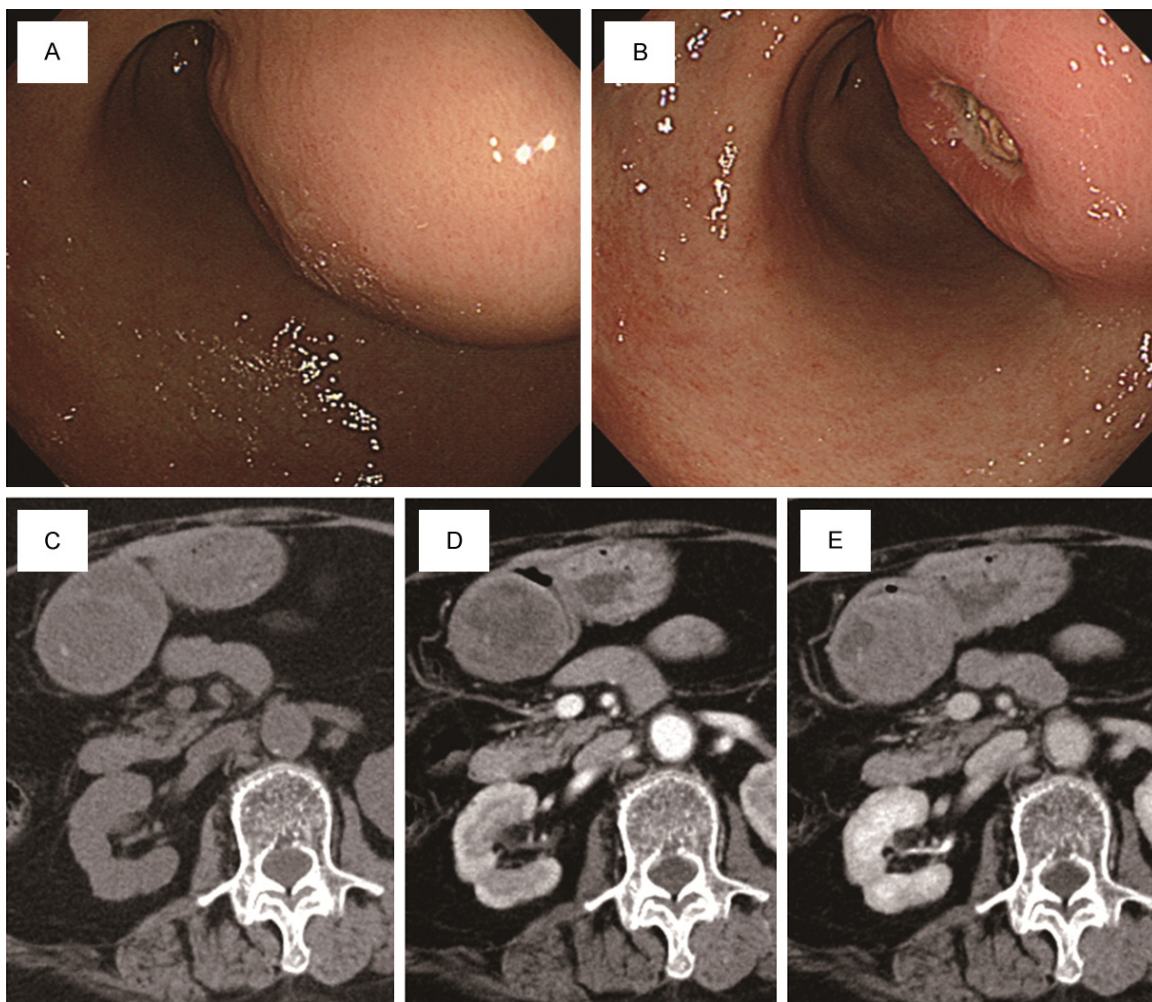


Figure 1. Findings of upper gastrointestinal endoscopy and computed tomography (CT). A, B. Upper gastrointestinal endoscopy revealed a gastric mass resembling a submucosal tumor with an ulcerated depression on its surface. C. On CT, most of the mass showed low density. D. During the arterial phase of contrast-enhanced CT, the mass displayed slight enhancement. E. During the late phase of contrast-enhanced CT, the mass displayed mild enhancement.

protein 0.3 mg/dL). Serum was negative for antibodies to *Helicobacter pylori*. The mass was low density on initial computed tomography (CT) (**Figure 1C**). CT with contrast enhancement displayed a gradually enhanced mass resembling an SMT and measuring about 6 cm across at the widest (**Figure 1D, 1E**). No other abnormal findings were observed in the abdominal organs. Because of the size of the mass and its continuous bleeding, distal gastrectomy was performed. Tissue culture of the mass was not conducted.

The surgically resected specimen revealed a mass measuring 6 × 4.5 × 3 cm (**Figure 2A**). Its cut surface was yellowish. It was predominantly

situated in the gastric submucosa but extended through the muscular layer nearly to the subserosa (**Figure 2B**).

Low-power magnification of sections stained with hematoxylin and eosin showed heterogeneous patterns of cells, with numerous faintly staining areas where foamy cells were abundant (**Figure 3A**). High-power magnification showed three distinct cell patterns compatible with a diagnosis of XGG. The first pattern consisted of numerous foamy cells mixed with multinucleated giant cells known as Touton giant cells (**Figure 3B**). The second pattern consisted of spindle cells mixed with abundant foamy cells and scattered lymphocytes (**Figure 3C**).

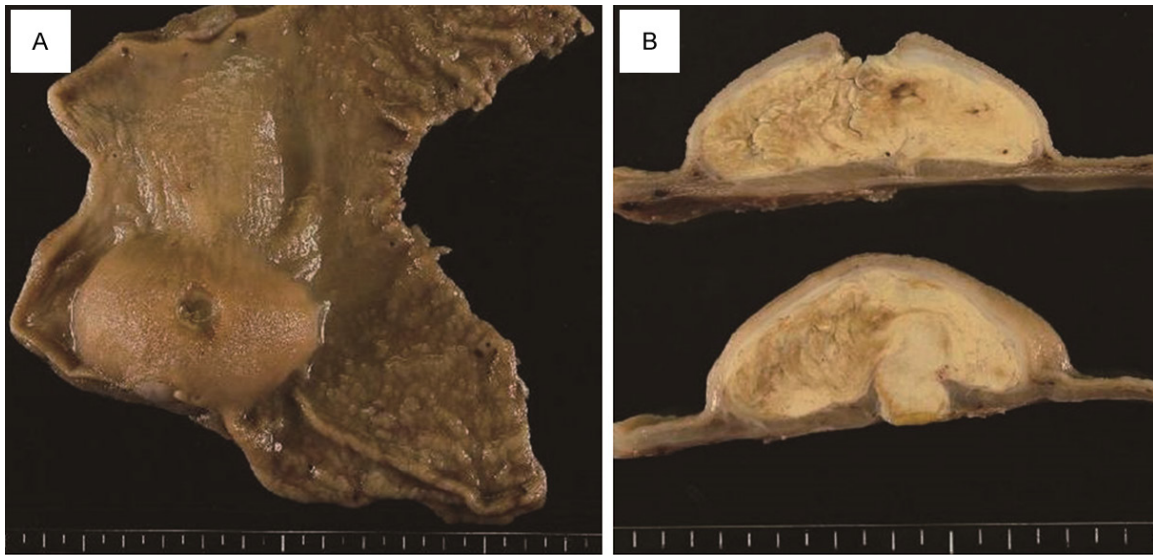


Figure 2. Macroscopic findings. A. The mass resembled a submucosal tumor and measured $6 \times 4.5 \times 3$ cm. B. The cut surface of the mass was almost entirely yellowish. The mass was predominantly situated in the gastric submucosa but extended through the muscular layer nearly to the subserosa.

The third pattern consisted of proliferating spindle cells mixed with infiltrating lymphocytes, with few foamy cells (**Figure 3D**). The second pattern predominated throughout the mass. Microscopic abscesses were present and contained a few “sulfur granules” (bacterial colonies with branching filaments peripherally arranged in a radial pattern), which was consistent with actinomycosis (**Figure 3E**).

Immunohistochemical analysis using polyclonal rabbit anti-*H. pylori* (Dako, Glostrup, Denmark) was negative. Proliferating spindle cells were not stained with classical markers to subclassify gastric SMTs, such as c-kit, CD34, desmin, and S100 protein.

The postoperative course was uneventful, and the patient has been recurrence-free for 1 year to date.

Discussion

The details of the pathogenesis of XGI are still unclear. Various possibilities have been suggested, including defective lipid transport, immunological disorders, infection with low-virulence pathogens, impaired clearance of such pathogens, and lymphatic obstruction [10]. XGI is characterized by tissue destruction and localized proliferation of macrophages containing large amounts of lipid, which may represent a

chronic process of interaction between the body and a pathogen. Indeed, *Escherichia coli* is considered the etiological agent in most cases of XGI of the kidney [2] and gallbladder [11], although some cases of XGI in the gallbladder are probably due to rupture of Rokitsansky-Aschoff sinuses with resultant liberation of bile lipids into the adjacent tissue [1]. Other diseases also characterized histologically by an abundance of macrophages, such as Whipple’s disease [12] and malakoplakia [13], result from defective clearance of bacteria in a variety of organs. The causative agent of the former is *Tropheryma whipplei*, one of the actinomycetes; that of the latter is usually *E. coli*.

Two previous cases of XGI associated with actinomycosis have been reported in the English-language literature. One of them occurred in the kidney [14] and the other in the spermatic cord [15]. No previous cases of XGG associated with a microorganism have been reported, although histological similarities between cases of XGG and gastric xanthomas might seem to suggest similar causative mechanisms for both. However, *H. pylori*, often found in gastric xanthomas [16], was not present in this case.

There are 4 main forms of actinomycosis, which may occasionally co-occur: cervicofacial, thoracic, abdominopelvic, and cerebral forms. The

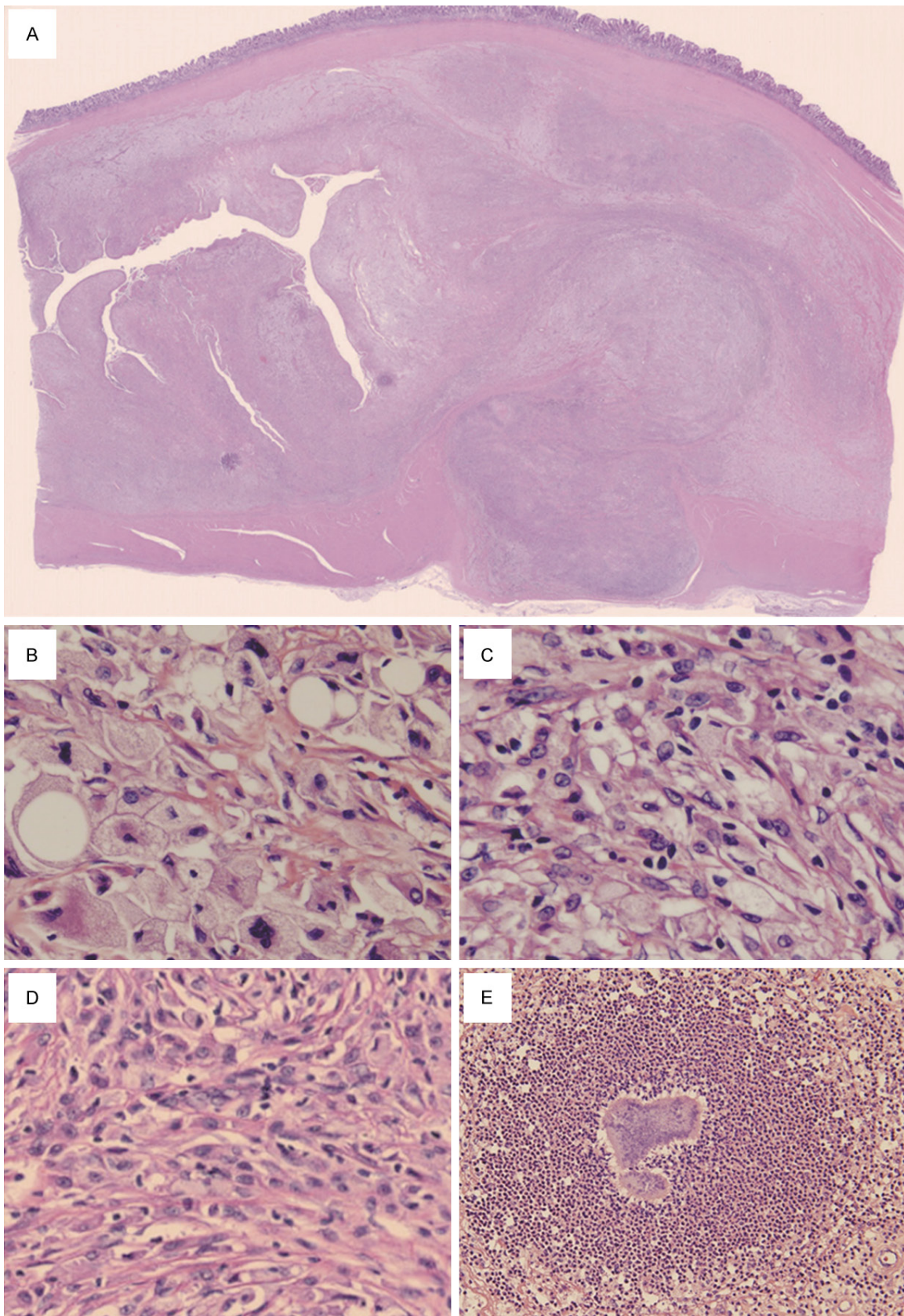


Figure 3. Microscopic findings. Sections stained with hematoxylin and eosin. A. Low-power view showing the heterogeneous cellular composition of the mass, with numerous faintly stained areas (2.5 ×). B. High-power view of

foamy-cell-rich area with multinucleated giant cells known as Touton giant cells (400 ×). C. High-power view of a representative area, consisting of spindle cells mixed with abundant foamy cells and scattered lymphocytes (400 ×). D. High-power view of an area with proliferating spindle cells and infiltrating lymphocytes with few foamy cells (400 ×). E. A “sulfur granule” surrounded by neutrophils (200 ×).

cervicofacial form is the most common, followed by the thoracic and abdominopelvic forms [17]. Several *Actinomyces* species can be pathogenic in humans, including *A. naeslundii*, *A. odontolyticus*, *A. viscosus*, *A. meyeri*, and *A. gerencseriae*; however, actinomycosis, including the abdominopelvic form, is most commonly caused by *A. israelii* [6, 17]. The bacteria are indigenous in the oral cavity, gastrointestinal tract, and genital tract. Opportunistic infection occurs when the mucosal barrier is damaged, which may result in multiple abscesses, dense fibrosis, or a massive lesion [6, 7]. Signs and symptoms of abdominopelvic actinomycosis depend on the anatomical location of the disease, but pain and leukocytosis are usually present [18, 19]. However, some cases, like this one, may present with no pain and no elevation in levels of inflammation indicators [9, 20].

Although diagnosis of actinomycosis is ideally made by identification of *Actinomyces* species, microbe isolation is achieved in fewer than 50% of cases [7]. In tissues, infectious *Actinomyces* species grow in microscopic or macroscopic clusters of tangled filaments surrounded by polymorphonuclear neutrophils, which are called “sulfur granules.” Histopathological examination reveals 1 to 3 sulfur granules in about 75% of cases [18]. However, there have been cases in which actinomycosis was diagnosed by culture despite the absence of identifiable sulfur granules [17]. In our case, the presence of sulfur granules, though they were sparse, strongly supported a diagnosis of actinomycosis without tissue cultivation; it would be reasonable to assume that actinomycosis was involved in the development of this case of XGG.

In conclusion, we report a hitherto undescribed relationship between XGG and actinomycosis. Although some types of XGI are thought to be caused by infectious microorganisms, XGI caused by actinomycosis has rarely been documented. Sulfur granules present in our case indicated infection with *Actinomyces*. No other microorganisms or potential causes of XGG were found.

Acknowledgements

We appreciate the technical assistance provided by Ms. Tomomi Shimizu, Ms. Sachiko Unno, and Ms. Toyoko Yajima.

Disclosure of conflict of interest

None.

Address correspondence to: Dr. Shogo Tajima, Department of Pathology, Shizuoka Saiseikai General Hospital, 1-1-1 Oshika, Suruga-ku, Shizuoka 422-8021, Japan. Tel: +81-54-285-6171; Fax: +81-54-285-5179; E-mail: stjajima-ky@umin.ac.jp

References

- [1] Dao AH, Wong SW and Adkins RB Jr. Xanthogranulomatous cholecystitis. A clinical and pathologic study of twelve cases. *Am Surg* 1989; 55: 32-35.
- [2] Korkes F, Favoretto RL, Broglio M, Silva CA, Castro MG and Perez MD. Xanthogranulomatous pyelonephritis: clinical experience with 41 cases. *Urology* 2008; 71: 178-180.
- [3] Oh YH, Seong SS, Jang KS, Chung YW, Paik CH, Park YW and Han DS. Xanthogranulomatous inflammation presenting as a submucosal mass of the sigmoid colon. *Pathol Int* 2005; 55: 440-444.
- [4] Kubosawa H, Yano K, Oda K, Shiobara M, Ando K, Nunomura M and Sarashina H. Xanthogranulomatous gastritis with pseudosarcomatous changes. *Pathol Int* 2007; 57: 291-295.
- [5] Tsukada T, Nakano T, Miyata T, Sasaki S and Higashi K. Xanthogranulomatous gastritis mimicking malignant GIST on F-18 FDG PET. *Ann Nucl Med* 2012; 26: 752-756.
- [6] Russo TA. Agents of actinomycosis. In: Mandell GL, Bennett JE, Dolin R, editors. *Mandell, Douglas, and Bennett's principles and practice of infectious diseases*. 7th edition. Philadelphia, Pa: Churchill Livingstone Elsevier; 2010. pp. 3209-3219.
- [7] Brown JR. Human actinomycosis. A study of 181 subjects. *Hum Pathol* 1973; 4: 319-330.
- [8] Fernandez-Acenero MJ, Silvestre V, Fernandez-Roldan R, Cortes L and Garcia-Blanch G. Gastric actinomycosis: a rare complication after gastric bypass for morbid obesity. *Obes Surg* 2004; 14: 1012-1015.
- [9] Patel N, Woodcock H, Patel K, Amo-Takyi B, Wotherspoon A, Thompson J and Prasad P.

- Gastric actinomycosis: an rare endoscopic diagnosis. *Endoscopy* 2010; 42 Suppl 2: E218-219.
- [10] Antonakopoulos GN, Chapple CR, Newman J, Crocker J, Tudway DC, O'Brien JM and Considine J. Xanthogranulomatous pyelonephritis. A reappraisal and immunohistochemical study. *Arch Pathol Lab Med* 1988; 112: 275-281.
 - [11] Sawada S, Harada K, Isse K, Sato Y, Sasaki M, Kaizaki Y and Nakanuma Y. Involvement of *Escherichia coli* in pathogenesis of xanthogranulomatous cholecystitis with scavenger receptor class A and CXCL16-CXCR6 interaction. *Pathol Int* 2007; 57: 652-663.
 - [12] Schwartzman S and Schwartzman M. Whipple's disease. *Rheum Dis Clin North Am* 2013; 39: 313-321.
 - [13] Yousef GM, Naghibi B and Hamodat MM. Malakoplakia outside the urinary tract. *Arch Pathol Lab Med* 2007; 131: 297-300.
 - [14] Lin TP, Fu LS, Peng HC, Lee T, Chen JT and Chi CS. Intra-abdominal actinomycosis with hepatic pseudotumor and xanthogranulomatous pyelonephritis in a 6-y-old boy. *Scand J Infect Dis* 2001; 33: 551-553.
 - [15] Nistal M, Gonzalez-Peramato P, Serrano A and Regadera J. Xanthogranulomatous funiculitis and orchiepididymitis: report of 2 cases with immunohistochemical study and literature review. *Arch Pathol Lab Med* 2004; 128: 911-914.
 - [16] Hori S and Tsutsumi Y. *Helicobacter pylori* infection in gastric xanthomas: immunohistochemical analysis of 145 lesions. *Pathol Int* 1996; 46: 589-593.
 - [17] Smego RA Jr and Foglia G. Actinomycosis. *Clin Infect Dis* 1998; 26: 1255-1261; quiz 1262-1253.
 - [18] Valour F, Senechal A, Dupieux C, Karsenty J, Lustig S, Breton P, Gleizal A, Boussel L, Laurent F, Braun E, Chidiac C, Ader F and Ferry T. Actinomycosis: etiology, clinical features, diagnosis, treatment, and management. *Infect Drug Resist* 2014; 7: 183-197.
 - [19] Berardi RS. Abdominal actinomycosis. *Surg Gynecol Obstet* 1979; 149: 257-266.
 - [20] Lee SY, Kwon HJ, Cho JH, Oh JY, Nam KJ, Lee JH, Yoon SK, Kang MJ and Jeong JS. Actinomycosis of the appendix mimicking appendiceal tumor: a case report. *World J Gastroenterol* 2010; 16: 395-397.