

## Original Article

# Early articular cartilage degeneration in a developmental dislocation of the hip model results from activation of $\beta$ -catenin

Bo Ning<sup>1,2</sup>, Jun Sun<sup>1</sup>, Yi Yuan<sup>1</sup>, Jie Yao<sup>1</sup>, Peng Wang<sup>2</sup>, Ruixue Ma<sup>2</sup>

<sup>1</sup>Department of Pediatric Orthopaedic, Anhui Provincial Children's Hospital, 39 Wangjiang Road, 230051, Hefei, China; <sup>2</sup>Department of Pediatric Orthopaedic, Children's Hospital of Fudan University, 399 Wanyuan Road, 201102, Shanghai, China

Received January 31, 2014; Accepted March 2, 2014; Epub March 15, 2014; Published April 1, 2014

**Abstract:** Developmental dislocation or dysplasia of the hip (DDH) is one of the most common deformities in children. Osteoarthritis (OA) is the most frequent long-term complication. The molecular mechanism of early articular cartilage degeneration in DDH is still unclear. It is well known that  $\beta$ -catenin plays a crucial role in articular cartilage degeneration. The objective of this study was to verify the relationship between  $\beta$ -catenin and DDH cartilage degeneration. We used a DDH model that was established by modification of swaddling position in newborn Wistar rats. The hips were isolated from the DDH model rats and untreated control group at the age of 2, 4, 6 and 8 weeks.  $\beta$ -Catenin gene and protein were investigated by quantitative (q)RT-PCR and immunohistochemistry. Collagen X and matrix metalloproteinase (MMP)-13, markers of early cartilage degeneration, were assessed by qRT-PCR. Primary chondrocytes were cultured from cartilage of two groups at the age of 8 weeks. Expression of  $\beta$ -catenin, collagen X and MMP-13 was detected. Continued high expression of  $\beta$ -catenin was observed in cartilage from DDH model rats. mRNA and protein expression of  $\beta$ -catenin was significantly increased in primary chondrocytes of the DDH model compared with the control group. Collagen X and MMP-13 expression was higher in the cartilage and chondrocytes from DDH model rats than the control group. Our findings suggest that early cartilage degeneration in DDH may result from activation of  $\beta$ -catenin signaling.

**Keywords:**  $\beta$ -catenin, hip dysplasia, cartilage degeneration, osteoarthritis

## Introduction

Developmental dislocation or dysplasia of the hip (DDH) is one of most common diseases in pediatric orthopedics. The reported incidence rate of DDH is 2.5-5% [1]. The cause of DDH is still unknown although some risk factors, including female sex, firstborn child, genetic factors and swaddling clothes, have been identified [2, 3]. The swaddling position after birth may result in DDH, therefore, many studies have used a DDH model in different animals, which is established by extending the hip and knee [4]. The straight leg swaddling position of newborn rats was modified to construct the DDH model in our previous study [5].

Osteoarthritis (OA) is the most frequent long term complication of DDH. Compared with the

normal population, DDH OA has an early age of onset and serious clinical features, and most patients need to undergo total hip arthroplasty (THA) [6]. The present study confirmed that there was cartilage degeneration in the early stage of DDH [5]. Poor containment of the acetabulum and femoral head in DDH creates abnormal forces in the hip joints, which play an important role in DDH cartilage degeneration. Although the treatment of DDH has made great progress because of early screening and improved surgery in recent years [7, 8], the long-term incidence of OA has not decreased [6, 9]. Therefore, the abnormal forces may not be the exclusive factor of cartilage degeneration in DDH. DDH is a developmental disease, thus, we hypothesize that cartilage degeneration in the early stage of DDH may partly result from growth factors.

**Table 1.** Primers used for amplification of target genes and β-actin

	F-Sequence (5'-3')	R-Sequenc (5'-3')
Collagen X	GATCATGGAGCTCACGGA AAA	CCGTTTCGATTCCGCATTG
MMP 13	TACGAGCATCCATCCCGAGACC	AACCGCAGCACTGAGCC TTTTC
β-catenin	GCAATCAGGAAAGCAAGCTC	TCAGCACTCTGCTTG TGGTC
β-actin	GGAGATTACTGCCCTGGCTCCTA	GACTCATCGTACTCTGCTTGCTG

In recent years, many studies have shown that β-catenin and its Wnt signaling pathway play a crucial role in articular cartilage formation and degeneration. Transgenic studies have shown that β-catenin promotes the maturation of growth plate chondrocytes after cartilage formation [10] and lack of signaling leads to defects in postnatal cartilage development [11]. Some studies have shown that β-catenin plays a critical role throughout chondrogenesis and chondrocyte maturation [12, 13]. However, activation of β-catenin can lead to cartilage degeneration and OA progression. In cartilage of human OA patients, high expression levels of β-catenin have been detected [11, 14]. Conditional activation of β-catenin signaling in adult mouse articular chondrocytes leads to an OA-like phenotype [15]. In addition, functional deletion of the Frizzled-related protein in a murine model of OA results in disease exacerbation [16, 17]. A dual function of β-catenin in articular cartilage growth and degeneration at different stages of postnatal cartilage developmental has been confirmed in rats [18]. All of these studies strongly suggest that the β-catenin signaling pathway plays a crucial role in cartilage formation and development, and is involved in the etiology and progression of OA.

Previous studies have demonstrated degenerative changes in the articular cartilage in the early stage of DDH [5, 19]. However, the molecular mechanism of early articular cartilage degeneration and OA is still unclear. As a link between cartilage development and degeneration, the function of β-catenin in DDH early cartilage degeneration has not been reported. We hypothesized that DDH cartilage may lead to high expression of β-catenin, and result in cartilage degeneration. To investigate the relation between β-catenin and cartilage degeneration in the early stage of DDH, we detected expression of β-catenin in cartilage at different stages of the rat DDH model and control group by immunohistochemistry and quantitative (q) RT-PCR. Collagen X and matrix metalloproteinase (MMP)-13 are well-known early cartilage

degenerative marker genes [20-23], and were detected in sections and chondrocytes. To the best of our knowledge, this is the first report of the relation between β-catenin and cartilage degeneration in a DDH model.

## Materials and methods

### *DDH model and tissue collection*

Wistar rats were randomly divided into DDH and control groups. In each group, 80 rats were used and sacrificed by overdose anesthesia at ages corresponding to human developmental stages of toddler (2 weeks), child (4 weeks), teenager (6 weeks), and adult (8 weeks). Cartilage from the hip joints was used for immunohistochemistry, qRT-PCR and cell culture.

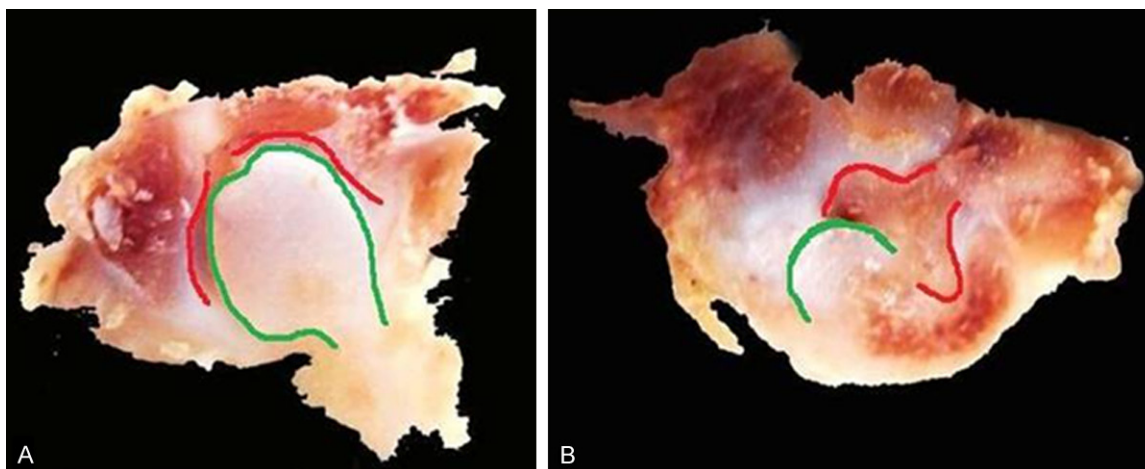
The DDH model was induced by modifying the swaddling position with fixation of the hind limbs in extension and adduction in newborn Wistar rats for 10 days [5]. The rats were fed their mother's milk during fixation. The weight and sex of the rats in each group were determined. This study was approved by the local ethics commission.

### *Immunohistochemistry*

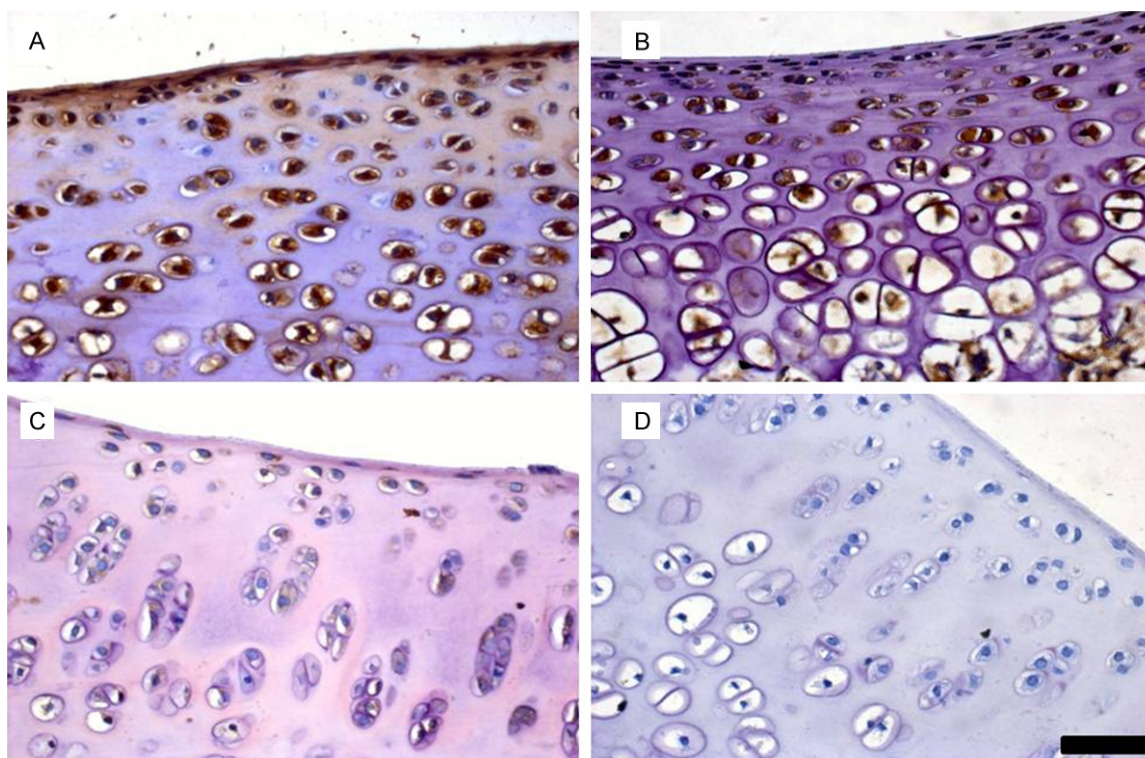
Isolated hip joints at different ages were fixed in 4% paraformaldehyde, decalcified in 10% EDTA until complete demineralization, and then embedded in paraffin. Ten representative sections (4 μm) of each joint from various depths were mounted on slides. Immunohistochemistry was carried out using a standard procedure [8]. In brief, the paraffin was removed, and the sections were incubated overnight at 4°C with rabbit anti-rat β-catenin monoclonal antibody at a dilution of 1:50 (Abcam, Cambridge, MA, USA). For the negative control reaction, the primary antibody was omitted. Thereafter, sections were detected with Envision Detection Kit (Dako, Glostrup, Denmark). Slides were visualized under a microscope.

### *Cell isolation and cell culture*

Hip joints isolated from 8-week-old rats in each group were washed in D-Hanks solution immediately upon excision. The femoral head and acetabular articular cartilage were harvested,



**Figure 1.** DDH model in newborn Wistar rats. A. Control group: containment between acetabulum and femoral head was excellent. B. DDH group: irregular acetabulum and femoral head were observed. (red line: acetabulum; green line: femoral head).

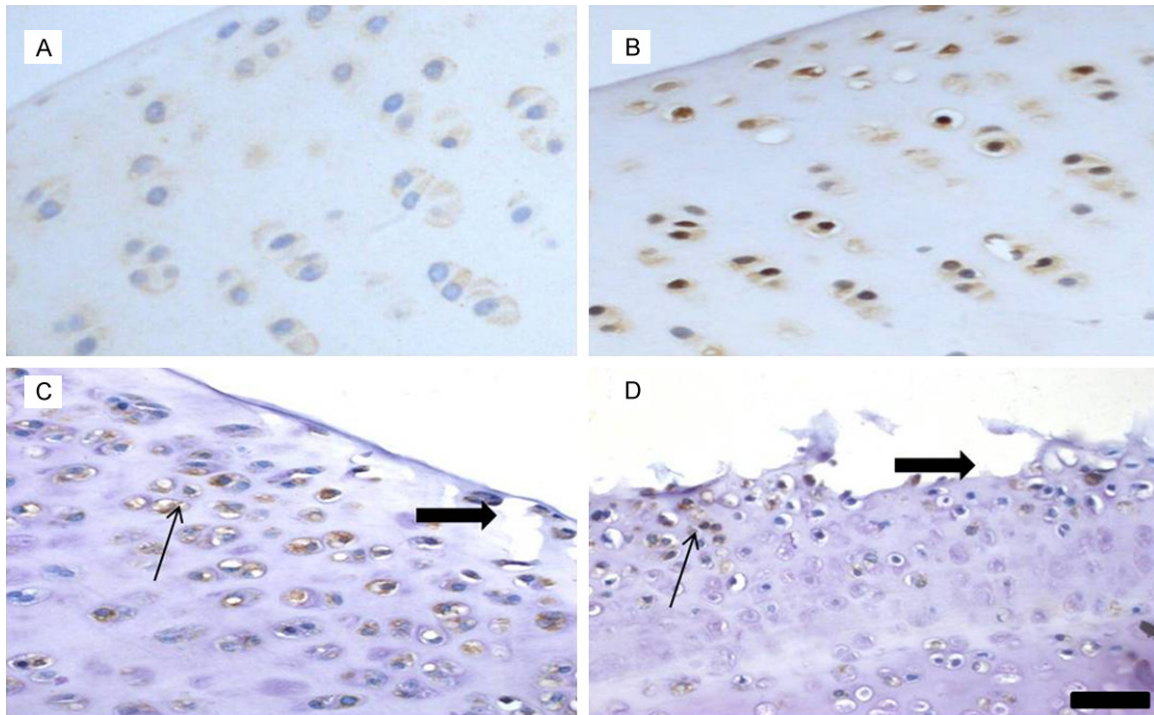


**Figure 2.** Expression of  $\beta$ -catenin in articular cartilage of control group at different ages. A. 2 weeks; B. 4 weeks; C. 6 weeks; D. 8 weeks. Expression of  $\beta$ -catenin protein decreased with age. (scale bar = 100  $\mu$ m).

rewashed with D-Hanks, and completely digested by soaking in 0.25% trypsin (Gibco-Invitrogen, Carlsbad, CA, USA) for 15 min in a 37°C shaking water bath. A solution of 0.2% collagenase II in 10% fetal bovine serum (FBS)

and Dulbecco's Modified Eagle's Medium (DMEM; Sigma-Aldrich, St. Louis, MO, USA) was added and the solution was further incubated with shaking for 3 h. A 2-ml aliquot of the digested product was collected every hour. The





**Figure 3.** Expression of β-catenin in articular cartilage of DDH group at different ages. A. 2 weeks; B. 4 weeks; C. 6 weeks; D. 8 weeks. High expression of β-catenin protein continued with age. Eroded cartilage and cleft were observed and chondrocytes formed clusters. (thick arrow: cleft; thin arrow: clusters formation). (scale bar = 100 μm).

digested product was passed through a 100-μm Swinex filter to remove any residual fragments, and the filtrate was centrifuged. The pelleted cells were resuspended in complete medium (DMEM with 10% FBS, 1% penicillin/streptomycin, 100 mM L-glutamine). Cells were counted and plated at the appropriate density in 25-cm culture flasks for incubation in a 5% CO<sub>2</sub>-air mixture at 37°C. The media were refreshed every 3-4 days. All experiments were conducted using first-passage cells. The chondrocytes were identified by the presence of collagen II in immunofluorescence and toluidine blue staining.

#### Immunofluorescence microscopy

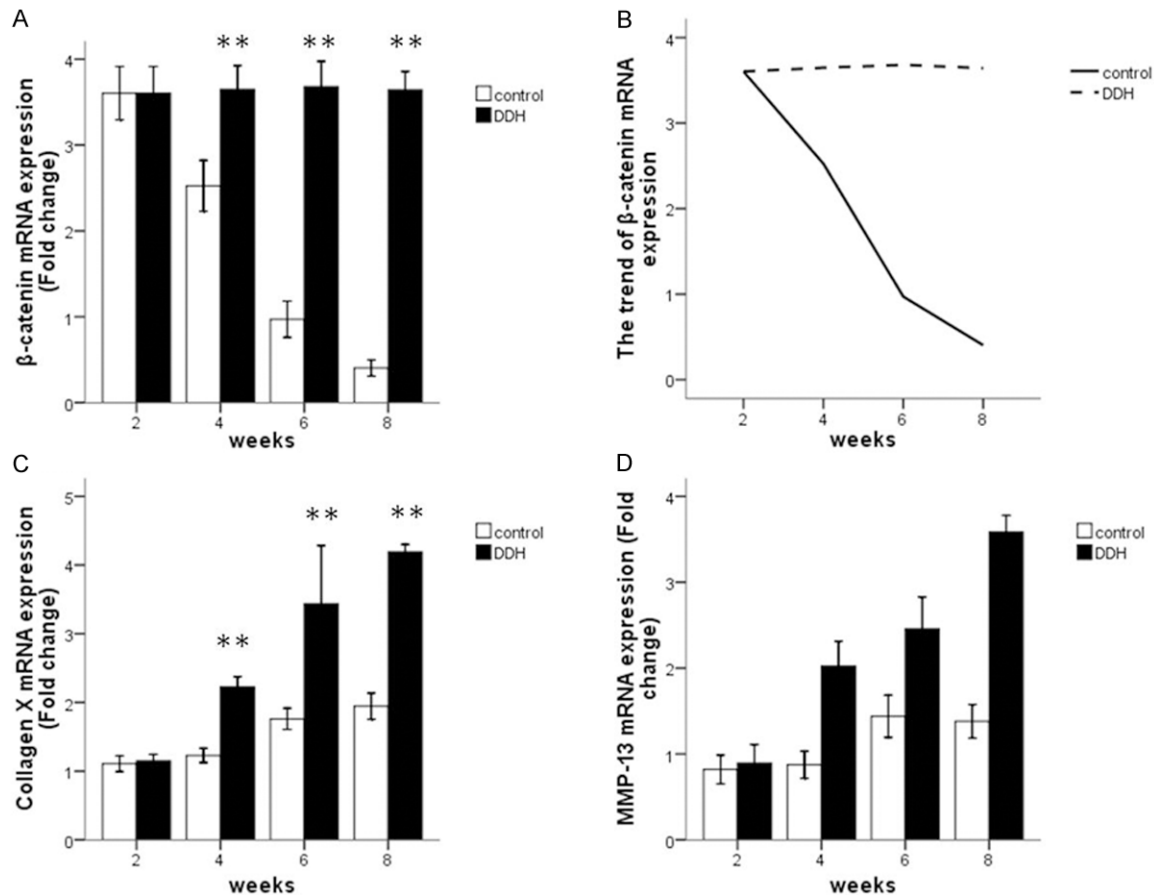
Articular chondrocytes cultured in six-well plates in each group were fixed with 4% paraformaldehyde for 10 min and blocked with 10% goat serum in PBS supplemented with 0.2% Triton X-100 (PBST; Sigma). Primary antibody incubation was performed overnight at 4°C for antibodies (Abcam) against collagen II and β-catenin. After washing, secondary antibody incubation was carried out for 1 h at room temperature with anti-rabbit AlexaFluor 488 antibody (1:50, Invitrogen). Cells were imaged by

fluorescent microscopy (Leica Microsystems, Buffalo Grove, IL, USA).

#### RNA extraction and qRT-PCR

Total RNA from cartilage and chondrocytes was extracted using Trizol reagent (Invitrogen-Life Technologies, Paisley, UK). The purity and amount of RNA were determined by measurement of the OD<sub>260/280</sub> ratio. All samples showed purity indices between 1.8 and 2.0. Preservation of 28S and 18S rRNA species was used to assess RNA integrity. All the samples included in the study had prominent 28S and 18S rRNA components. Reverse transcription of 1 μg RNA to cDNA was performed using ReverTra Ace qPCR RT kit (TOYOBO, Osaka, Japan) according to the manufacturer's instructions. The yield was quantified spectrophotometrically.

qRT-PCR was performed using 5 μl cDNA (100 ng), 2 μl each primer (10 μM), 25 μl SYBR Green Realtime PCR Master Mix (TOYOBO), and 16 μl water in a total volume of 50 μl. The target genes were MMP-13, Collagen X and β-catenin; expression of which was normalized to the housekeeping gene β-actin. All primers used are shown in **Table 1**. qRT-PCR was performed



**Figure 4.** Expression of β-catenin mRNA in articular cartilage of DDH and control group at different ages: (A) showed continued high expression of β-catenin in DDH group (B) showed the trend of expression of β-catenin mRNA in two groups. (C and D) Showed higher expression of Collagen X and MMP-13 in DDH model at the ages of 4, 6, and 8 weeks. \*\* $P < 0.01$ .

using ABI PRISM 3730HT Sequence Detection System (ABI, CA, USA), which was programmed to an initial step of 10 min at 95°C for polymerase activity, followed by 40 cycles of 15 s denaturation at 95°C, 15 s annealing at 60°C, and 45 s extension at 72°C. Absence of non-specific PCR products was checked using melting curve and electrophoresis analyses. Reactions were done in triplicate and the average values were used. The relative quantification of target genes was determined using the  $\Delta\Delta CT$  method. Results are expressed as the fold change of relative expression in the DDH model group compared with that in the control group.

#### Statistical analysis

Descriptive statistical analysis was performed using mean values and standard deviations. Data were analyzed using the commercially available statistical software SPSS 16.0 (SPSS,

Chicago, IL, USA) and two-tailed Student's *t* test.  $P < 0.05$  was considered significantly different.

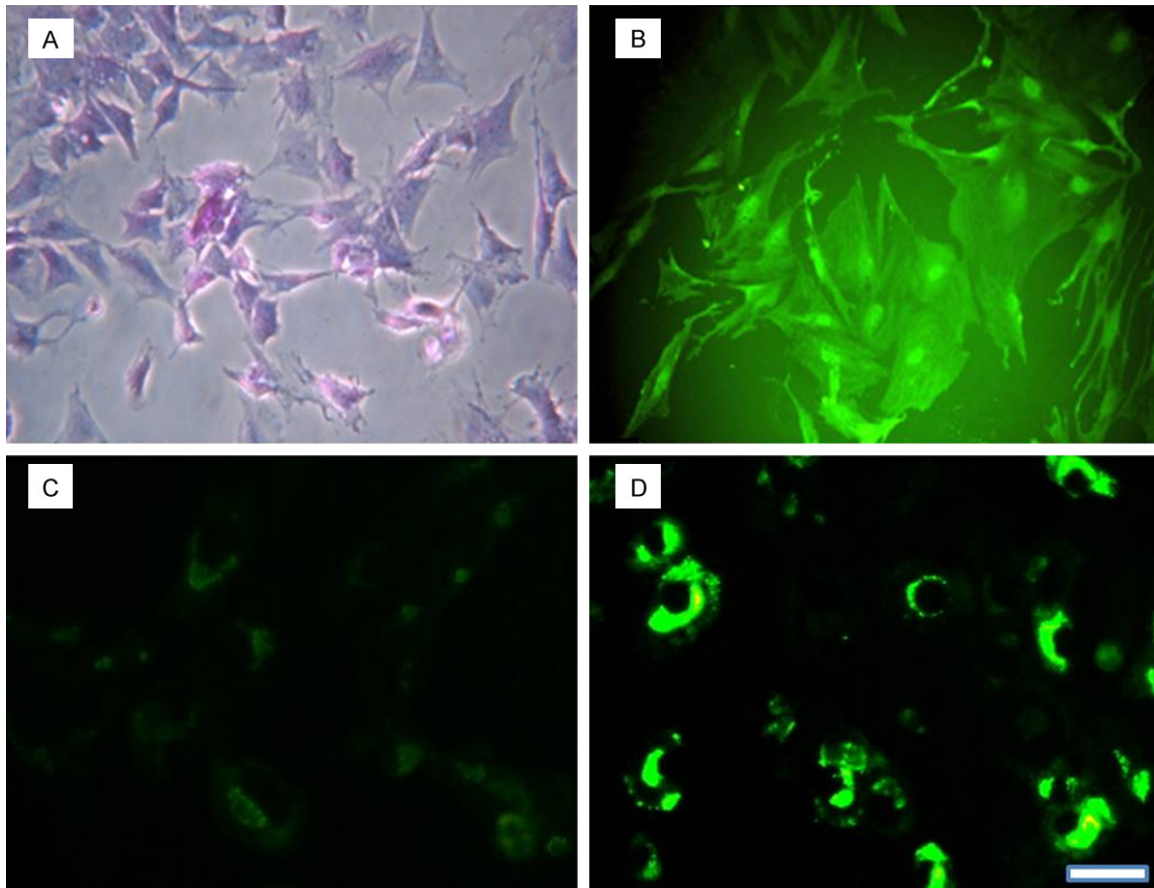
## Results

### Dislocation of the hip in the DDH model

Poor containment between acetabulum and femoral head was found in the DDH model. A flat and underdeveloped femoral head was observed with greater correspondence to the acetabulum in the DDH model (Figure 1B). However, the containment between acetabulum and femoral head was excellent in the control group (Figure 1A).

### Expressional tendency of β-catenin in DDH cartilage and control group is different

To investigate the role of β-catenin in DDH cartilage, we detected expression of β-catenin in



**Figure 5.**  $\beta$ -Catenin signaling was activated in 8-week-old rat chondrocytes in the DDH model group. Primary articular chondrocytes were identified by the presence of toluidine blue staining (A) and collagen II (B). Higher expression of  $\beta$ -catenin protein (D) was observed in the DDH group compared to the control group (C). (scale bar = 75  $\mu$ m).

the DDH model and control group by immunohistochemistry and qRT-PCR at different ages. In the control group, immunohistological analysis revealed that  $\beta$ -catenin was most highly expressed at 2 weeks of age. Thereafter, expression of  $\beta$ -catenin steadily decreased in an age-dependent manner (**Figure 2**). However, in the DDH model, there was no decrease in the expression of  $\beta$ -catenin at different ages (**Figure 3**). Parallel analysis of  $\beta$ -catenin mRNA expression by qRT-PCR indicated that gene transcription followed the same expression pattern as was observed by immunohistochemistry between the two groups (**Figure 4A**) ( $P < 0.01$ ).

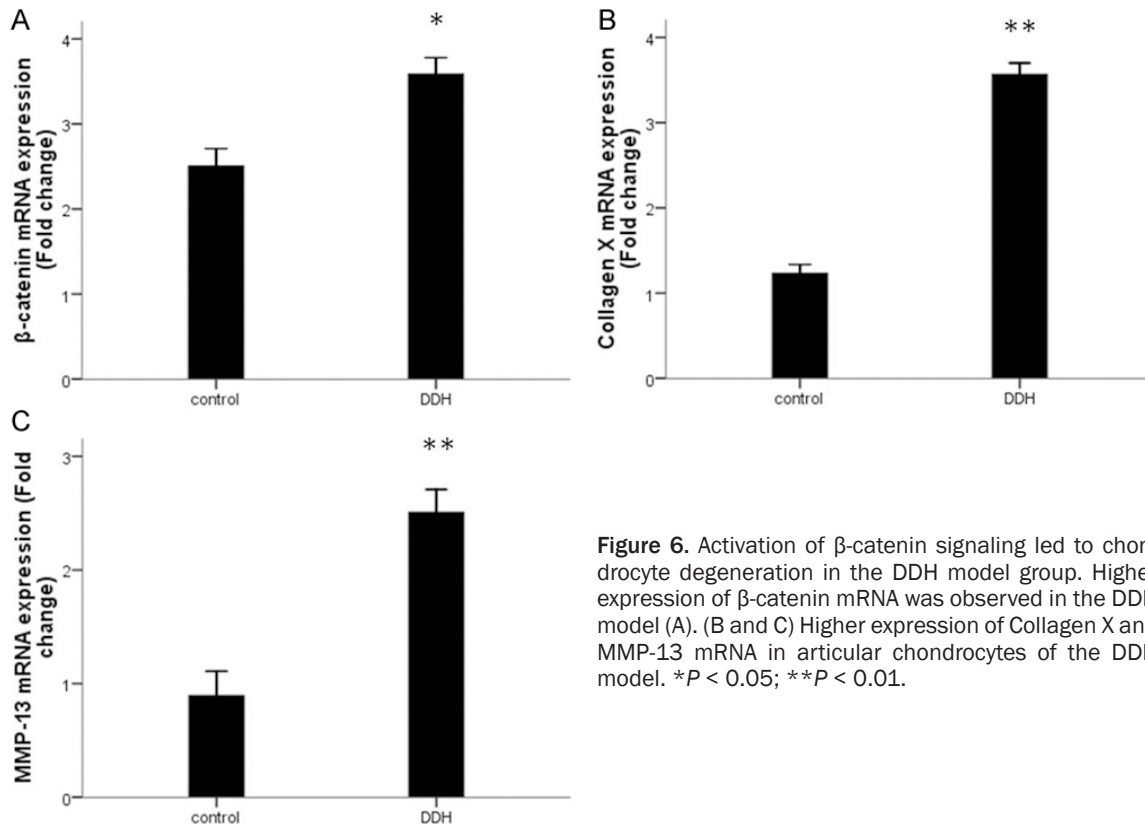
These results indicated that the  $\beta$ -catenin signaling pathway was present, and presumably active, during early cartilage growth but disappeared and did not contribute to processes in adult cartilage. However, high expression of

$\beta$ -catenin in DDH cartilage was continued with increased age (**Figure 4B**).

#### *Articular cartilage degeneration was observed in DDH model*

The chondrocytes of the superficial zone in DDH model cartilage were rounded, aggregated, and formed clusters. The surface of cartilage was irregular and eroded, and cleft formation was seen in DDH model rats (**Figure 3C** and **3D**). However, the surface of the cartilage from the control group was smooth and its chondrocytes were flattened and aligned with the surface.

To determine cartilage degenerative changes in the DDH model, Collagen X and MMP-13, markers of early cartilage degeneration, were detected by qRT-PCR in articular cartilage from the two groups. Fold changes in expression of Collagen X and MMP-13 at different ages in the



**Figure 6.** Activation of β-catenin signaling led to chondrocyte degeneration in the DDH model group. Higher expression of β-catenin mRNA was observed in the DDH model (A). (B and C) Higher expression of Collagen X and MMP-13 mRNA in articular chondrocytes of the DDH model. \* $P < 0.05$ ; \*\* $P < 0.01$ .

two groups are presented in **Figure 4**. Expression of Collagen X and MMP-13 mRNA was increased in the DDH model group at of 4, 6 and 8 weeks of age, and the difference between the two groups at these ages was significant ( $P < 0.01$ ). These results revealed that degenerative changes were observed in early articular cartilage in the DDH model.

#### *Expression of β-catenin was increased in chondrocytes of the DDH model*

Our previous study confirmed that activation of β-catenin led to degenerative changes in articular chondrocytes at the age of 8 weeks [18]. Collagen II and toluidine blue staining were used to identify the chondrocytes (**Figure 5A** and **5B**). We found high expression of β-catenin in DDH cartilage. Therefore, the chondrocytes were cultured from the DDH model and control group at the age of 8 weeks. Expression of β-catenin was detected by immunofluorescence and qRT-PCR. Expression of β-catenin protein and mRNA in chondrocytes from the DDH model was significantly increased (**Figures 5D** and **6A**) ( $P < 0.05$ ). Thus, the β-catenin signaling pathway was activated in chondrocytes from the DDH model.

#### *Increased mRNA expression of Collagen X and MMP-13 in chondrocytes of the DDH model*

We determined the relation between β-catenin and early cartilage degeneration in the DDH model. Considering that high expression of β-catenin chondrocytes of the DDH model at the age of 8 weeks, the expression of the articular chondrocytes early degeneration gene markers were examined. The results are shown in **Figure 6**. Higher mRNA expression of Collagen X and MMP-13 was observed in the DDH model group (**Figure 6B** and **6C**) ( $P < 0.01$ ). These results suggest that activation of β-catenin may lead to early degeneration of chondrocytes in the DDH model group.

#### **Discussion**

DDH is one of the most common deformities in children. Some studies suggest that DDH is one of the predisposing factors for OA and the reasons may be mechanical [6, 19]. As provision of adequate and suitable treatment in early stages of DDH because of progression of early screening and management [8, 24, 25], the relative normal joints in function and image were acquired. However, the incidence rate of



long-term degenerative OA remains higher than in the normal population [6, 26]. These studies indicated that mechanical factors were not the only reasons for transformation of DDH to OA. Given that DDH is a developmental disease, early articular cartilage degeneration may result from abnormal joint development.

The function of the  $\beta$ -catenin signaling pathway in normal bone formation, cartilage development and cartilage degeneration is well established [18, 27, 28]. In the present study, expression of  $\beta$ -catenin in the control group decreased in a age-dependent manner. However, in the DDH model group, continued high expression of  $\beta$ -catenin was observed. It is well known that  $\beta$ -catenin is essential during cartilage development. However,  $\beta$ -catenin promotes degeneration while articular cartilage undergoes maturation. Therefore, continued high expression of  $\beta$ -catenin may result from persistence of developmental factors in articular cartilage in the DDH model. Early cartilage degeneration in the DDH model has been confirmed previously [5, 19]. In our study, morphology of articular cartilage in the DDH model differed from that in the control group. Loss of the smooth surface of articular cartilage and aggregates and clusters of articular chondrocytes were detected. Moreover, surface fibrillation and vertical clefts were observed with increasing age. qRT-PCR revealed that Collagen X and MMP-13 [5, 29, 30], markers of early cartilage degeneration, were upregulated in the articular cartilage of the DDH model compared with the control group at the age of 4, 6 and 8 weeks. Therefore, the present study confirmed that early degeneration of cartilage occurred in the DDH model. These results suggest that there may be dependency between high expression of  $\beta$ -catenin and cartilage degeneration in the DDH model group.

In the present study, chondrocytes were cultured in the DDH model and control group at the age of 8 weeks. Higher expression of  $\beta$ -catenin protein was observed in the DDH model group compared with the control group. Previous studies have confirmed that activation of  $\beta$ -catenin leads to degenerative changes in normal chondrocytes [14, 15, 18]. Given the high expression of  $\beta$ -catenin in DDH cartilage and chondrocytes, we presumed that degenerative changes occurred in DDH articular chondrocytes. To test this hypothesis, we detected

the expression of Collagen X and MMP-13 in articular cartilage chondrocytes. qRT-PCR showed differences in Collagen X and MMP-13 between the two groups, indicating that higher gene expression was involved in the DDH model. Overall, these findings support the idea that articular chondrocytes from DDH model rats display high expression of  $\beta$ -catenin and degenerative changes compared with the control group.

In summary, OA is one of the most common long-term complications of DDH. The molecular mechanism is still unknown. Our study revealed that continued high expression of  $\beta$ -catenin may result from persistence of developmental factors in the cartilage of the DDH model. Finally, high expression of  $\beta$ -catenin led to cartilage degeneration. To the our best of knowledge, this is the first study to investigate the molecular mechanism of transition of DDH to OA.

### Disclosure of conflict of interest

None.

**Address correspondence to:** Dr. Ruixue Ma, Department of Pediatric Orthopaedic, Children's Hospital of Fudan University, 399 Wanyuan Road, 201102, Shanghai, China. Tel: +86-2164931101; Fax: +86-2164931914; E-mail: ruixuemaning@gmail.com

### References

- [1] Senaran H, Bowen JR and Harcke HT. Avascular necrosis rate in early reduction after failed Pavlik harness treatment of developmental dysplasia of the hip. *J Pediatr Orthop* 2007; 27: 192-197.
- [2] Stein-Zamir C, Volovik I, Rishpon S and Sabi R. Developmental dysplasia of the hip: risk markers, clinical screening and outcome. *Pediatr Int* 2008; 50: 341-345.
- [3] Kutlu A, Memik R, Mutlu M, Kutlu R and Arslan A. Congenital dislocation of the hip and its relation to swaddling used in Turkey. *J Pediatr Orthop* 1992; 12: 598-602.
- [4] Greenhill BJ, Hainau B, Ellis RD and el-Sayed RM. Acetabular changes in an experimental model of developmental dysplasia of the hip (DDH). *J Pediatr Orthop* 1995; 15: 789-793.
- [5] Bo N, Peng W, Xinghong P and Ma R. Early cartilage degeneration in a rat experimental model of developmental dysplasia of the hip. *Connect Tissue Res* 2012; 53: 513-520.
- [6] Thomas SR, Wedge JH and Salter RB. Outcome at forty-five years after open reduction and in-



- nominate osteotomy for late-presenting developmental dislocation of the hip. *J Bone Joint Surg Am* 2007; 89: 2341-2350.
- [7] Riccabona M, Schweintzger G, Grill F and Graf R. Erratum to: Screening for developmental hip dysplasia (DDH)-clinically or sonographically? Comments to the current discussion and proposals. *Pediatr Radiol* 2013; 43: 637-40.
- [8] Tschauner C, Furntrath F, Saba Y, Berghold A and Radl R. Developmental dysplasia of the hip: impact of sonographic newborn hip screening on the outcome of early treated de-centered hip joints-a single center retrospective comparative cohort study based on Graf's method of hip ultrasonography. *J Child Orthop* 2011; 5: 415-424.
- [9] Dudkiewicz I, Salai M, Ganel A, Blankstein A and Chechik A. Total hip arthroplasty in patients younger than 30 years of age following developmental dysplasia of hip (DDH) in infancy. *Arch Orthop Trauma Surg* 2002; 122: 139-142.
- [10] Tamamura Y, Otani T, Kanatani N, Koyama E, Kitagaki J, Komori T, Yamada Y, Costantini F, Wakisaka S, Pacifici M, Iwamoto M and Enomoto-Iwamoto M. Developmental regulation of Wnt/beta-catenin signals is required for growth plate assembly, cartilage integrity, and endochondral ossification. *J Biol Chem* 2005; 280: 19185-19195.
- [11] Akiyama H, Lyons JP, Mori-Akiyama Y, Yang X, Zhang R, Zhang Z, Deng JM, Taketo MM, Nakamura T, Behringer RR, McCrea PD and de Crombrughe B. Interactions between Sox9 and beta-catenin control chondrocyte differentiation. *Genes Dev* 2004; 18: 1072-1087.
- [12] Hill TP, Spater D, Taketo MM, Birchmeier W and Hartmann C. Canonical Wnt/beta-catenin signaling prevents osteoblasts from differentiating into chondrocytes. *Developmental Cell* 2005; 8: 727-738.
- [13] Yuasa T, Otani T, Koike T, Iwamoto M and Enomoto-Iwamoto M. Wnt/β-catenin signaling stimulates matrix catabolic genes and activity in articular chondrocytes: its possible role in joint degeneration. *Lab Invest* 2008; 88: 264-274.
- [14] Chen M, Zhu M, Awad H, Li TF, Sheu TJ, Boyce BF, Chen D and O'Keefe RJ. Inhibition of beta-catenin signaling causes defects in postnatal cartilage development. *J Cell Sci* 2008; 121: 1455-1465.
- [15] Zhu M, Tang D, Wu Q, Hao S, Chen M, Xie C, Rosier RN, O'Keefe RJ, Zuscik M and Chen D. Activation of beta-catenin signaling in articular chondrocytes leads to osteoarthritis-like phenotype in adult beta-catenin conditional activation mice. *J Bone Miner Res* 2009; 24: 12-21.
- [16] Lories RJ, Peeters J, Bakker A, Tylzanowski P, Derese I, Schrooten J, Thomas JT and Luyten FP. Articular cartilage and biomechanical properties of the long bones in Frzb-knockout mice. *Arthritis Rheum* 2007; 56: 4095-4103.
- [17] Jones SE and Jomary C. Secreted Frizzled-related proteins: searching for relationships and patterns. *Bioessays* 2002; 24: 811-820.
- [18] Ning B, Wang P, Pei X, Kang Y, Song J, Wang D, Zhang W and Ma R. Dual function of beta-catenin in articular cartilage growth and degeneration at different stages of postnatal cartilage development. *Int Orthop* 2012; 36: 655-664.
- [19] da Silva MA, Yamada N, Clarke NM and Roach HI. Cellular and epigenetic features of a young healthy and a young osteoarthritic cartilage compared with aged control and OA cartilage. *J Orthop Res* 2009; 27: 593-601.
- [20] Li J, Anemaet W, Diaz MA, Buchanan S, Tortorella M, Malfait AM, Mikecz K, Sandy JD and Plaas A. Knockout of ADAMTS5 does not eliminate cartilage aggrecanase activity but abrogates joint fibrosis and promotes cartilage aggrecan deposition in murine osteoarthritis models. *J Orthop Res* 2011; 29: 516-22.
- [21] Chang JK, Chang LH, Hung SH, Wu SC, Lee HY, Lin YS, Chen CH, Fu YC, Wang GJ and Ho ML. Parathyroid hormone 1-34 inhibits terminal differentiation of human articular chondrocytes and osteoarthritis progression in rats. *Arthritis Rheum* 2009; 60: 3049-3060.
- [22] Wang X, Manner PA, Horner A, Shum L, Tuan RS and Nuckolls GH. Regulation of MMP-13 expression by RUNX2 and FGF2 in osteoarthritic cartilage. *Osteoarthritis Cartilage* 2004; 12: 963-973.
- [23] Plaas A, Osborn B, Yoshihara Y, Bai Y, Bloom T, Nelson F, Mikecz K and Sandy JD. Aggrecanolytic activity in human osteoarthritis: confocal localization and biochemical characterization of ADAMTS5-hyaluronan complexes in articular cartilages. *Osteoarthritis Cartilage* 2007; 15: 719-34.
- [24] Riccabona M, Schweintzger G, Grill F and Graf R. Screening for developmental hip dysplasia (DDH)-clinically or sonographically? Comments to the current discussion and proposals. *Pediatr Radiol* 2013; 43: 637-40.
- [25] Bhuyan BK. Outcome of one-stage treatment of developmental dysplasia of hip in older children. *Indian J Orthop* 2012; 46: 548-555.
- [26] Terjesen T and Gunderson RB. Radiographic evaluation of osteoarthritis of the hip: an interobserver study of 61 hips treated for late-detected developmental hip dislocation. *Acta Orthop* 2012; 83: 185-189.
- [27] Day TF, Guo X, Garrett-Beal L and Yang Y. Wnt/beta-catenin signaling in mesenchymal

- progenitors controls osteoblast and chondrocyte differentiation during vertebrate skeletogenesis. *Dev Cell* 2005; 8: 739-750.
- [28] Clevers H. Wnt/beta-catenin signaling in development and disease. *Cell* 2006; 127: 469-480.
- [29] Orlandi A, Oliva F, Taurisano G, Candi E, Di Lascio A, Melino G, Spagnoli LG and Tarantino U. Transglutaminase-2 differently regulates cartilage destruction and osteophyte formation in a surgical model of osteoarthritis. *Amino Acids* 2008; 36: 755-763.
- [30] Moldovan F, Pelletier JP, Hambor J, Cloutier JM and Martel-Pelletier J. Collagenase-3 (matrix metalloprotease 13) is preferentially localized in the deep layer of human arthritic cartilage in situ: in vitro mimicking effect by transforming growth factor beta. *Arthritis Rheum* 1997; 40: 1653-1661.