

Management of upper ureteral stones exceeding 15 mm in diameter: Shock wave lithotripsy versus semirigid ureteroscopy with holmium:yttrium–aluminum–garnet laser lithotripsy

SAGE Open Medicine

Volume 4: 1–7

© The Author(s) 2017

Reprints and permissions:

sagepub.co.uk/journalsPermissions.nav

DOI: 10.1177/2050312116685180

journals.sagepub.com/home/smo

Hamdy Aboutaleb, Mohamed Omar, Shady Salem
and Mohamed Elshazly

Abstract

Objectives: We conducted a retrospective study to evaluate the efficacy and outcome of shock wave lithotripsy versus semirigid ureteroscopy in the management of the proximal ureteral stones of diameter exceeding 15 mm.

Methods: During the 2009–2014 study period, 147 patients presenting with the proximal ureteral stones exceeding 15 mm in diameter were treated. Both shock wave lithotripsy and ureteroscopy with laser lithotripsy were offered for our patients. A 6/8.9 Fr semirigid ureteroscope was used in conjunction with a holmium:yttrium–aluminum–garnet laser. The stone-free rate was assessed at 2 weeks and 3 months post-treatment. All patients were evaluated for stone-free status, operation time, hospital stay, perioperative complications, and auxiliary procedures.

Results: Of the 147 patients who took part in this study, 66 (45%) had undergone shock wave lithotripsy and 81 (55%) underwent ureteroscopy. At the 3-month follow-up, the overall stone-free rate in the shock wave lithotripsy group was 39/66 (59%) compared to 70/81 (86.4%) in the ureteroscopic laser lithotripsy group. Ureteroscopic laser lithotripsy achieved a highly significant stone-free rate ($p=0.0002$), and the mean operative time, auxiliary procedures, and postoperative complication rates were comparable between the two groups.

Conclusion: In terms of the management of proximal ureteral stones exceeding 15 mm in diameter, ureteroscopy achieved a greater stone-free rate and is considered the first-line of management. Shock wave lithotripsy achieved lower stone-free rate, and it could be used in selected cases.

Keywords

Calculi, ureter, ureteroscopy, lithotripsy

Date received: 5 July 2016; accepted: 27 November 2016

Introduction

Urinary stones, one of the most common urological diseases, require active treatment due to its high prevalence, high recurrence rates, and various complications.^{1,2} There are many therapeutic approaches for the treatment, that is, complete stone clearance with minimal patient morbidity, of ureteral stones. The most commonly used approaches include shock wave lithotripsy (SWL), ureteroscopy (URS), percutaneous nephrolithotripsy, laparoscopic ureterolithotomy, and open ureterolithotomy.³ However, there is a lack of definite evidence-based options for managing large proximal ureteral stones.³

Moreover, the optimal choice of treatment depends on various factors, including stone size, composition and location, clinical factors, equipment availability, and surgeon capability.⁴ The European Association of Urology guidelines

Department of Urology, Menoufia University Hospital, Shebin El Kom, Egypt

Corresponding author:

Hamdy Aboutaleb, Department of Urology, Menoufia University Hospital, Shebin El Kom, 32714, Menoufia, Egypt.

Email: hamdyaboutaleb@yahoo.com



Creative Commons Non Commercial CC-BY-NC: This article is distributed under the terms of the Creative Commons Attribution-NonCommercial 3.0 License (<http://www.creativecommons.org/licenses/by-nc/3.0/>) which permits non-commercial use, reproduction and distribution of the work without further permission provided the original work is attributed as specified on the SAGE and Open Access pages (<https://us.sagepub.com/en-us/nam/open-access-at-sage>).

recommend SWL or ureteroscopic laser lithotripsy (URSL) as the first-line treatment for proximal ureteral stones.⁵

Both these procedures are preferred because they are less invasive than other approaches, have low complication rates, and are well tolerated by patients. In general, SWL is preferred by both patients and physicians.^{6–8}

However, in the past two decades, the technological advancements achieved in ureteroscope manufacturing and laser lithotripsy have considerably improved the outcomes of treatment of proximal ureteral stones exceeding 10 mm in diameter. Thus, this study aimed at evaluating the outcomes, safety, efficacy, and complications associated with SWL versus URSL in the management of proximal ureteral calculi exceeding 15 mm in diameter.

Patients and methods

A total of 147 patients presented to the Urology Clinic with proximal ureteral stones exceeding 15 mm in diameter between 2009 and 2014. The patients had undergone either SWL or URSL and were classified into two groups, SWL (Group A) and URSL (Group B). The proximal ureter was defined as the part below the ureteropelvic junction to the superior aspect of the sacroiliac joint. The patient's age, sex, and stone size were determined for each group. All patients who presented with single proximal radiopaque ureteral stone ≥ 15 mm revealed on plain abdominal film or non-contrast computed tomography (CT)–Kidney, Ureter, Bladder (KUB) study were invited to participate in the study. Following the classification by the Society for Fetal Urology, the degree of hydronephrosis was categorized as mild (grade 1), moderate (grades 2–3), and severe (grade 4).⁹

Exclusion criteria

On the other hand, patients with a history of any intervention on the corresponding ureter, coagulopathy diseases, pregnancy, recent active infection, and urinary tract abnormalities and children were excluded from the study. Morbid obese patients, severe hydronephrosis, and elevated serum creatinine (≥ 2 mg/dL) were excluded from SWL group. SWL failure cases shifted to URSL procedure were excluded from the current URSL group.

Preoperative routine laboratory tests were performed. In addition to urine culture and sensitivity, all the patients underwent KUB (Figure 1(a)), abdominopelvic ultrasonography (Figure 1(b)), and CT without contrast.

SWL (Group A) group

Patients with in situ SWL were treated using Siemens Lithostar Modularis (Global Siemens Healthcare Headquarters, Siemens AG, Erlangen, Germany). All patients were premedicated with intravenous midazolam and fentanyl. A fluoroscopic image was used to successfully localize the calculus. The total number of

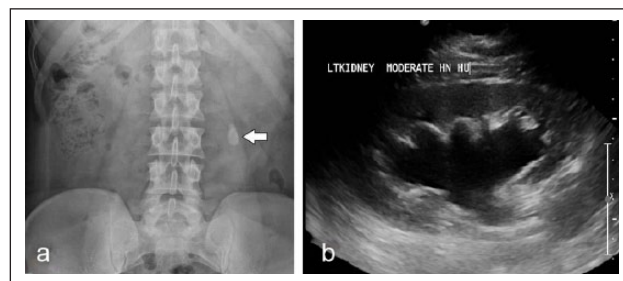


Figure 1. (a) KUB X-ray shows left upper ureteric calculus at the level of L4. (b) Renal ultrasound shows moderate dilatation of pelvicalyceal system of the same patient.

shock waves and the kilo voltage used were determined individually by the urologist. The voltage used ranged from 12 to 21 kV, and the maximum number of shocks was 4000 per session. Persistent post-SWL pain was indication for double J stent insertion, which was removed after complete stone clearance. The patients were treated on an outpatient basis.

Follow-up

Post-treatment abdominal X-ray KUB was obtained at 2 weeks and 3 months after the SWL, and CT-KUB was requested in selected cases. The cases of inadequate fragmentation or incomplete clearance noted at the X-ray performed at the 2-week follow-up were retreated. If no stone breakage had occurred after three SWL treatment sessions, then the case was considered a SWL failure, and the patient was shifted to URSL. The characteristics of patient age, sex, and stone size for the different treatments were recorded and tabulated.

URS (Group B) group

The procedure was performed under general/spinal anesthesia, using semirigid ureteroscope 6/8.9 Fr (Richard Wolf Medical Instruments Corporation, IL, USA). Our standard technique for ureteroscopic treatment of proximal ureteral calculi includes cystourethroscopy with placement of a 0.035-inch floppy tip guide wire past the stone (glide wire when necessary) to maintain access and for placement of a safety wire with a direct vision. For URSL, holmium:yttrium–aluminum–garnet (YAG) laser 365–550 micron fibers (Mega pulse stone laser, Richard Wolf Medical Instruments Corporation) was used to disintegrate the stone (Figure 2(d)). The laser apparatus settings were adjusted to produce 200–4000 mJ with the pulse frequency of 3–25 Hz. Low pressure continuous flow irrigation and/or intermittent manual pumping of irrigant was used to maintain a clear ureteroscopic view when the appropriate holmium:YAG laser was used. N-Trap baskets (Cook Urological Inc., IN, USA) (Figure 2(b) and (c)) were used in all cases to prevent stone migration. All significant gravels were removed using N-Gage basket (Cook Urological Inc.; Figure 2(a)). All patients

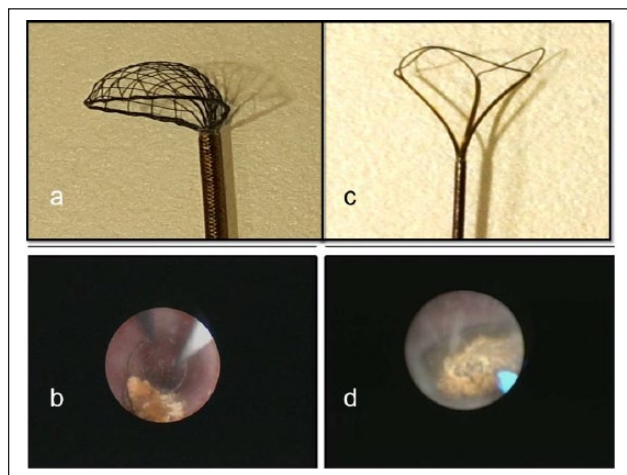


Figure 2. (a) Postoperative URSL KUB X-ray of the same patient with DJ stent in situ and stone free and (b) postoperative renal US shows resolution of hydronephrosis of the same patient.

were treated on a day-case basis, and all procedures were scheduled as outpatient procedures unless any complications occurred during the procedure. At the end of the procedure, internal ureteric stents were optional in some cases. If excessive manipulation had occurred, mucosal edema or injury had developed, residual fragments are seen, a double J ureteric stent was placed for 2–4 weeks. The double J stent was removed after complete stone clearance.

The stone chemical analysis was not performed for all patients. The data pertaining to the stone-free status, operative time, perioperative complications, and the need for any additional procedure were recorded for both groups, and the findings were subsequently analyzed and compared.

Postoperative follow-up

All patients underwent postoperative abdominal radiography at our institution and were available for follow-up. All patients attended 2-week and 3-month follow-ups, which consisted of imaging studies. More specifically, the sessions included KUB (Figure 3(a)) and ultrasound (US; Figure 3(b)). The US, KUB were used as a control for most of the patients at both follow-ups while some patients also underwent non-contrast CT-KUB for radiolucent stones until the stone-free diagnosis was made. In case of procedure failure, laparoscopic ureterolithotomy was considered. After the initial SWL session or URS, stone-free status was defined as the radiologic absence of stones, or asymptomatic patient with stone fragments <3 mm.

Statistical procedures

The data pertaining to both groups were statistically analyzed using SPSS (Statistical Package for Social Sciences) program version 21 for MS Windows and Epi info program

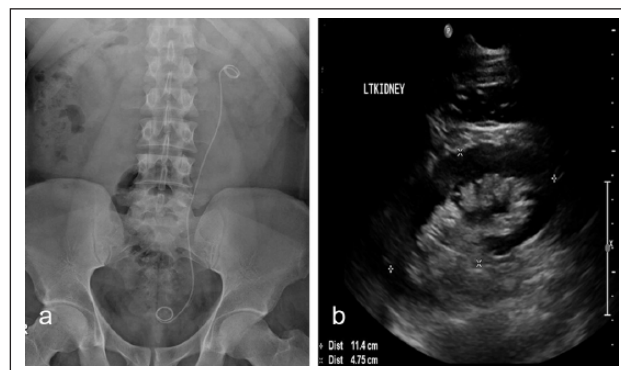


Figure 3. (a) N-Trap basket used during URSL to prevent stone migration during the procedure, (b) endoscopic image shows the N-Trap basket preventing the stone from migration during URSL, (c) image of the N-Gage basket which used during URSL to remove stone fragments, and (d) endoscopic image of laser during disintegration of the stone during URSL.

version. In all analyses, $p < 0.05$ was considered to denote statistical significance. Chi-square test was also performed for qualitative variable analysis. Fisher exact test for 2×2 tables was conducted when the expected cell count in more than 25% of cases was less than 5. Student's t -test was performed on all normally distributed quantitative variables in order to measure the mean and standard deviation (SD). All data were tested with Kolmogorov–Smirnov Z test and were found normally distributed. Thus, the results could be presented as mean \pm SD, and the parametric tests could be performed in order to establish associations.

Results

Of the 147 patients considered in this study, 101 (68.8%) patients were males and 46 (31.2%) were females. Mean age at surgery was 41.6 years (range, 25–72 years). In addition, 90 (61%) patients presented with pain, 35 (23.8%) with urinary tract infections (UTIs), 20 (13.6%) with hematuria, and 2 (1.3%) patients presented with solitary kidney. Reviewing the renal US reports for hydronephrosis is done. US showed mild hydronephrosis in 30/26, moderate in 26/40, and severe in 10/15 in SWL and URSL, respectively. The patients presented with severe hydronephrosis underwent further evaluation by renal isotopes. Five patients had renal functions between 10% and 20%, 16 between 20% and 30%, and 4 more than 30% was detected. Those groups need more close follow-up by renal isotope scanning.

During the study period, 66 (44.9%) patients (46 males and 20 females) underwent SWL and were grouped into Group A. Their mean age was 36.7 ± 13.5 (range, 25–72) years (Table 1). All stones were radiopaque in KUB X-ray. None of these patients had double J stenting pre-SWL. The mean operative time was 48 ± 13.2 min (range, 38–65 min). At the 2-week follow-up, 35 patients (53%) were found to be stone free, and this percentage increased to 39 patients (59%) at

Table 1. Preoperative data in both SWL and URSL groups (patient and stone characteristics).

Procedure		SWL	URSL	Test of significance	p-value
No. and percentage of cases		66	81		
Age (years)	Mean	43.6 ± 2	44.3 ± 16.7	Mann–Whitney test:	0.74
	Range	25–72	28–68	0.34	
Sex	Male	46 (69.7%)	55 (68%)	Chi-square test: 0.05	0.82
	Female	20 (30.3%)	26 (32%)		
Average stone size (mm)	Mean (mm)	17.9 ± 2	18.2 ± 3	t-test: 0.69	0.49
	Range (mm)	15–21	15–27		
Side	RT	42 (63.6%)	30 (37%)	Chi-square test: 10.3	0.001
	LT	24 (36.4%)	51 (63%)		

SWL: shock wave lithotripsy; URSL: ureteroscopic laser lithotripsy; RT: Right; LT: Left.

There is high statistical significant difference between SWL and URSL regarding the age, stone size, and the side (p -value < 0.01) while there is no statistical significance difference between them regarding gender (p -value > 0.05).

Table 2. Postoperative data in both SWL and URSL groups.

		SWL (Group A)	URSL + Laser (Group B)	Test of significance	p-value
Operating time (min)	Mean	48 ± 13.2	75 ± 24.3	t-test: 8.1	0.0001
	Range	38–65	55–98		
Stone free	At 2 weeks	35/66	62/81	Chi-square test: 9.86	0.003
		53%	75.3%		
	At 3 months	39/66	70/81	Chi-square test: 14.17	0.0002
		59%	86.4%		
Hospital stay (h)	Mean	6 ± 0.3	10 ± 8.5	t-test: 3.36	0.001
	Range	6–10	8–36		
Auxiliary stenting	No	18	22	Chi-square test: 0.00	0.96
	Percentage	27.3%	27.2%		
Complications	Hematuria	36	26	Chi-square test: 6.23	0.013
		54.5%	32%		
	Steinstrasse	23	3	Fisher exact test: 0.33	1
		34.8%	3.7%		
	Perforation	–	6	Fisher exact test: 3.38	0.03
			7.4%		
	Postoperative colic	32	8	Chi-square test: 1.68	0.19
		48.5%	9.9%		

SWL: shock wave lithotripsy; URSL: ureteroscopic laser lithotripsy.

There is statistical significant difference between SWL and URSL regarding all hematuria and perforation complications (p -value < 0.05) while there is no statistical significance difference between them regarding steinstrasse and postoperative colic (p -value > 0.05).

There is high statistical significant difference between SWL and URSL regarding all variables (p -value < 0.01).

the last follow-up, which was conducted after the second and third sessions of SWL. A total of 31 (47%) patients required the second and third sessions. The 27 cases (41%) of failed SWL after third session were shifted to URSL and not included in our URSL study group. SWL complications were observed in 23 (34.8%) patients in which steinstrasse was managed by alpha blockers (Tamsulosin, 0.4 mg). This treatment succeeded in 14 cases while the remaining 9 were shifted to URSL. Postoperative renal colic occurred in 32 patients (48.5%) and 18 patients had persistent colic and were indicated for DJ stenting; the other 14 responded to non-steroidal anti-inflammatory drugs (NSAIDs) and alpha blockers. Gross hematuria was observed in 36 cases (54.5%)

and was managed conservatively by hemostatic drugs and intravenous hydration (Table 2).

During the study period, 81 (55.1%) patients (55 males and 26 females) underwent URSL and were grouped as Group B, in which stone disintegration was attempted using the holmium laser. The mean age in this group was 44.3 years (range, 28–68 years). Radiolucent stones were reported in 14 patients and 67 had radiopaque stones. The average operative time was 75 ± 24 min (range, 55–98 min). Incomplete stone clearance and complicated cases were characterized by false passage or perforation. Stenting after URS and stone fragmentation by holmium laser was performed in 22 patients, but none of these patients had double J stenting

preoperatively. In 64 (80%) of the cases, the average length of hospital stay was 12 h while the remaining 17 patients (20%) stayed for more than 24 h. In 62 (75.3%) patients, the single endoscopic procedure was sufficient to achieve stone-free status at the 2-week postoperative follow-up while this number increased to 70 (86.4%) after 3 months. Two cases were presented with anuria due to single kidney and impacted proximal ureteral calculus. Double J stent was inserted up to the improvement of renal functions and later the stone was completely removed in one session with DJ stent reinsertion. No cases were reported with stone migration to the kidney. The failed cases in this group may be due to stone impaction surrounded with edema, ureteric kinks, or ureteric strictures. Of the failure cases, 11 (13.6%) patients underwent laparoscopic ureterolithotomy, while 26 patients (32%) experienced short-term complications in the form of hematuria. Ureteric injury and extravasation occurred in six cases (7.4%). They were managed by the insertion of DJ.

Discussion

Although SWL and URS remain the most common modalities for the treatment of proximal ureteral stones, there is still an ongoing debate among the academicians and medical practitioners regarding the best treatment modality.¹⁰ SWL is the most prevalent intervention for upper ureteral stones;^{11,12} the success rates of this treatment in stones <10 mm range from 85% to 93%.⁸ However, its efficacy declines when the stone size is >12 mm and falls below 60%.^{13,14} Thus, the need for repeated treatments in patients with large stones is the most important drawback of SWL.

In our study, the initial stone-free rate (SFR) for the URS and SWL treatment was 86.2% and 53%, respectively. This is similar to the findings of Salem,¹⁵ who reported that the initial SFRs for URS and SWL, when applied to stones ≥ 1 cm, were 88% and 60%, respectively.¹⁵ However, in our study, at the subsequent follow-up, the SWL group achieved only 59% SFR. This may be because our study included patients presenting with stones exceeding 15 mm in diameter; thus, making it difficult to compare these findings with the literature and provide a definitive assessment of the two treatment modalities.

However, it should be noted that SWL has lower invasiveness despite the potential need for repeated treatments and greater failure rate compared to URS. Due to its lesser invasiveness, SWL was performed in the outpatient setting as a day-care procedure with the patient under sedation. The retreatment rate after SWL was high (85%) because of the presence of large stones (≥ 15 mm).¹⁶

In our series, the invasive intervention rate after SWL was higher for proximal ureteral calculi exceeding 15 mm. The treatment failed to clear the stone in 27 patients (41%) even after three sessions of SWL. These patients required further interventions in the form of repeated SWL and/or URS. The disadvantages associated with less invasive surgery include

more follow-up visits, more follow-up X-ray exposure, and relatively more cost with less than 50% stone clearance.

Previous reports correlated the success rate of SWL treatments for stones with the size of the stones. They have reported a significant decline in the success rate of the treatment when the stones exceeded ≥ 12 mm. In general, it can be said that a large stone will be associated with more shock waves per treatment session and an increase in the need for auxiliary procedures following SWL.^{17,18}

Stone composition affects SWL results of fragmentation and subsequent elimination. Contrary to calcium oxalate dihydrate stones, which have a better coefficient of fragmentation and thus respond well to SWL, cystine and calcium oxalate monohydrate stones are relatively resistant to SWL treatment.¹⁹ However, it is difficult to predict the response of a stone to SWL based on the pretreatment imaging studies. Since stone analysis for biochemical structures was not performed for all cases, it was not possible to correlate stone composition and response to SWL. Therefore, a prospective randomized study with a larger number of patients is encouraged in order to verify these results.

The incidence of steinstrasse following lithotripsy is about 6%. When the fragments are smaller than 2 mm and there are no complications, conservative treatment should be offered for at least the first few weeks. In our study, one-third of the patients who underwent SWL suffered from steinstrasse. Conservative management succeeded in 14 patients (61%) and failed in 9 patients (39%), who were then shifted to URS.

The recent advances in telescope manufacturing, the introduction of small-caliber semirigid ureteroscope, and the development of effective intracorporeal lithotripsy methods have resulted in improved SFRs following the URS treatment while reducing the complication rates. This has made ureteroscopic management of proximal ureteral stones more effective.²⁰

Recently, the use of the holmium laser in combination with URS has resulted in marked improvements in the patient outcomes following the treatment of proximal ureteral calculi in terms of efficacy and safety.²¹ Holmium:YAG laser is used for fragmenting the stones and the fragment retrieval with baskets. The main disadvantage of this method is its high cost. Empirical evidence indicates that, in the management of larger stones (>10 mm), URS has superior efficacy and higher SFRs compared with SWL.²² Nonetheless, it is associated with higher morbidity as the procedure needs to be performed in the operating theater, with the patient under spinal or general anesthesia, thus requiring a well-trained endourologist. Owing to its greater complexity, URS might also be associated with a greater risk of complications.²² Despite these notable shortcomings, some urologists recommend URS as the first-line treatment for ureteral stones exceeding 10 mm in diameter.²³

In this study, in 11 patients (13.6%), stones could not be manipulated by URS. The failure of URS was attributed to

tortuosity of the ureter, angulations, and edema around the stone. In some cases, laser was used to ablate this edema and assist with stone exposure, thus allowing for stone fragmentation and removal to be performed. In this study, the need to repeat the procedure or to proceed with laparoscopic ureterolithotomy was considered a failure of the URS.

Proximal stone migration is a potential complication during the manipulation of proximal ureteral calculi.^{24,25} This complication was avoided in our study using N-Trap basket, which was proven effective in preventing migration.

Recently, the introduction of holmium:YAG laser has improved the URS SFR while decreasing the risk of intraoperative complications.^{26,27} The holmium:YAG laser can fragment all types of stones by delivering energy through small-diameter quartz fibers through the small size ureteroscopes. Dusting stones with laser allows the treatment of proximal ureteral calculi exceeding 15 mm without the burdensome process of fragment removal and with a safe and effective outcome.^{28–30}

In order to assist with the passage of fragments and avoid postoperative pain and colic, DJ stenting was used postoperatively in 19 patients. It also helped with drainage of previously obstructed kidneys. URSL with DJ stenting is a single-session procedure with a high success rate in relieving obstruction and removal of stones exceeding 15 mm in diameter.

Authors of extant studies have reported variable outcomes of SWL and URS, even though both techniques employ the latest innovations. We found URSL treatment modality highly effective, with statistically significant differences in the patient outcomes. However, using URSL in the treatment of larger stones (≥ 15 mm) is still advantageous compared to SWL due to its higher stone clearance ($>86\%$).

Finally, each treatment modality is characterized by particular advantages and disadvantages, with a wide range of factors influencing the choice of treatment. The urologists advocating for SWL typically base their preference on its noninvasiveness, minimal anesthetic requirements, low morbidity, and acceptable efficacy. On the other hand, urologists in favor of URSL claim that, although it is minimally invasive procedure, unlike SWL, the initial treatment results in a greater success rate. In practice, the treatment modality is also affected by the access (or lack thereof) to a nearby lithotripter and surgeon preference, which are important factors in an endourologic procedure. Finally, when choosing a treatment option, patient preference should always be a great concern. Some patients might have some fears regarding the anesthesia required and invasiveness of URSL. Others might prefer to have the stone removed and the pain alleviated more rapidly, without the potential need for multiple treatment sessions and a prolonged stone clearance period, which are common in SWL. Thus, the required equipment availability, surgeon's experience with both modalities, and patient preference will ultimately determine the treatment choice.

There are several limitations of our study. First of all, our study is a retrospective study and based on a small number of

patients. In the literature, the SFR and clinically insignificant residual fragment (CIRF) terms have not been defined and standardized yet. In our study, we used CIRF term for stones <3 mm. Moreover, the standardization of surgical interventions is very difficult because skills may vary between surgeons. The options of management were decided after a discussion between surgeon and the patient. The significance in SFR between SWL and URSL can be attributed to the fact that proximal ureteral stones treated with URSL did not vary significantly with size, whereas it is negatively correlated with stone size in SWL patients.

Renal isotopes are done in 25 cases with severe hydronephrosis. The isotope studies were optional according to surgeon preferences. Future studies are required to correlate the hydronephrosis to the SFR status and the split renal function before and after the procedure.

Conclusion

URS achieved a greater SFR in patients with proximal ureteral calculi exceeding 15 mm in diameter and is more efficacious. Comparatively, SWL achieved less acceptable SFRs and more retreatment rate. Thus, we do not recommend SWL for proximal ureteral stones exceeding 15 mm in diameter as a first option.

Declaration of conflicting interests

The author(s) declared no potential conflicts of interest with respect to the research, authorship, and/or publication of this article.

Ethical approval

All procedures performed in this study were in accordance with the ethical standards of the Institution and/or National Research Committee and with the 1964 Declaration of Helsinki and its later amendments or comparable ethical standards.

Funding

The author(s) received no financial support for the research, authorship, and/or publication of this article.

Informed consent

Informed consent was obtained from all the patients.

Research ethics

This study was approved as a clinical study by the Ethical Board of Urology, Menoufia University Hospital, Shibin El Kom, Egypt. Each author certifies that his or her institution approved the human protocol for the investigation that all investigations were concluded in conformity with ethical principles of research and that informed consent was obtained for participation in the study.

References

1. Papadoukakis S, Stolzenburg J-U and Truss MC. Treatment strategies of ureteral stones. *EAU-EBU Update Ser* 2006; 4:

- 184–190, http://eu-acme.org/europeanurology/upload_articles/Treatment.pdf
2. Ahn SH, Oh TH and Seo Y III. Can a dual-energy computed tomography predict unsuitable stone components for extracorporeal shock wave lithotripsy? *Korean J Urol* 2015; 56(9): 644–649.
3. Rabani S and Moosavizadeh A. Management of large proximal ureteral stones: a comparative clinical trial between transureteral lithotripsy (TUL) and shock wave lithotripsy (SWL). *Nephrourol Mon* 2012; 4(3): 556–559.
4. Kijvikai K, Haleblan GE, Preminger GM, et al. Shock wave lithotripsy or ureteroscopy for the management of proximal ureteral calculi: an old discussion revisited. *J Urol* 2007; 178(4 Pt 1): 1157–1163.
5. Turk CKT, Petrik A and Sarica K. Guidelines on urolithiasis 2013, <http://www.uroweb.org/publications/eau-guidelines>
6. Deem S, Defade B, Modak A, et al. Percutaneous nephrolithotomy versus extracorporeal shock wave lithotripsy for moderate sized kidney stones. *Urology* 2011; 78: 739–743.
7. Preminger GM, Tiselius HG, Assimos DG, et al. 2007 guideline for the management of ureteral calculi. *J Urol* 2007; 178: 2418–2434.
8. Wiesenthal JD, Ghiculete D, D'A Honey RJ, et al. A comparison of treatment modalities for renal calculi between 100 and 300 mm²: are shockwave lithotripsy, ureteroscopy, and percutaneous nephrolithotomy equivalent? *J Endourol* 2011; 25: 481–485.
9. Fernbach SK, Maizels M and Conway JJ. Ultrasound grading of hydronephrosis: introduction to the system used by the Society for Fetal Urology. *Pediatr Radiol* 1993; 23: 478–480.
10. Bader MJ, Eisner B, Porpiglia F, et al. Contemporary management of ureteral stones. *Eur Urol* 2012; 61: 746–772.
11. Ehreth JT, Drach GW, Arnett ML, et al. Extracorporeal shock wave lithotripsy: multicenter study of kidney and upper ureter versus middle and lower ureter treatments. *J Urol* 1994; 152(5 Pt 1): 1379–1385.
12. Liong ML, Clayman RV, Gittes RF, et al. Treatment options for proximal ureteral urolithiasis: review and recommendations. *J Urol* 1989; 141(3): 504–509.
13. Youssef RF, El-Nahas AR, El-Assmy AM, et al. Shock wave lithotripsy versus semirigid ureteroscopy for proximal ureteral calculi (<20 mm): a comparative matched-pair study. *Urology* 2009; 73(6): 1184–1187.
14. Wu CF, Shee JJ, Lin WY, et al. Comparison between extracorporeal shock wave lithotripsy and semirigid ureterorenoscopy with holmium:YAG laser lithotripsy for treating large proximal ureteral stones. *J Urol* 2004; 172(5 Pt 1): 1899–1902.
15. Salem HK. A prospective randomized study comparing shock wave lithotripsy and semirigid ureteroscopy for the management of proximal ureteral calculi. *Urology* 2009; 74: 1216–1221.
16. El-Assmy A, El-Nahas AR, Youssef RF, et al. Impact of the degree of hydronephrosis on the efficacy of in situ extracorporeal shock-wave lithotripsy for proximal ureteral calculi. *Scand J Urol Nephrol* 2007; 41: 208–213.
17. Shiroyanagi Y, Yagisawa T, Nanri M, et al. Factors associated with failure of extracorporeal shock-wave lithotripsy for ureteral stones using Dornier lithotripter U/50. *Int J Urol* 2002; 9: 304–307.
18. Park H, Park M and Park T. Two-year experience with ureteral stones: extracorporeal shockwave lithotripsy v ureteroscopic manipulation. *J Endourol* 1998; 12: 501–504.
19. Galvin D and Pearle MS. The contemporary management of renal and ureteric calculi. *BJU Int* 2006; 98(6): 1283–1288.
20. Lee YH, Tsai JY, Jiaan BP, et al. Prospective randomized trial comparing shock wave lithotripsy and ureteroscopic lithotripsy for management of large upper third ureteral stones. *Urology* 2006; 67: 480–484.
21. Lam JS, Greene TD and Gupta M. Treatment of proximal ureteral calculi: holmium:YAG laser ureterolithotripsy versus extracorporeal shock wave lithotripsy. *J Urol* 2002; 167(5): 1972–1976.
22. Tiselius HG. Removal of ureteral stones with extracorporeal shock wave lithotripsy and ureteroscopic procedures. What can we learn from the literature in terms of results and treatment efforts? *Urol Res* 2005; 33(3): 185–190.
23. Ziaee SA, Halimiasl P, Aminsharifi A, et al. Management of 10–15-mm proximal ureteral stones: ureteroscopy or extracorporeal shockwave lithotripsy? *Urology* 2008; 71(1): 28–31.
24. Kurahashi T, Miyake H, Oka N, et al. Clinical outcome of ureteroscopic lithotripsy for 2,129 patients with ureteral stones. *Urol Res* 2007; 35(3): 149–153.
25. Yencilek F, Sarica K, Erturam S, et al. Treatment of ureteral calculi with semirigid ureteroscopy: where should we stop? *Urol Int* 2010; 84: 260–264.
26. Denstedt J and Clayman RV. Electrohydraulic lithotripsy of renal and ureteral calculi. *J Urol* 1990; 143: 13–17.
27. Graff J, Pastor J, Funke PJ, et al. Extracorporeal shock wave lithotripsy for ureteral stones: a retrospective analysis of 417 cases. *J Urol* 1988; 139: 513–516.
28. Scarpa RM, DeLisa A, Porru D, et al. Holmium:YAG laser ureterolithotripsy. *Eur Urol* 1999; 35: 233–238.
29. Cheung MC, Lee F, Yip SK, et al. Outpatient holmium laser lithotripsy using semirigid ureteroscope. Is the treatment outcome affected by stone load? *Eur Urol* 2001; 39: 702–708.
30. Devarajan R, Ashraf M, Beck RO, et al. Holmium:YAG laser lithotripsy for ureteric calculi: an experience of 300 procedures. *Br J Urol* 1998; 82(3): 342–347.