

Disrupted white matter integrity is associated with cognitive deficits in patients with amnesic mild cognitive impairment: An atlas-based study

SAGE Open Medicine

Volume 4: 1–8

© The Author(s) 2016

Reprints and permissions:

sagepub.co.uk/journalsPermissions.nav

DOI: 10.1177/2050312116648812

smo.sagepub.com

Duan Liu, Zan Wang, Hao Shu and Zhijun Zhang

Abstract

Objective: This study investigated white matter integrity in patients with amnesic mild cognitive impairment by diffusion tensor imaging.

Methods: A total of 83 patients with amnesic mild cognitive impairment and 85 elderly healthy controls underwent neuropsychological testing and a diffusion tensor imaging scan. Whole-brain white matter data were parcellated into 50 regions based on the anatomical ICBM-DTI-81 atlas, and regional diffusion metrics consisting of fractional anisotropy, mean diffusivity, radial diffusivity, and axial diffusivity were calculated for each region. Diffusion tensor imaging indices were compared between groups, and it was determined that between-group differences were significantly correlated with neurocognitive performance.

Results: Relative to the healthy controls group, the amnesic mild cognitive impairment group exhibited poorer cognitive performance in all neuropsychological tests except the complex figure test ($p = 0.083$) and showed decreased mean fractional anisotropy in the fornix, increased mean diffusivity in the fornix and bilateral uncinate fasciculus, elevated axial diffusivity in the fornix and genu of corpus callosum, and elevated radial diffusivity in the fornix and bilateral uncinate fasciculus ($p < 0.05$). Behaviorally, integrity of the bilateral uncinate fasciculus was correlated positively with episodic memory function, while left uncinate fasciculus integrity was positively associated with language function in the amnesic mild cognitive impairment group ($p < 0.05$).

Conclusion: White matter abnormalities in neural pathways associated with memory were correlated with neurocognitive deficiencies in amnesic mild cognitive impairment. Given that amnesic mild cognitive impairment is putatively a prodromal syndrome for Alzheimer's disease, this study furthers our understanding of the white matter changes associated with Alzheimer's disease pathogenesis in the predementia stage.

Keywords

Amnesic mild cognitive impairment, diffusion tensor imaging, atlas-based analysis, cognitive function

Date received: 18 November 2015; accepted: 31 March 2016

Introduction

Mild cognitive impairment (MCI) is a transition stage between normal aging and dementia. Clinically, MCI comprises two subtypes, amnesic MCI (aMCI) and nonamnesic MCI (naMCI), which are differentiated according to whether memory impairment is present.¹ Recently, aMCI has been recognized as an essential clinical element for diagnosing prodromal Alzheimer's disease (AD).² Therefore, aMCI may correspond to a critical time window for early diagnosis and effective prevention of dementia.

Imaging-based characterizations of aMCI will enable better diagnostic capabilities and the ability to track dementia

progression while also improving the understanding of aMCI pathology. Previous structural magnetic resonance imaging (MRI) studies have described hippocampal atrophy and

Department of Neurology, The Second People's Hospital Of Chengdu, Chengdu, China

Corresponding author:

Zhijun Zhang, Department of Neurology, Affiliated ZhongDa Hospital, Neuropsychiatric Institute and Medical School of Southeast University, 87 Dingjiaqiao Road, Nanjing, Jiangsu 210009, China.

Email: janemengzhang@vip.163.com



Creative Commons Non Commercial CC-BY-NC: This article is distributed under the terms of the Creative Commons Attribution-NonCommercial 3.0 License (<http://www.creativecommons.org/licenses/by-nc/3.0/>) which permits non-commercial use, reproduction and distribution of the work without further permission provided the original work is attributed as specified on the SAGE and Open Access pages (<https://us.sagepub.com/en-us/nam/open-access-at-sage>).

cortical thinning in patients with aMCI.³ More recently, growing pathological evidence suggests that there is widespread white matter (WM) damage in aMCI that is believed to be related to axonal damage and breakdown of oligodendrocytes and myelin.^{4,5} Moreover, animal studies indicate that AD-related myelination and neural transmission deficits may occur in the presymptomatic stages of neurodegenerative processes.⁶ Thus, it is possible that patients with aMCI may possess WM disruptions that can be clearly identified by MRI.

Based on the theory that water molecules diffuse more rapidly along neuronal fiber versus the direction perpendicular to fibers,^{7,8} diffusion tensor imaging (DTI) provides a tool for noninvasively investigating the integrity of WM fiber tracts at the microstructural level, through the analysis of four main indices: fractional anisotropy (FA), mean diffusivity (MD), axial diffusivity (DA), and radial diffusivity (DR). FA values are calculated from the diffusion tensor eigenvalues, which may be influenced by a variety of factors including myelination, axon density, axon diameter, axonal membrane integrity, and intravoxel coherence of fiber orientation.^{9,10} MD denotes the average diffusivity in all three dimensions.^{11,12} DA refers to the extent of diffusion along the direction of the highest eigenvalue (λ_1), and DR is calculated as the average diffusion ability along the other two radii (λ_2 and λ_3), which are orthogonal to λ_1 .¹³

All four of these indices are altered by WM damage. It has been demonstrated that injured WM generally accompanies increased MD and decreased FA. Aberrant DR values are also associated with myelin breakdown. Studies of human subjects indicate that WM disruption leads to an initial DA decrease that is followed by a DA increase once axonal fragments are cleared by microglia and water molecules begin to again diffuse longitudinally.^{14,15} Studies suggest that the MD and DR indices are more sensitive in detecting WM lesion-induced alterations than the FA and DA indices.^{16,17}

Recent DTI imaging studies of individuals with aMCI indicate that WM damage is mainly located in the parahippocampal WM, cingulum, uncinate fasciculus, and corpus callosum.^{18–20} However, the results of these studies are inconsistent. For example, the results of analyses of DA in the cingulum have been notably different between studies. This may be due to differences in either patient characteristics (e.g. individuals at different transitional stages between MCI and AD) or image data analysis methodology.^{20,21} Additionally, few studies have taken advantage of newly developed atlas-based analysis (ABA) methods to investigate altered WM integrity in aMCI.²² In this study, we, therefore, used ABA to compare WM integrity in patients with aMCI and healthy elderly controls (HCs) in a relatively large cohort.²³ To investigate the cognitive significance of aberrant WM integrity in aMCI, we then performed partial correlation analysis to elucidate the association of cognitive performance with the WM indices.

Methods

Subjects

We recruited 168 elderly subjects comprising 83 individuals with aMCI and 85 HCs through local community health screening and media advertisements. All participants gave informed consent to participate in the study. The study was approved by the Research Ethics Committee of Affiliated ZhongDa Hospital, Southeast University, and conformed to the ethical principles of the Helsinki Declaration.

Cognitive testing

All subjects underwent diagnostic evaluations, including a clinical interview, demographic inventory, neurological and mental status examination, and medical history review. We assessed general cognitive function by the mini-mental state examination (MMSE) and Mattis Dementia Rating Scale-2 (MDRS-2). To evaluate episodic memory, language, attention, executive function, and visuospatial skills, we carried out a neuropsychological battery that consisted of auditory verbal learning test–delayed recall (AVLT-DR); logical memory test–delayed recall (LMT-DR); the Rey–Osterrieth complex figure test (CFT) and delayed recall to the items in this test; digital symbol substitution test (DSST); clock drawing test (CDT); Stroop color-word tests A, B, and C; trail making test A (TMT-A) and trail making test B (TMT-B); verbal fluency test (VFT); Boston naming test; digital span test (DST); and semantic similarity test.

Inclusion criteria

All participants met the following criteria: aged 55–80 years, education duration of 8 or more years, right-handedness, and no major vision and hearing dysfunction observed on clinical assessment. None of the participants had neuropsychiatric, endocrine, or other diseases that might affect cognitive function.

All patients with aMCI included in the study met the following established diagnostic criteria: (1) complaints of subjective memory by the subject and an informant, (2) diminished objective memory performance documented by an AVLT-DR score inferior to 1.5 standard deviations (SDs) from the age- and education-adjusted norms, (3) an MMSE score that was no less than 24 or an MDRS score that was at least 120, (4) preserved activities of daily living, and (5) absence of dementia that was sufficient to meet the National Institute of Neurological and Communicative Disorders and Stroke (NINCDS) and the Alzheimer's Disease and Related Disorders Association (ADRDA) Alzheimer's criteria. In addition, control subjects were required to have an MMSE score ≥ 26 , an MDRS score ≥ 120 , and an AVLT-DR score > 4 .

MRI data acquisition

All subjects were scanned using a Siemens Verio 3.0-T scanner (Siemens, Erlangen, Germany) with a 12-channel head

coil at ZhongDa Hospital Affiliated with Southeast University. Conventional axial T2-weight images were obtained previously to rule out cerebral infarction or other lesions. Diffusion weighted imaging was acquired with a single-shot echo planar imaging sequence in alignment with the anterior–posterior commissural plan. The diffusion sensitizing gradients were applied along a 30 noncollinear direction ($b=1000\text{ s/mm}^2$), together with an acquisition without diffusion weighting ($b=0\text{ s/mm}^2$). A total of 70 contiguous axial slices were acquired with a slice thickness of 2 mm and no gap. The acquisition parameters were presented as follows: repetition time=10,000 ms, echo time=90 ms, flip angle=90°, acquisition matrix=128 × 128, field of view=256 mm × 256 mm, and number of excitations=2.0.

DTI data post-processing

Individual maps of FA, MD, DA, and DR indices were first obtained with the original DTI data. Second, individual FA images in native space were normalized to Montreal Neurological Institute (MNI) space with an FA template by nonlinear registration. The resultant warping transformations were then used to resample the images of the diffusion metrics (i.e. FA, MD, DA, and DR) with a final voxel size of $1 \times 1 \times 1\text{ mm}^3$. Finally, a WM atlas (ICBM-DTI-81 WM labels atlas divided into 50 areas) of areas in the same standard space was used for segmenting the whole-brain WM image into multiple regions of interest (ROIs), where each ROI represented a labeled region in the atlas. Then, regional diffusion metrics (i.e. FA, MD, DA, and DR) were, respectively, calculated by averaging the values within each region of the WM atlases. The above steps were conducted with a MATLAB toolbox: Pipeline for Analyzing brain Diffusion images.²⁴

Statistical analysis

For demographic data and neuropsychological performance, group comparisons were performed by analysis of covariance (ANCOVA) for age and years of education as covariates and a chi-square test for gender as a covariate. Then, between-group (patients vs controls) differences in mean FA, MD, DA, or DR values for each atlas-based region were examined by multivariate analysis of covariance (MANCOVA) with age, years of education, and gender as covariates. Third, partial correlation coefficients were obtained to examine the relationship between the mean FA, MD, DA, or DR values that showed significant between-group differences and neuropsychological performance, controlling for age, years of education, and gender.

Composite score analysis, which is widely used in data analysis to increase statistical power by reducing random variability and floor and ceiling effects, was conducted. The composite scores for cognitive function were obtained in a two-step process. First, the raw scores from each test for

each subject were transformed to z-scores with reference to the means and SDs of each test for all subjects. Second, the composite scores were calculated by averaging the z-scores of individual tests for the following categories: episodic memory (AVLT-DR, LMT-DR, and CFT-DR), language (VFT and Boston naming test), executive function (Stroop color-word test, TMT-B, and semantic similarity test), attention (DST, TMT-A, and symbol digit modulation test (SDMT)), and visuospatial function (CFT and CDT). MMSE and MDRS were performed for descriptive and diagnostic classifications but not used in the composite measures. All of the above calculations were carried out with Statistical Product and Service Solutions 18.0 (SPSS 18.0) software.

Results

Demographic and neuropsychological data

No significant differences in age, gender distribution, or education years were observed between the aMCI and HC groups (all $p>0.05$, as shown in Table 1). The aMCI group exhibited poorer cognitive performance compared to the HC group in all neuropsychological tests except the CFT (Table 1). Therefore, patients with aMCI in this study showed evidence of significant cognitive decline in processes involving memory, executive function, attention, language, and visuospatial skills.

DTI atlas-based measurements

Using ABA, we observed decreased FA in the fornix and increased MD in the fornix and bilateral uncinate fasciculus in the aMCI group compared with the HC group ($p<0.05$; Table 2). Additionally, both the mean DA in the fornix and genu of corpus callosum and DR in the fornix and bilateral uncinate fasciculus were significantly elevated compared with the HC group ($p<0.05$). In the aMCI group, the DR of the left uncinate fasciculus was significantly increased compared with the right uncinate fasciculus (Figure 1; $p<0.05$).

Behaviorally, episodic memory in subjects with aMCI was negatively correlated with the intragroup mean MD (left: $r=-0.315$, $p=0.004$; right: $r=-0.349$, $p=0.001$) and DR (left: $r=-0.303$, $p=0.006$; right: $r=-0.370$, $p=0.001$) in the bilateral uncinate fasciculus. In addition, within the aMCI group, language function was negatively correlated with mean MD ($r=-0.326$, $p=0.003$) and DR ($r=-0.319$, $p=0.004$) indices in the left uncinate fasciculus (Table 3 and Figure 2).

Discussion

This study compared cerebral WM integrity in aMCI and healthy aging using ABA. Subjects in the aMCI group showed significant cognitive impairment in episodic memory, executive function, attention, language, and the visuospatial domains.

Table 1. Comparisons of demographic characteristics and neuropsychological performances between aMCI and HC groups.

	aMCI (<i>n</i> = 83)	HCs (<i>n</i> = 85)	χ^2/F -value	<i>p</i> -value*
Gender (male/female)	45/38	44/41	0.101	0.750 ^a
Age (years)	69.4 (7.5)	68.4 (6.3)	0.745	0.389
Education (years)	11.9 (3.2)	12.1 (3.0)	0.106	0.746
MMSE	26.2 (2.6)	28.3 (1.3)	43.224	0.000
MDRS	131.4 (6.9)	138.0 (3.5)	62.308	0.000
AVLT-DR	2.4 (1.6)	7.5 (2.0)	324.018	0.000
LMT-DR	4.6 (3.4)	8.4 (2.5)	67.995	0.000
CFT-DR	12.1 (7.3)	18.5 (6.1)	40.674	0.000
Episodic memory ^b	-0.013 (0.835)			
CFT-copy (s)	329.4 (149.9)	284.4 (124.4)	3.048	0.083
CDT	24.9 (4.6)	26.6 (3.0)	8.419	0.004
Visuospatial function ^b	-0.001 (0.495)			
Boston naming test	8.7 (1.4)	9.2 (1.0)	6.821	0.010
VFT (<i>animal</i>)	16.2 (4.6)	21.1 (5.8)	36.683	0.000
Language function ^b	0.002 (0.801)			
DST	11.4 (2.2)	12.3 (2.1)	8.010	0.004
SDMT	30.0 (10.1)	38.6 (9.8)	30.786	0.000
TMT-A (s)	83.9 (36.0)	67.1 (17.6)	14.886	0.000
Attention function ^b	-0.001 (0.480)			
TMT-B (s)	256.8 (124.5)	178.1 (59.0)	27.601	0.000
Stroop A (s)	32.5 (8.7)	26.7 (5.3)	25.834	0.000
Stroop B (s)	47.4 (13.2)	40.4 (10.6)	13.124	0.000
Stroop C (s)	98.2 (29.3)	81.8 (23.8)	15.776	0.000
Semantic similarity test	16.9 (3.8)	18.9 (3.2)	13.289	0.000
Executive function ^b	0.000 (0.487)			

aMCI: amnesic mild cognitive impairment; HC: healthy control; MMSE: mini-mental state examination; MDRS: Mattis Dementia Rating Scale; AVLT-DR: auditory verbal learning test–delayed recall; CFT-DR: complex figure test–delayed recall; LMT-DR: logical memory test–delayed recall; CDT: clock drawing test; VFT: verbal fluency test; DST: digit span test; SDMT: symbol digit modulation test; TMT-A: trail making test A; TMT-B: trail making test B. Values are presented as mean (standard deviation).

^a*p* value was obtained by chi-square test.

^bComposite score of episodic memory, language, attention, executive function, and visuospatial skills is presented as mean (standard deviation).

**F* and *p* values were obtained by analysis of covariance (ANCOVA) with age, years of education, and gender as covariates, exception of gender.

Table 2. Atlas-based analysis for aMCI and HC groups.

	DTI value	aMCI (<i>n</i> = 83)	HCs (<i>n</i> = 85)	<i>F</i> -value	<i>p</i> -value
Fornix	FA	0.30 (0.09)	0.33 (0.09)	5.251	0.023
	MD (E-03)	2.11 (0.33)	1.98 (0.33)	5.154	0.025
	DA (E-03)	2.69 (0.25)	2.59 (0.25)	4.970	0.027
	DR (E-03)	1.82 (0.38)	1.68 (0.38)	5.134	0.025
Genu of corpus callosum	FA	0.53 (0.04)	0.53 (0.03)	0.736	0.392
	MD (E-04)	9.08 (0.61)	8.90 (0.54)	3.126	0.079
	DA (E-03)	1.49 (0.05)	1.47 (0.06)	5.359	0.022
	DR (E-04)	6.16 (0.70)	6.00 (0.57)	1.979	0.161
Uncinate fasciculus right	FA	0.42 (0.04)	0.43 (0.03)	1.581	0.210
	MD (E-04)	8.26 (0.67)	8.04 (0.44)	5.542	0.020
	DA (E-03)	1.21 (0.08)	1.19 (0.06)	2.480	0.117
	DR (E-04)	6.32 (0.70)	6.09 (0.46)	5.871	0.016
Uncinate fasciculus left	FA	0.39 (0.04)	0.39 (0.04)	0.830	0.364
	MD (E-04)	8.44 (0.74)	8.22 (0.39)	4.873	0.029
	DA (E-03)	1.21 (0.09)	1.19 (0.06)	3.185	0.076
	DR (E-04)	6.63 (0.74)	6.41 (0.42)	4.776	0.030

aMCI: amnesic mild cognitive impairment; HC: healthy control; FA: fractional anisotropy; MD: mean diffusivity; DA: axial diffusivity; DR: radial diffusivity; DTI: diffusion tensor imaging.

This table only shows the statistically significant areas of the brain (significance level: *p* < 0.05). Values are mean (standard deviation).

Abnormalities were observed in the fornix, genu of corpus callosum, and bilateral uncinate fasciculus. Furthermore, integrity of the bilateral uncinate fasciculus was correlated positively with episodic memory function, while integrity of the left uncinate fasciculus alone was positively associated with language function in the aMCI group.

Our use of the newly developed approach of ABA allowed us to comprehensively study WM tract integrity throughout the brain. Various methods of DTI analysis have been developed to detect WM integrity in addition to ABA, including ROI analysis and voxel-based analysis (VBA), as well as the more recently developed tract-based spatial statistics (TBSS) approach. ROI-based methods can be used to investigate regional WM integrity when there is a specific hypothesis pertaining to the affected regions, but it is limited in its ability to detect both integrity and volume of WM fiber tracts at the whole-brain level. By contrast, VBA allows for DTI data analysis in a voxel-wise manner^{25,26} but has low statistical power partly due to signal interference among individual voxels. In contrast, ABA enables automatic segmentation of whole-brain DTI data into multiple predefined brain regions according to a three-dimensional (3D) anatomical template, thereby avoiding partial volume effects in structure-by-structure analysis. This method is superior to VBA in that it reduces the anatomical dimensions of DTI data. ABA is additionally able to sensitively detect entire tract volumes and minor alterations at the neural systems level.^{27,28} Furthermore, ABA has been demonstrated to have greater sensitivity and specificity for detecting aberrant WM integrity compared with the TBSS method.^{29,30} By applying ABA to whole-brain DTI data, we were, therefore, able to more

precisely and thoroughly assess WM tract integrity in this study than in previous work.

Our findings of decreased FA values and increased MD, DA, and DR values in the fornix of the aMCI group indicate that the integrity and connectivity of fornix is disrupted in individuals with aMCI. The fornix is an essential structure in relaying information from the hippocampal output pathway and the Papez circuit, which play key roles in episodic memory formation and AD pathogenesis.^{20,31,32} Therefore, disrupted WM integrity of the fornix observed in this study may underlie memory dysfunction observed in individuals with aMCI.^{33,34}

Furthermore, we found increased MD and DR in the bilateral uncinate fasciculus in the aMCI group. The uncinate fasciculus is responsible for connecting the hippocampus with the subgenual cortex. In accordance with this result, previous studies have found disrupted uncinate fasciculus integrity in individuals with MCI and AD.^{35,36} We further found that the DR of the left uncinate fasciculus was significantly increased compared with the right uncinate fasciculus in the aMCI group. Previous studies have reported that gray matter (GM) volumetric reductions in patients with aMCI who developed AD were mainly located in the left hippocampus.³⁷ Using a novel ABA approach in this study, we determined that WM abnormalities were more severe in the left side of the hippocampus in individuals with aMCI, which may be the reason that the left hemisphere is more affected in AD.³⁸

Additionally, we found that the genu of corpus callosum, a commissural fiber connecting the frontal lobes bilaterally, was impaired in patients with aMCI, corroborating the work of Wang et al.³⁹ Furthermore, the regions in which the MD and DR values increased were greater than the values of FA and DA in WM. These results support the view that the MD and DR values have greater sensitivity than the FA and DA values in detecting WM lesions.

Importantly, correlations between DTI findings and cognitive performance were identified in patients with aMCI. It has been demonstrated that reduced integrity in the uncinate fasciculus is associated with diminished memory and language function. Distinguishing our study from previous DTI studies,^{15,40} we carried out correlation analysis between cognitive function and altered WM integrity using composite scores of cognitive function. We found that the presence of WM degradation is associated with cognitive impairment in aMCI.

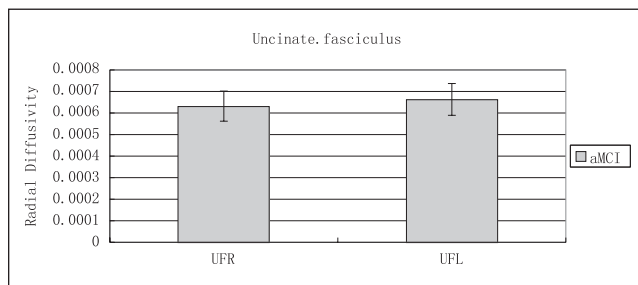


Figure 1. Significant differences in radial diffusivity ($p=0.007$) in individuals with right uncinate fasciculus (UFR) versus left uncinate fasciculus (UFL) in aMCI.

Table 3. Correlations between DTI indices and neurocognitive performance in aMCI patients.

		Memory	Language	Visuospatial	Attention	Executive function
Uncinate fasciculus right	MD	$r=-0.349, p=0.001$		—	—	—
	DR	$r=-0.370, p=0.001$		—	—	—
Uncinate fasciculus left	MD	$r=-0.315, p=0.004$	$r=-0.326, p=0.003$	—	—	—
	DR	$r=-0.303, p=0.006$	$r=-0.319, p=0.004$	—	—	—

aMCI: amnesic mild cognitive impairment; MD: mean diffusivity; DR: radial diffusivity; DTI: diffusion tensor imaging.

This table only shows the significant correlations by partial correlation using SPSS (significance level: $p < 0.05$, Bonferroni corrected).

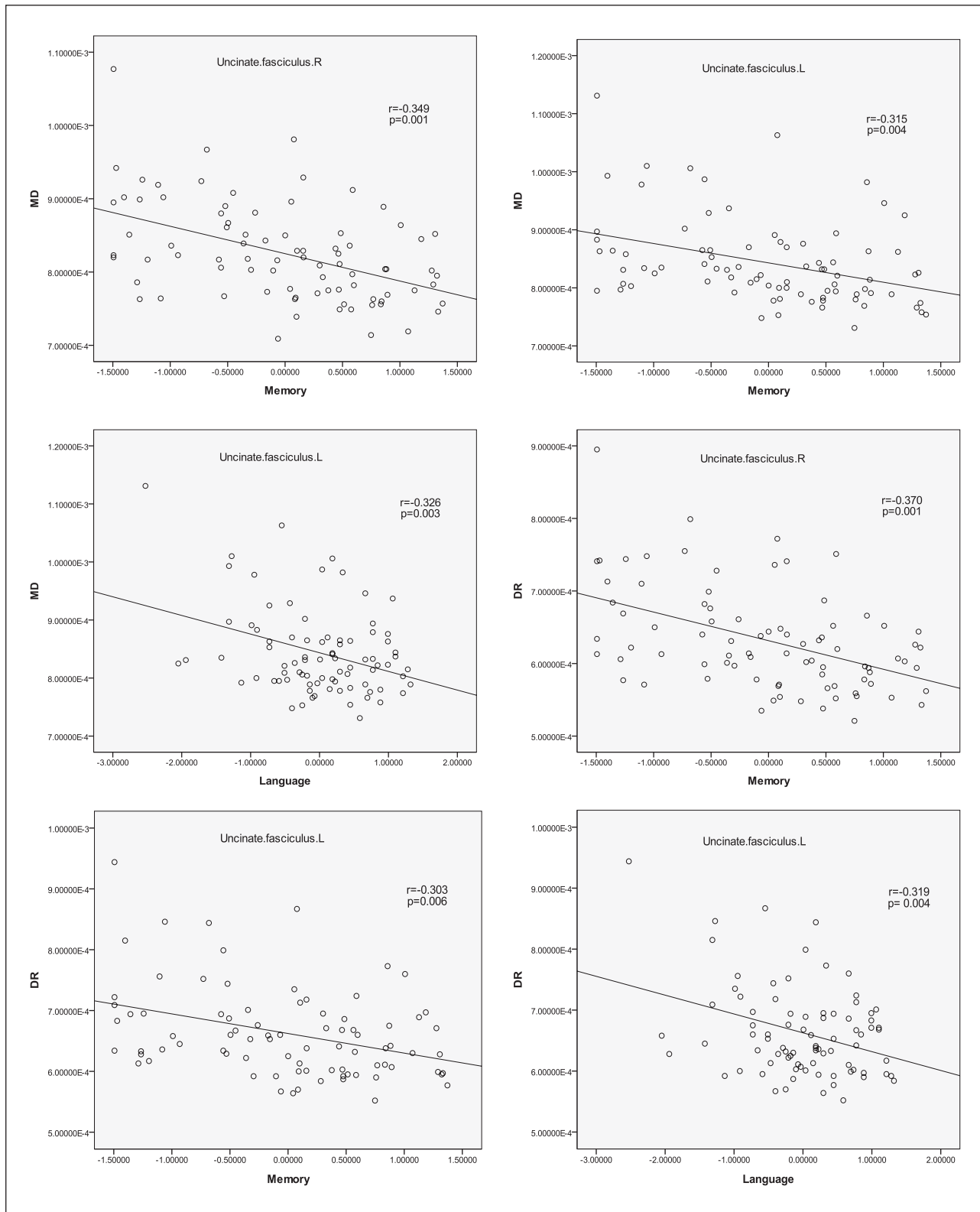


Figure 2. Statistically significant correlations (after controlled age, years of education and gender, Bonferroni corrected) between MD or DR and cognitive function in bilateral uncinate fasciculus.

This study has several limitations that should be noted. First, the cross-sectional design did not allow us to

determine the potential role of abnormal WM integrity in the transition to AD in patients with aMCI. Second, the ABA

findings did not reach statistical significance when a multiple comparison correction was applied. Thus, the significant findings for fasciculus impairment should be validated in an independent sample. Indeed, we will carry out a follow-up study in subjects with aMCI in order to validate and extend the findings presented here.

Conclusion

Using a novel ABA approach, we found evidence of disrupted cerebral WM integrity in hippocampal-associated pathways in patients with aMCI that were closely correlated with cognitive impairment. These data expand our knowledge of the pathological changes in WM that contribute to neurodegenerative processes in AD. Further studies with a large independent sample and longitudinal design are required to validate the role of DTI indices in tracking AD development and progression.

Acknowledgements

We sincerely thank Youming Zheng, Haixia Feng, Hong Zhu, and Xiaofa Huang for subject recruitment.

Declaration of conflicting interests

The author(s) declared no potential conflicts of interest with respect to the research, authorship, and/or publication of this article.

Ethics approval

The study conformed to the ethical principles of the Helsinki declaration and was approved by the Research Ethics Committee of Affiliated ZhongDa Hospital, Southeast University (approval no: 2008ZDLL010.1).

Funding

The author(s) received no financial support for the research, authorship, and/or publication of this article.

Informed consent

Written informed consent was obtained from all subjects before the study.

References

- Petersen RC. Mild cognitive impairment as a diagnostic entity. *J Intern Med* 2004; 256: 183–194.
- Dubois B, Feldman HH, Jacova C, et al. Revising the definition of Alzheimer's disease: a new lexicon. *Lancet Neurol* 2010; 9: 1118–1127.
- Devanand DP, Pradhaban G, Liu X, et al. Hippocampal and entorhinal atrophy in mild cognitive impairment: prediction of Alzheimer disease. *Neurology* 2007; 68: 828–836.
- Markesbery WR. Neuropathologic alterations in mild cognitive impairment: a review. *J Alzheimers Dis* 2010; 19: 221–228.
- Englund E. Neuropathology of WM changes in Alzheimer's disease and vascular dementia. *Dement Geriatr Cogn Disord* 1998; 9(Suppl. 1): 6–12.
- Desai MK, Sudol KL, Janelins MC, et al. Triple-transgenic Alzheimer's disease mice exhibit region-specific abnormalities in brain myelination patterns prior to appearance of amyloid and tau pathology. *Glia* 2009; 57: 54–65.
- Le Bihan D, Mangin JF, Poupon C, et al. Diffusion tensor imaging: concepts and applications. *J Magn Reson Imaging* 2001; 13: 534–546.
- Sundgren PC, Dong Q, Gómez-Hassan D, et al. Diffusion tensor imaging of the brain: review of clinical applications. *Neuroradiology* 2004; 46: 339–350.
- Beaulieu C, Does MD, Snyder RE, et al. Changes in water diffusion due to Wallerian degeneration in peripheral nerve. *Magn Reson Med* 1996; 36: 627–631.
- Smith SM, Johansen-Berg H, Jenkinson M, et al. Acquisition and voxelwise analysis of multi-subject diffusion data with tract-based spatial statistics. *Nat Protoc* 2007; 2: 499–503.
- Bozzali M, Falini A, Franceschi M, et al. White matter damage in Alzheimer's disease assessed in vivo using diffusion tensor magnetic resonance imaging. *J Neurol Neurosurg Psychiatry* 2002; 72: 742–746.
- Kantarci K, Jack CR Jr, Xu YC, et al. Mild cognitive impairment and Alzheimer disease: regional diffusivity of water. *Radiology* 2001; 219: 101–107.
- Zhang Y, Du AT, Hayasaka S, et al. Patterns of age-related water diffusion changes in human brain by concordance and discordance analysis. *Neurobiol Aging* 2010; 31: 1991–2001.
- Thomalla G, Glauche V, Weiller C, et al. Time course of wallerian degeneration after ischaemic stroke revealed by diffusion tensor imaging. *J Neurol Neurosurg Psychiatry* 2005; 76: 266–268.
- Thomas B, Eyssen M, Peeters R, et al. Quantitative diffusion tensor imaging in cerebral palsy due to periventricular white matter injury. *Brain* 2005; 128: 2562–2577.
- Davis SW, Dennis NA, Buchler NG, et al. Assessing the effects of age on long white matter tracts using diffusion tensor tractography. *Neuroimage* 2009; 46: 530–541.
- Acosta-Cabronero J, Williams GB, Pengas G, et al. Absolute diffusivities define the landscape of white matter degeneration in Alzheimer's disease. *Brain* 2010; 133: 529–539.
- Zhang Y, Schuff N, Jahng GH, et al. Diffusion tensor imaging of cingulum fibers in mild cognitive impairment and Alzheimer disease. *Neurology* 2007; 68: 13–19.
- Bai F, Zhang Z, Watson DR, et al. Abnormal integrity of association fiber tracts in amnesic mild cognitive impairment. *J Neurol Sci* 2009; 278: 102–106.
- Liu Y, Spulber G, Lehtimäki KK, et al. Diffusion tensor imaging and tract-based spatial statistics in Alzheimer's disease and mild cognitive impairment. *Neurobiol Aging* 2011; 32: 1558–1571.
- Claire ES, Ukwuori GK, Nicola F, et al. A meta-analysis of diffusion tensor imaging in mild cognitive impairment and Alzheimer's disease. *Neurobiol Aging* 2011; 32: 12.
- Oishi K, Faria A, Jiang H, et al. Atlas-based whole brain white matter analysis using large deformation diffeomorphic metric mapping: application to normal elderly and Alzheimer's disease participants. *Neuroimage* 2009; 46(2): 486–499.
- Ito K, Sasaki M, Takahashi J, et al. Detection of early changes in the parahippocampal and posterior cingulum bundles during mild cognitive impairment by using high-resolution multi-parametric diffusion tensor imaging. *Psychiatry Res* 2015; 231: 346–352.

24. Cui Z, Zhong S, Xu P, et al. PANDA: a pipeline toolbox for analyzing brain diffusion images. *Front Hum Neurosci* 2013; 7: 42.
25. Soria-Pastor S, Padilla N, Zubiaurre-Elorza L, et al. Decreased regional brain volume and cognitive impairment in preterm children at low risk. *Pediatrics* 2009; 24: 1161–1170.
26. Oishi K, Mielke MM, Albert M, et al. DTI analyses and clinical applications in Alzheimer's disease. *J Alzheimers Dis* 2011; 26: 287–296.
27. Faria AV, Joel SE, Zhang Y, et al. Atlas-based analysis of resting-state functional connectivity: evaluation for reproducibility and multi-modal anatomy-function correlation studies. *Neuroimage* 2012; 61: 613–621.
28. Giménez M, Miranda MJ, Born AP, et al. Accelerated cerebral white matter development in preterm infants: a voxel-based morphometry study with diffusion tensor MR imaging. *Neuroimage* 2008; 41: 728–734.
29. Preti MG, Baglio F, Laganà MM, et al. Assessing corpus callosum changes in Alzheimer's disease: comparison between tract-based spatial statistics and atlas-based tractography. *PLoS One* 2012; 7: e35856.
30. Jenkinson M, Beckmann CF, Behrens TE, et al. FSL. *Neuroimage* 2012; 62: 782–790.
31. Nestor PJ, Fryer TD, Smielewski P, et al. Limbic hypometabolism in Alzheimer's disease and mild cognitive impairment. *Ann Neurol* 2003; 54: 343–351.
32. Zhuang L, Wen W, Zhu W, et al. White matter integrity in mild cognitive impairment: a tract-based spatial statistics study. *Neuroimage* 2010; 53: 16–25.
33. Takei K, Yamasue H, Abe O, et al. Disrupted integrity of the fornix is associated with impaired memory organization in schizophrenia. *Schizophr Res* 2008; 103: 52–61.
34. Nestor PG, Kubicki M, Kuroki N, et al. Episodic memory and neuroimaging of hippocampus and fornix in chronic schizophrenia. *Psychiatry Res* 2007; 155: 21–28.
35. Yasmin H, Nakata Y, Aoki S, et al. Diffusion abnormalities of the uncinate fasciculus in Alzheimer's disease: diffusion tensor tract-specific analysis using a new method to measure the core of the tract. *Neuroradiology* 2008; 50: 293–299.
36. Fouquet M, Desgranges B, Landeau B, et al. Longitudinal brain metabolic changes from amnesic mild cognitive impairment to Alzheimer's disease. *Brain* 2009; 132: 2058–2067.
37. Ferreira LK, Diniz BS, Forlenza OV, et al. Neurostructural predictors of Alzheimer's disease: a meta-analysis of VBM studies. *Neurobiol Aging* 2011; 32: 1733–1741.
38. Scahill RI, Schott JM, Stevens JM, et al. Mapping the evolution of regional atrophy in Alzheimer's disease: unbiased analysis of fluid-registered serial MRI. *Proc Natl Acad Sci* 2002; 99: 4703–4707.
39. Wang L, Goldstein FC, Veledar E, et al. Alterations in cortical thickness and white matter integrity in mild cognitive impairment measured by whole brain cortical thickness mapping and diffusion tensor imaging. *AJNR Am J Neuroradiol* 2009; 30: 893–899.
40. Bosch B, Arenaza-Urquijo EM, Rami L, et al. Multiple DTI index analysis in normal aging, amnesic MCI and AD. Relationship with neuropsychological performance. *Neurobiol Aging* 2012; 33: 61–74.