

Past and present in abdominal surgery management for Cushing's syndrome

SAGE Open Medicine
2: 2050312114528905
© The Author(s) 2014
Reprints and permissions:
sagepub.co.uk/journalsPermissions.nav
DOI: 10.1177/2050312114528905
smo.sagepub.com


Ramon Vilallonga¹, Carles Zafon^{2,3}, José Manuel Fort¹, Jordi Mesa^{2,3}
and Manel Armengol¹

Abstract

Introduction: Data on specific abdominal surgery and Cushing's syndrome are infrequent and are usually included in the adrenalectomy reports. Current literature suggests the feasibility and reproducibility of the surgical adrenalectomies for patients diagnosed with non-functioning tumours and functioning adrenal tumours including pheochromocytoma, Conn's syndrome and Cushing's syndrome.

Discussion: Medical treatment for Cushing's syndrome is feasible but follow-up or clinical situations force the patient to undergo a surgical procedure. Laparoscopic surgery has become a gold standard nowadays in a broad spectrum of pathologies. Laparoscopic adrenalectomies are also standard procedures nowadays. However, despite the different characteristics and clinical disorders related to the laparoscopically removed adrenal tumours, the intraoperative and postoperative outcomes do not significantly differ in most cases between the different groups of patients, techniques and types of tumours. Tumour size, hormonal type and surgeon's experience could be different factors that predict intraoperative and postoperative complications. Transabdominal and retroperitoneal approaches can be considered. Outcomes for Cushing's syndrome do not differ depending on the surgical approach. Novel technologies and approaches such as single-port surgery or robotic surgery have proven to be safe and feasible.

Conclusion: Laparoscopic adrenalectomy is a safe and feasible approach to adrenal pathology, providing the patients with all the benefits of minimally invasive surgery. Single-port access and robotic surgery can be performed but more data are required to identify their correct role between the different surgical approaches. Factors such as surgeon's experience, tumour size and optimal technique can affect the outcomes of this surgery.

Keywords

Adrenal surgery, Cushing's syndrome, evolution

Date received: 8 October 2013; accepted: 24 February 2014

Introduction

Cushing's syndrome (CS) results from chronic levels of the hormone cortisol in the body either from endogenous or exogenous sources. Endogenous CS is a rare entity, with estimated incidence of 2.4 cases per million populations per year.¹ Traditionally, most of these cases are due to a pituitary adenoma (Cushing disease), which is thought to occur in 80%–85% of cases. Small percentage of cases include adrenocorticotrophic hormone (ACTH)-dependent CS (<10%) resulting from (non-pituitary) ectopic ACTH secretion (EAS) or, more rarely, corticotropin-releasing hormone by benign or malignant neoplasias such as a neuroendocrine tumour. The remaining percentage of patients (15%–20%) has ACTH-independent CS, which is the result of either bilateral adrenocortical hyperplasia or adrenocortical tumours that secrete excessive cortisol, causing suppression of ACTH.²

The clinical manifestations are multiple. The typical complaints of the patients are weight gain, especially in the face

¹Endocrine, Metabolic and Bariatric Unit, General Surgery Department, University Hospital Vall d'Hebron, Center of Excellence for the EAC-BC, Barcelona, Spain

²Department of Endocrinology, University Hospital Vall d'Hebron, Universitat Autònoma de Barcelona, Barcelona, Spain.

³Diabetes and Metabolism Research Unit (VHIR), Centro de Investigación Biomédica en Red de Diabetes y Enfermedades Metabólicas Asociadas (CIBERDEM), ISCIII, Barcelona, Spain

Corresponding author:

Ramon Vilallonga, Endocrine, Metabolic and Bariatric Unit, General Surgery Department, University Hospital Vall d'Hebron, Center of Excellence for the EAC-BC, Passeig de la Vall d'Hebron, 119-129, 08035 Barcelona, Spain.
Email: vilallongapuy@hotmail.com

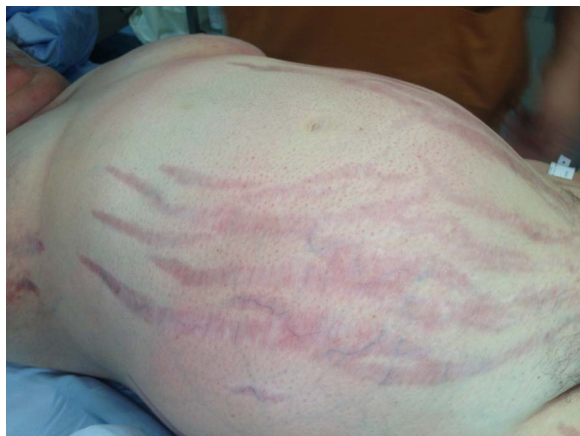

Figure 1. Patient who underwent laparoscopic adrenalectomy presenting weight gain, supraclavicular fat pads, buffalo hump and central obesity. We can observe the classical purple striae with acne.

developing the classic ‘moon face’, supraclavicular fat pads, buffalo hump and central obesity. Other frequent signs are purple striae, acne, skin thinning, easy bruising, osteopenia, proximal muscle weakness, emotional lability, menstrual dysfunction, virilization in women and infertility² (Figure 1). CS shortens the expectancy of life of the patients due to cardiovascular disease, diabetes as well as hypertension (caused by cortisol, excess of sodium and water retention).^{1,2}

As for the diagnosis, a detailed clinical history, physical examination, laboratory tests and radiologic evaluation can confirm the existence of a CS as well as determine its cause.

Medical treatment is based on the administration of adrenal enzyme inhibitors, such as ketoconazole, metyrapone, mitotane or aminogluthetimide.³ However, the blockage achieved is only transient and leads to significant potential liver toxicity. Many of these patients, however, will benefit from a surgical procedure. When considering surgery for CS, which results from an ACTH-producing tumour of the pituitary gland (Cushing’s disease), treatment may include medical inhibitors of the ACTH secretion, but also surgical removal of a small, well-defined pituitary adenoma.³ The transsphenoidal adenomectomy surgical approach is the gold standard for the removal of these tumours.⁴ The access to this area through the gums above the upper front teeth or the nose is feasible with minimally invasive surgery.⁵ By using special instruments, the surgeon makes an incision which is extended through the sphenoid sinus. Thus, the endoscopic view facilitates to remove the adenoma. This type of surgery and surgical approach permanently cures CS in 60%–70% of patients.⁶ In those cases where the tumour cannot be identified, hemihypophysectomy may be considered or even subtotal hypophysectomy.⁷ For some other patients, for whom the previous treatments have not been successful, surgical removal of the adrenal glands should be recommended, including total excision of one or both adrenal

glands. Also, patients diagnosed with non-functioning adrenal tumour (NFT) and functioning adrenal tumour (FT) including pheochromocytoma (PH), Conn’s syndrome (CO) and CS might benefit from a surgical approach. For patients with corticotropin (ACTH)-dependent CS who have experienced failed attempts to remove the pituitary or ectopic neoplasm, bilateral adrenalectomy emerges as an excellent treatment option, resulting in immediate cure of hypercortisolism-related symptoms even in those patients with disseminated, untreatable malignancy.^{3,8}

Surgical management and factors related

It is generally accepted that the laparoscopic approach (LA) offers some advantages compared with the open approach (OA) such as shorter postoperative recovery time, less long-term morbidity, earlier return to daily activities, early return of bowel function and low rate of wound infection and hernia.^{2,3,9} Some authors have tried to define which should be the criteria to perform LA versus OA. Factors such as suspicious of malignancy, a large size of the tumour, morbid obesity and invasion of the surrounding structures have been described as some reasons for conversion to open surgery without a doubt.¹⁰

In a survey conducted by the endocrine surgery section of Spanish Association of Surgeons,¹¹ it was found that the LA was generally the procedure chosen by 84% of the surgeons who responded to the survey. According to their results, they had a lower rate for conversion to laparotomy (6.7%), overall morbidity (8.9%), urgent re-operation (2.3%) and mortality (0.3%) as well as a length of hospital stay of 4.9 days. In addition, it was shown that laparoscopic adrenal surgery was usually performed by a small number of surgeons in endocrine surgery units in large hospitals. Various US and European articles have analysed the influence of the volume of activity on the patients’ outcome. The outcome of these procedures does not appear to depend generally on the type of hormonal secretion by the adrenal lesion. Laparoscopy offers the possibility to operate tumours responsible for incidentalomas, CO, CS or even PH.^{12–15}

The surgeon should choose the type of procedure after a thorough preoperative study.¹⁶ Once the approach is chosen, which in most of the cases will be laparoscopically, adrenalectomies can be performed safely.¹¹

LA to the adrenal gland

There are many ways to approach the adrenal gland laparoscopically, such as by a lateral transperitoneal approach, anterior transperitoneal approach, lateral retroperitoneal approach and posterior transperitoneal approach. A clear evolution has been observed during the past 20 years in the endocrinologic surgical field, especially when dealing with new approaches and technologies.

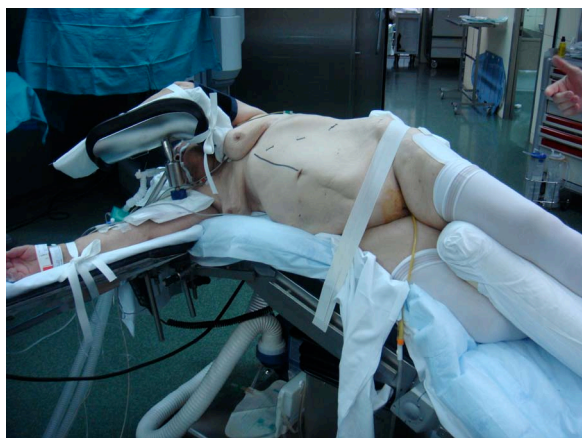

Figure 2. Patient's positioning before performing a left robotic transabdominal laparoscopic adrenalectomy in a patient with CS. CS: Cushing's syndrome.

The standard LA was first reported in 1992 by Gagner et al.,¹⁷ and nowadays, it is defined as the standard of care for adrenal pathology.³ Even when there is suspicious of malignancy or adrenal masses >7 cm, LA is considered a safe option.⁹ When compared to medical therapy, laparoscopic adrenalectomy is superior in terms of tolerance, efficacy and safety.³ The choice of approach in laparoscopic adrenalectomy is dependent upon surgeon because there have not been found any superiority in either the transperitoneal or the retroperitoneal approach. Some surgeons do prefer the retroperitoneal approach for patients who have had prior abdominal surgery.³ In addition, the benefits of this approach are said to be a shorter operating time, reduced blood loss and reduced risk of injury to the viscera. The retroperitoneal approach uses the retroperitoneal space in order to access the gland. A bilateral adrenalectomy can be performed in this fashion by experienced surgeons with the patient in prone position without having to move the patient.⁹ Nevertheless, the lateral transperitoneal approach is preferred by most of the surgeons because the working space is wider, the anatomic landmarks are clearer and the fact that lateral decubitus and the medial rotation of the viscera allow gravity to keep the viscera away from the surgical field. The transperitoneal route is a more standardised approach where the adrenal gland is reached by entering the abdominal cavity (Figure 2).

The laparoscopic technique pretends to remove the gland by previously identifying, clipping and dividing the adrenal vein (right or left). Each adrenalectomy performed on each side has specific anatomical landmarks that skilled endocrine surgeon has to respect in order to perform a standard adrenalectomy.¹¹

Factors related to laparoscopic outcomes

In a personal review, limiting the search for reviews and systematic reviews with the keywords 'adrenalectomy, surgery

and Cushing syndrome', 154 articles were included in the final study after performing the first search. All abstracts were reviewed and 33 articles were selected according to the information provided with reference to CS. All these studies suggest the feasibility and reproducibility of the adrenalectomies. Many of the articles showed results with patients diagnosed with NFT, FT, PH, CO syndrome and CS. However, despite the different characteristics and clinical disorders related to laparoscopically removed adrenal tumours, the intraoperative and postoperative outcomes did not significantly differ in most cases between the different groups of patients, techniques and types of tumours. Tumour size, hormonal type and surgeon's experience could be different factors that predict intraoperative and postoperative complications. CS does not differ in terms of surgical approach compared to other types of adrenal tumours. LA for CS is highly successful for pituitary-dependent CS and most ACTH-independent adrenal causes.

Size could be an issue in non-functional tumours, where a size of an adrenal tumour (>8 cm) and/or the evidence of its local invasiveness (both primary and metastatic adrenal malignancy) are still considered in many centres to be contraindications to a LA.^{12,13,15–19}

Many authors have suggested that outcomes after laparoscopic procedure are related to endocrine tumour secretion, size of the tumour and the patient's age.^{15,20} We believe that in the case of larger tumours, the transabdominal approach should be used in order to have an early closure of the adrenal vein avoiding, for example, the life-threatening output of catecholamine.^{20,21} The commonest complication reported is the tissue bleeding.²² This complication can usually be controlled surgically during LA, but conversion to open surgery can be necessary because the ongoing tissue bleeding could not allow a safe tumour dissection. Severe bleedings can occur when dealing with the inferior cava vein during removal of a right adrenal lesion. The lesion of the peritoneum can be a problem when undergoing extraperitoneal LA. An anterior approach can then be required. Surgeon's experience with advanced laparoscopic procedures is related to outcomes, and they are comparable to the outcome of LA performed for all tumours with hormonal disorders.^{21,23–26} Thus, a lower rate of postoperative complications and hospital stay after adrenalectomy is found when it is performed by a surgeon and in a hospital with a high volume of surgical activity.¹¹ Laparoscopic adrenalectomy is currently used to treat patients for whom malignancy is not suspected, while open surgery is still considered the standard treatment approach in patients with suspect of malignancy.²⁷

Conversion from LA to OA ranges between 0% and 13%.¹⁴ Bleeding is the main cause for conversion and other causes include the following: difficult dissection or detection of the adrenal tumour, opening of the peritoneum when performing extraperitoneal approach and the presence of a pneumothorax. Gumbs and Gagner did not found differences related to the hormonal type of tumour,¹⁴ although

the surgeon's experience, the size of the tumour and the body mass index could be predictive for conversion to OA.^{21,24–27} The keys to successful laparoscopic adrenalectomy should be an appropriate patient selection, a clear knowledge of the anatomy, delicate tissue handling, meticulous haemostasis and experience with the technique of laparoscopic adrenalectomy.²⁸ Finally, patients undergoing surgery with CS have a higher predisposition to develop complications related to cicatrization, coagulation and also related to infections.²⁹

New surgical technologies

Clearly, recent advances in imaging, along with developments in neurosurgery with the transsphenoidal approach and also the laparoscopic surgery, have had the greatest impact on today's management of the complex patient with CS. All these advances include the use of new devices and approaches. New surgical approaches such as robotic or single-port access (SPA) surgery have been used in many other procedures such as appendectomy, cholecystectomy or even bariatric procedures.^{29–31} Adrenalectomy has also been one of the indications in which single access can be used.^{32–34} Last but not least, the robotic approach in selected patients with ACTH-dependent CS, such as patients with persistent Cushing's disease after failed hypophysectomy or patients with ectopic ACTH production that may require bilateral adrenalectomy, could be used.³⁵

Robotic adrenal surgery

As mentioned before, a new special tool for adrenal surgery came from a continuous development of new devices, and technologies such as robotic systems (da Vinci®) and single-port robotic incision/access devices have led to better postoperative pain control, better cosmetic result, decreased length of stay and same postoperative results.³⁶ Robotic surgery has proven to assess the surgical anatomy of the adrenal glands, its vascularisation and the surrounding structures, through a high-definition and magnified three-dimensional view of the operating field provided by the da Vinci surgical system (Intuitive Surgical, Sunnyvale, CA, USA) (Figures 2 and 3). This technique performed under the da Vinci Surgical system can be safer and can offer the promise of a unique combination of advantages over open and conventional LAs. However, there is still a lack of clinical data demonstrating improved outcomes for robotic surgical applications within the abdomen and also for adrenalectomy.^{37–39} Thus, more outcome data for surgical robotics should be given in order to elucidate the real benefit compared to the exorbitant costs associated with the use of these tools. The performance of unilateral or synchronous bilateral adrenalectomy treated using the da Vinci robot (Intuitive Surgical) has been described.³⁸ Although, some studies have mentioned that laparoscopic

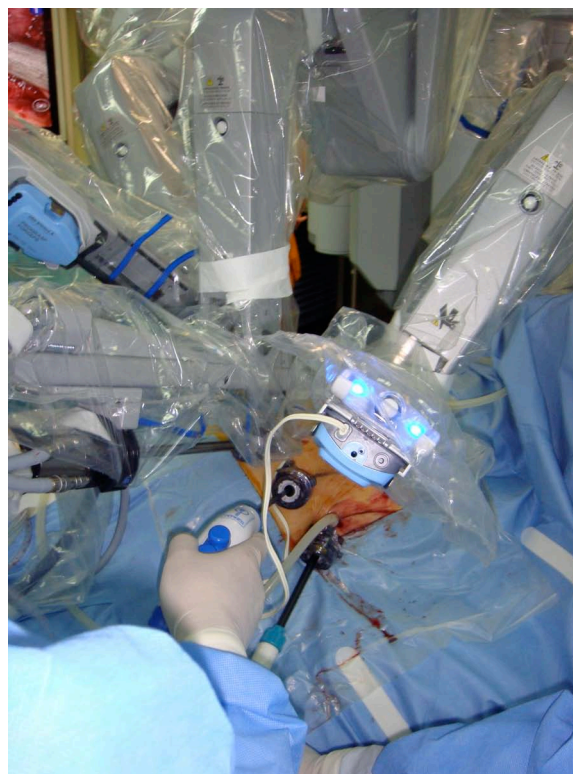


Figure 3. External view of a robotic transabdominal laparoscopic adrenalectomy in a patient with CS. CS: Cushing's syndrome.

adrenalectomy is superior to robot-assisted adrenalectomy in terms of feasibility, morbidity and cost.^{40–42} We can conclude, and according to some of the reviewed papers, that bilateral total adrenalectomy can also provide effective palliation from hypercortisolism in patients with ectopic ACTH syndrome and for those who have failed previous transsphenoidal surgery.⁴³ The da Vinci technology can nowadays be applied through a single incision.⁴⁴

Single-site access adrenal surgery

Recently, advanced laparoscopic skills accumulated from experience and new developments in laparoscopic instruments have led to the introduction of SPA laparoscopic adrenalectomy.⁴³ Many authors have already reported their previous experience in SPA, with good results. This SPA technique could provide potential benefits (lesser wound pain, better cosmetic satisfaction and shorter convalescence).^{45,46} Left adrenalectomy is a technically feasible and safe procedure in carefully selected patients. The definitive clinical, aesthetic and functional advantages of this technique require further analysis. The approach can be challenging for bilateral lesions. Although, further studies will be required in order to define and decide the patients who are more eligible for this approach.³⁶ A summary of the different approaches is shown in Table 1.

Table 1. Table showing the different laparoscopic approaches with their usual accesses, number of trocars, advantages and disadvantages.

	Transperitoneal	Retroperitoneal	Single-port access	Robotic da Vinci® system
Access	Trocars are placed through the anterior abdominal wall	Balloon dilatation of the retroperitoneum below the 12th rib	1 trocar placed umbilical	Anterior or posterior
Number of trocars	Right: 4 (10 mm); left: 3	Right and left: 3 (5 mm)	1 (24 mm) multiport	Same as anterior or posterior with 8 mm da Vinci trocars
Contra-indications	Previous surgical history (above all, kidney or liver procedures) Large gland (from 8 to 10 cm) Carcinoma	BMI > 45 Large gland Need to explore the rest of the abdomen (i.e. metastases)	Previous surgical history (above all, kidney or liver procedures) Large gland (from 8 to 10 cm)	Previous surgical history (above all, kidney or liver procedures) Large gland (from 8 to 10 cm) BMI?
Advantages	Minimally invasive Magnified view Control of the vascular pedicles (obese patients) Absence of large surgical wounds Reduced hospital stay Reduced wound morbidity	Direct access to the gland Avoid the risk of viscera injury No paralytic ileus Bilateral adrenalectomy without repositioning the patient	Less pain Cosmetic result	3D vision Precision Ergonomics
Pitfalls	Liver, splenic and pancreatic injury Tear of an accessory adrenal vein Injury of the vena cava or the diaphragm Division of a polar renal artery Rupture of the capsule of the gland	Colonic injury	Same as transperitoneal, including challenges for surgeon	Same as transabdominal approach

BMI: body mass index (Kg/m²); 3D: three-dimensional.

For all these above-mentioned reasons, during the past decades, surgery has become the treatment of choice for patients with endogenous CS. Adrenalectomy, in particular, is a surgical procedure performed with increasing frequency since 1980s, and over the last two decades, LA has become the surgical procedure of choice in the treatment of most benign adrenal lesions. Also, this approach is suitable for removal of both functional and non-functional tumours. Since then, as we have already mentioned, many authors have reported their experience with their results in OA and LA.

Conclusion

Laparoscopic adrenalectomy is nowadays the technique gold standard for the surgical management of CS because it allows the removal of adrenal lesions or bilateral adrenalectomy in the same act without an increase in morbidity. Moreover, surgery provides an immediate disease control. There are

several studies that have shown its advantages compared with the OA such as reduced hospital stay, less postoperative pain and a decrease in transfusion requirements or wound morbidity. There are wide ranges of technical approaches, which are equally effective. As long as the surgeon has taken into account preoperatively key facts such as the size of the adrenal mass, the history of previous abdominal surgeries. Factors such as tumour size and surgeon's experience may influence the surgical outcomes. New technologies such as robotic surgery or single-port surgery can offer new vistas for the future of adrenal surgery.

Declaration of conflicting interests

The authors declare that they do not have any conflict of interest.

Funding

The Dr Ramon Vilallonga Foundation has financially supported the study and helped to prepare the manuscript (www.fundacioramonvilallonga.org).

References

1. Etxabe J and Vazquez JA. Morbidity and mortality in Cushing's disease: an epidemiological approach. *Clin Endocrinol (Oxf)* 1994; 40: 479–484.
2. Prague JK, May S and Whitelaw BC. Cushing's syndrome. *BMJ* 2013; 346: f945.
3. Fleseriu M and Petersenn S. Medical management of Cushing's disease: what is the future? *Pituitary* 2012; 15: 330–341.
4. Lucas JW and Zada G. Endoscopic surgery for pituitary tumors. *Neurosurg Clin N Am* 2012; 23(4): 555–569.
5. Jane JA Jr, Han J, Prevedello DM, et al. Perspectives on endoscopic transsphenoidal surgery. *Neurosurg Focus* 2005; 19(6): E2.
6. D'Haens J, Van Rompaey K, Stadnik T, et al. Fully endoscopic transsphenoidal surgery for functioning pituitary adenomas: a retrospective comparison with traditional transsphenoidal microsurgery in the same institution. *Surg Neurol* 2009; 72(4): 336–340.
7. Hofstetter CP, Shin BJ, Mubita L, et al. Endoscopic endonasal transsphenoidal surgery for functional pituitary adenomas. *Neurosurg Focus* 2011; 30(4): E10.
8. Malley D, Boris R, Kaul S, et al. Synchronous bilateral adrenalectomy for adrenocorticotrophic-dependent Cushing's syndrome. *JSLs* 2008; 12: 198–201.
9. Castillo OA, López-Fontana G and Vitagliano G. Laparoscopic synchronous bilateral adrenalectomy. *Arch Esp Urol* 2011; 64: 114–120.
10. Brix D, Allolio B, Fenske W, et al.; Adrenocortical Carcinoma Registry Group. Laparoscopic versus open adrenalectomy for adrenocortical carcinoma: surgical and oncologic outcome in 152 patients. *Eur Urol* 2010; 58: 609–615.
11. Villar del Moral JM, Rodríguez González JM, Moreno Llorente P, et al. Adrenal surgery in Spain: final results of a national survey. *Cir Esp* 2011; 89: 663–669.
12. Brunt ML, Moley JF, Doherty GM, et al. Outcomes analysis in patients undergoing laparoscopic adrenalectomy for hormonally active adrenal tumors. *Surgery* 2001; 130: 629–635.
13. Thompson GB and Young WF. Adrenal incidentaloma. *Curr Opin Oncol* 2003; 15: 84–90.
14. Kalady MF, McKinlay R, Olson JA, et al. Laparoscopic adrenalectomy for pheochromocytoma. A comparison to aldosteronoma and incidentaloma. *Surg Endosc* 2004; 18: 621–625.
15. Ramacciato G, Mercantini P, La Torre M, et al. Is laparoscopic adrenalectomy safe and effective for adrenal masses larger than 7 cm? *Surg Endosc* 2008; 22: 516–521.
16. Karanikola E, Tsigris C, Kontzoglou K, et al. Laparoscopic adrenalectomy: where do we stand now? *Tohoku J Exp Med* 2010; 220: 259–265.
17. Gagner M, Lacroix A and Bolté E. Laparoscopic adrenalectomy in Cushing's syndrome and pheochromocytoma. *N Engl J Med* 1992; 327: 1033.
18. Doh QY. Laparoscopic adrenalectomy for isolated adrenal metastasis: the right thing to do and the right way to do it. *Ann Surg Oncol* 2007; 14: 3288–3289.
19. Soon PS, Yeh MW, Delbridge LW, et al. Laparoscopic surgery is safe for large adrenal lesions. *Eur J Surg Oncol* 2008; 34: 67–70.
20. Kim A, Quiros R, Maxhimer J, et al. Outcome of laparoscopic adrenalectomy for pheochromocytomas vs aldosteronomas. *Arch Surg* 2004; 139: 526–531.
21. Karcher KW, Novitsky YW, Park A, et al. Laparoscopic curative resection of pheochromocytomas. *Ann Surg* 2005; 241: 919–928.
22. Assalia A and Gagner M. Laparoscopic adrenalectomy. *Br J Surg* 2004; 91: 1259–1274.
23. Toniato A, Boschini IM, Opocher G, et al. Is the laparoscopic adrenalectomy for pheochromocytoma the best treatment? *Surgery* 2007; 141: 723–777.
24. Porpiglia F, Destefanis P, Flori C, et al. Does adrenal mass size really affect safety and effectiveness of laparoscopic adrenalectomy? *Urology* 2002; 60: 801–805.
25. Salomon L, Soulie M, Mouly F, et al. Experience with retroperitoneal laparoscopic adrenalectomy in 115 procedures. *J Urol* 2001; 166: 38–41.
26. Meria P, Kempf BF, Hermieu JF, et al. Laparoscopic management of primary hyperaldosteronism: clinical experience with 212 cases. *J Urol* 2003; 169: 32–35.
27. Berruti A, Baudin E, Gelderblom H, et al.; ESMO Guidelines Working Group. Adrenal cancer: ESMO Clinical Practice Guidelines for diagnosis, treatment and follow-up. *Ann Oncol* 2012; 23(Suppl. 7): vii131–vii138.
28. Young WF Jr and Thompson GB. Laparoscopic adrenalectomy for patients who have Cushing's syndrome. *Endocrinol Metab Clin North Am* 2005; 34: 489–499, xi.
29. Pivonello R, De Martino MC, De Leo M, et al. Cushing's syndrome. *Endocrinol Metab Clin North Am* 2008; 37: 135–149.
30. Vilallonga R, Barbaros U, Nada A, et al. Single-port transumbilical laparoscopic appendectomy: a preliminary multicentric comparative study in 87 patients with acute appendicitis. *Minim Invasive Surg* 2012; 2012: 492409.
31. Vilallonga R, Rius J, Fort JM, et al. Single port access sleeve gastrectomy: is it reasonable? *J Minim Access Surg* 2011; 7: 156–157.
32. Brunt M and Moley JF. Adrenal incidentaloma. *World J Surg* 2001; 25: 905–913.
33. Walz MK, Alesina PF, Wenger FA, et al. Posterior retroperitoneoscopic adrenalectomy – results of 560 procedures in 520 patients. *Surgery* 2006; 140: 951–952.
34. Alberda WJ, van Eijck CH, Feelders RA, et al. Endoscopic bilateral adrenalectomy in patients with ectopic Cushing's syndrome. *Surg Endosc* 2012; 26: 1140–1145.
35. Valeri A, Bergamini C, Manca G, et al. Adrenal incidentaloma: the influence of the decision-making algorithm on the short-term outcome of laparoscopy. *J Laparoendosc Adv Surg Tech A* 2005; 15: 451–459.
36. Choi SH, Hwang HK, Kang CM, et al. Transumbilical single port laparoscopic adrenalectomy: a technical report on right and left adrenalectomy using the glove port. *Yonsei Med J* 2012; 53: 442–445.
37. Park JH, Walz MK, Kang SW, et al. Robot-assisted posterior retroperitoneoscopic adrenalectomy: single port access. *J Korean Surg Soc* 2011; 81(Suppl. 1): S21–S24.
38. Krane LS, Shrivastava A, Eun D, et al. A four-step technique of robotic right adrenalectomy: initial experience. *BJU Int* 2008; 101: 1289–1292.

39. D'Annibale A, Fiscon V, Trevisan P, et al. The da Vinci robot in right adrenalectomy: considerations on technique. *Surg Laparosc Endosc Percutan Tech* 2004; 14: 38–41.
40. Morino M, Benincà G, Giraudo G, et al. Robot-assisted vs laparoscopic adrenalectomy: a prospective randomized controlled trial. *Surg Endosc* 2004; 18: 1742–1746.
41. Taskin HE and Berber E. Robotic adrenalectomy. *Cancer J* 2013; 19: 162–166.
42. Brandao LF, Autorino R, Laydner H, et al. Robotic versus laparoscopic adrenalectomy: a systematic review and meta-analysis. *Eur Urol* 2013; pii: S0302-2838(13)01008–01007.
43. You JY, Lee HY, Son GS, et al. Comparison of robotic adrenalectomy with traditional laparoscopic adrenalectomy with a lateral transperitoneal approach: a single-surgeon experience. *Int J Med Robot* 2013; 9: 345–350.
44. Park JH, Kim SY, Lee CR, et al. Robot-assisted posterior retroperitoneoscopic adrenalectomy using single-port access: technical feasibility and preliminary results. *Ann Surg Oncol* 2013; 20: 2741–2745.
45. Miyajima A, Hattori S, Maeda T, et al. Transumbilical approach for laparo-endoscopic single-site adrenalectomy: initial experience and short-term outcome. *Int J Urol* 2012; 19: 331–335.
46. Vidal Ó, Astudillo E, Valentini M, et al. Single-incision transperitoneal laparoscopic left adrenalectomy. *World J Surg* 2012; 36(6): 1395–1399.