

# Anatomy of the posterior and middle ethmoidal arteries via computed tomography

SAGE Open Medicine

Volume 6: 1–7

© The Author(s) 2018

Reprints and permissions:

sagepub.co.uk/journalsPermissions.nav

DOI: 10.1177/2050312118772473

journals.sagepub.com/home/smo



Hiroki Yamamoto<sup>1</sup>, Kazuhiro Nomura<sup>1,2</sup> , Hiroshi Hidaka<sup>2</sup>, Yukio Katori<sup>2</sup> and Naohiro Yoshida<sup>1</sup>

## Abstract

**Objective:** The aim of this study is to investigate the anatomy of the posterior and middle ethmoidal arteries from the viewpoint of an endoscopic sinus surgeon.

**Methods:** Based on 100 computed tomography images, the anatomical position of the posterior ethmoidal artery in relation to the posterior ethmoid cells was classified into five types. The presence of the posterior and middle ethmoidal arteries, their distance from the skull base, and their length exposed in the ethmoid cells were measured. The association of patients' age and sex, presence of the middle ethmoidal artery, and anatomical type of the posterior ethmoidal artery with the posterior ethmoidal artery distance from the ethmoid roof was analyzed.

**Results:** The posterior ethmoidal artery's position, relative to the ethmoid cell walls, was most often near the first wall, anterior to the optic canal (92.5%). The posterior ethmoidal artery's distance from the skull base ranged from 0 to 6.4 mm (mean: 1.2 mm). Older age, longer length of the posterior ethmoidal artery exposed in the ethmoid cells, and absence of the middle ethmoidal artery were positively associated with a longer posterior ethmoidal artery distance from the skull base.

**Conclusion:** Attention should be paid to the posterior and middle ethmoidal arteries.

## Keywords

Endoscopic sinus surgery, epistaxis, sinus anatomy, skull base

Date received: 10 November 2017; accepted: 28 March 2018

## Introduction

The anatomy of the ethmoidal arteries is of concern to surgeons performing endoscopic sinus surgery, as injury to these arteries can cause intraorbital hemorrhage and vision loss.<sup>1,2</sup> Recognizing the course of the ethmoidal arteries via computed tomography (CT) before and during surgery reduces the risks of accidental injuries. Previous studies have mostly focused on the anterior ethmoidal artery (AEA); there are comparatively few studies on the posterior ethmoidal artery (PEA) or middle ethmoidal artery (MEA).<sup>1–8</sup> The exact distances between these ethmoidal arteries and the ethmoid roof have not been reported.

After branching from the ophthalmic artery, the PEA supplies the posterior ethmoid cells, nasal septum, and dura overlying the planum sphenoidale.<sup>9,10</sup> The MEA, which is present in 31.8%–33% of nasal cavities according to a cadaver study,<sup>8,11</sup> exists between the AEA and PEA and supplies the nasal septum and ethmoid cells. The importance of the anatomy of the PEA has grown along with the advancement in surgical procedures. The PEA needs to be identified and coagulated during anterior skull base surgery. Recognizing

the anatomy of the PEA during wide sphenoidotomy is important. The PEA is located nearer to the optic nerve than the AEA, and coagulating or clipping the PEA is difficult. The anatomy around the PEA is complex and variable. Identifying the PEA on CT images and understanding its relation to the ethmoid cell walls before surgery are necessary to prevent damage to the area.

To examine the anatomy of the PEA and MEA, we examined CT images, classified PEA anatomy relative to the ethmoid cell walls, and measured the presence of the PEA

<sup>1</sup>Department of Otolaryngology, Jichi Medical University Saitama Medical Center, Saitama, Japan

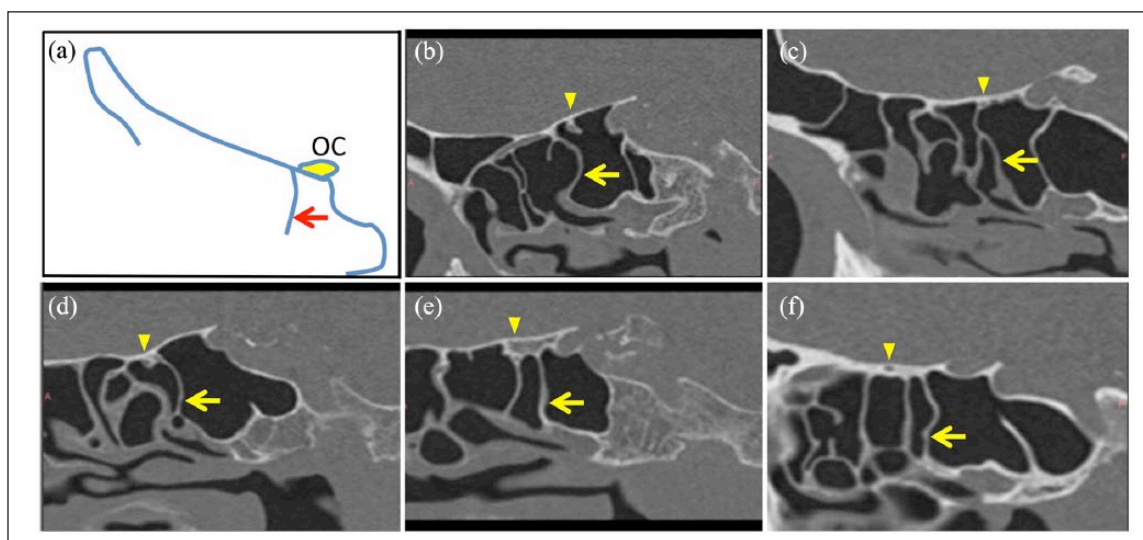
<sup>2</sup>Department of Otolaryngology-Head and Neck Surgery, Tohoku University Graduate School of Medicine, Sendai, Japan

## Corresponding author:

Kazuhiro Nomura, Department of Otolaryngology-Head and Neck Surgery, Tohoku University Graduate School of Medicine, 1-1 Seiryomachi, Aoba-ku, Sendai 980-8574, Miyagi, Japan.

Email: nomura@ori.med.tohoku.ac.jp





**Figure 1.** Classification of the PEA: (a) FW, (b) type 1, (c) type 2, (d) type 3, (e) type 4, and (f) type 5. Arrows indicate FW; arrowheads indicate PEA. OC: optic canal.

and MEA as well as their distances from the skull base and their exposed lengths in the ethmoid cells. We then tested the hypotheses that the PEA distance from the ethmoid roof is associated with the patient's age and sex, presence of the MEA, and anatomical type of the PEA.

## Methods

We reviewed CT images of unaffected sinuses in scans originally taken for the temporal bone. CT images of the paranasal sinus region were taken at the Department of Otolaryngology, Jichi Medical University, Saitama Medical Center, between April and December 2015.

The exclusion criteria were previous surgery on the sino-nasal area, rhinosinusitis, and post-traumatic change. The CT images of 100 patients were included, and anatomical variations were measured and classified. To calculate sample size, we set allowable error, standard deviation, and reliability to 0.5 mm, 3.5 mm, and 95%, respectively. The required sample size for this study was 191. The sample size selected for this study was comparable to those of prior studies focused on the ethmoidal arteries.<sup>1,2,4-8</sup>

Thin-slice images (0.5 mm thick) were taken using CT (Aquilion ONE, Toshiba Medical Systems Corporation, Otawara, Japan). Data were processed using a three-dimensional Digital Imaging and Communications in Medicine (DICOM) viewer (Ziostation version 4.1.7.2; Ziosoft, Tokyo, Japan). All examinations were based on three-dimensional images. The PEA was identified as the first-appearing transverse canal on coronal sections viewed in a posterior to anterior manner. The second canal appearing on coronal sections was identified as the MEA if it was not the AEA.

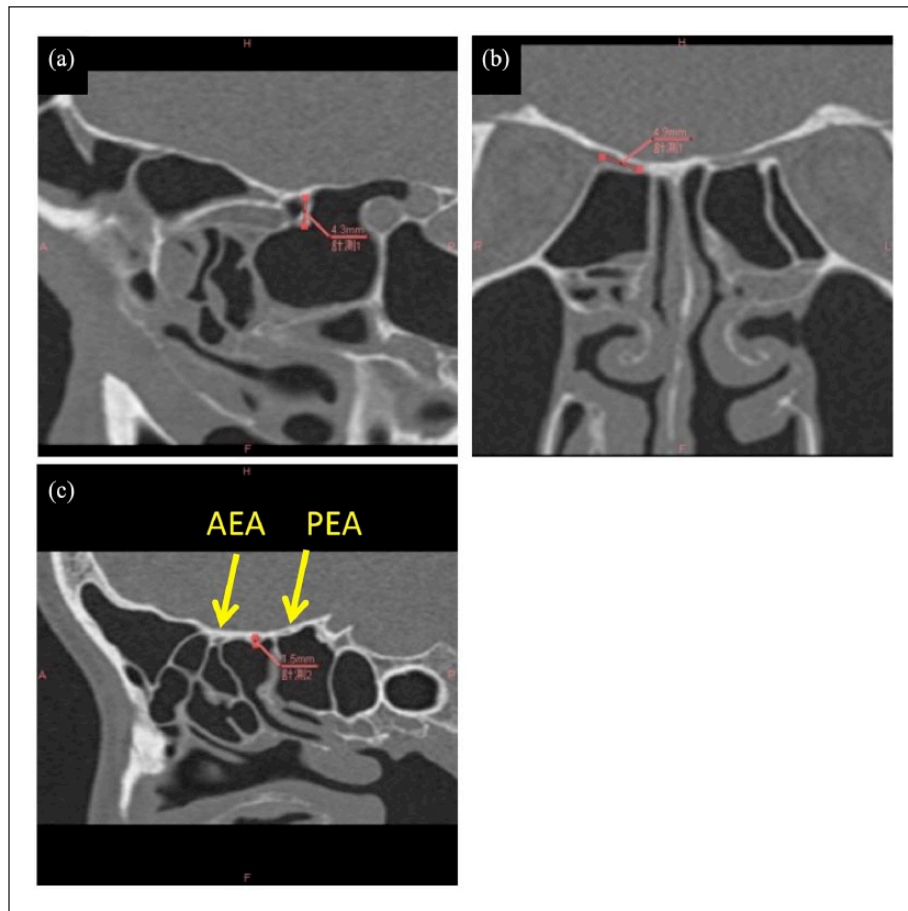
We classified the PEA anatomy into five types depending on its relation to the ethmoid cell walls. It is not practical to

use the anterior wall of the sphenoid sinus because of its variation; that is, the anterior wall of the sphenoid sinus can exist either anterior to, inside, or posterior to the optic canal.<sup>12</sup> On sagittal images in which the optic nerve crossed the lamina papyracea, we defined the first wall anterior to the optic canal as the first wall (FW). We classified the PEA position relative to the FW as follows (Figure 1): type 1, the PEA is located posterior to the FW; type 2, the PEA is located inside the FW; type 3, the PEA is located in the ethmoid cells facing the FW posteriorly; type 4, the PEA is located inside the second wall anterior to the optic canal; and type 5, the PEA is located anterior to the second wall that is anterior to the optic canal. In cases of types 3–5, the anterior face of the sphenoid sinus is the FW.

Measurement of the PEA distance from the ethmoid roof was based on sagittal sections (Figure 2(a)). The PEA distance was defined as the distance from the most prominent portion of the PEA to the skull base. Measurements of the length of the PEA and MEA exposed in the ethmoid cells were based on coronal sections (Figure 2(b)). Measurement of the MEA distance from the ethmoid roof was based on sagittal sections (Figure 2(c)). All measurements were performed by a single person (H.Y.). The study was approved by the institutional review board of Jichi Medical University, Saitama Medical Center (#S17-067).

## Statistical analysis

Continuous variables were expressed as mean  $\pm$  standard deviation (SD). Age, sex, anatomical type of the PEA (Figure 1), length of the PEA exposed in the ethmoid cells, and presence of the MEA were analyzed as possible factors associated with the PEA distance from the skull base. The relationships between these clinical factors and the



**Figure 2.** Measurements from CT: (a) PEA distance from the skull base on sagittal CT scan, (b) length of the PEA exposed in the ethmoid cells on coronal CT scan, and (c) MEA distance from the skull base on sagittal CT scan. Bar indicates the measured distance. AEA: anterior ethmoidal artery; PEA: posterior ethmoidal artery.

**Table 1.** Patient characteristics and anatomical measurements.

	Mean (SD)	n (%)
Age (years)	55.4 (16.6)	
Sex		
Male		50 (50)
Age (years)	52.5 (17.6)	
Female		50 (50)
Age (years)	58.3 (15.2)	
PEA		
Presence		200 (100)
Distance from the skull base (mm)	1.2 (1.0)	
Length exposed in the ethmoid cells (mm)	6.0 (2.5)	
MEA		
Presence		42 (21)
Distance from the skull base (mm)	1.0 (0.6)	
Length exposed in the ethmoid cells (mm)	3.9 (1.7)	

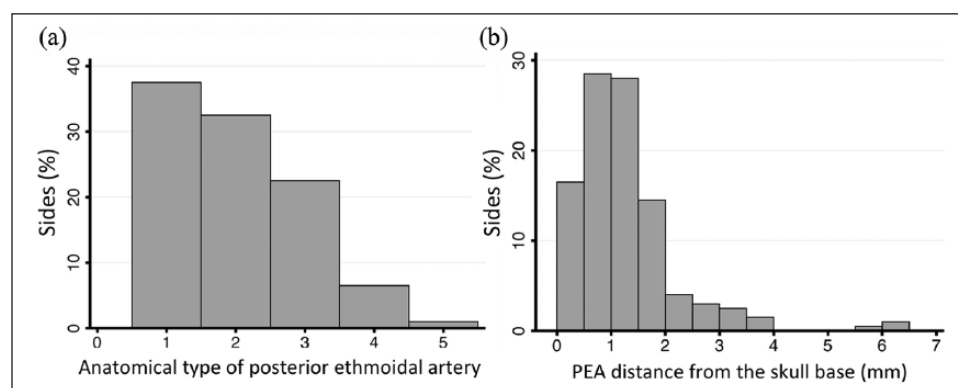
SD: standard deviation; PEA: posterior ethmoidal artery; MEA: middle ethmoidal artery.

PEA distance from the skull base were determined using multivariate linear regression analysis. Statistical analysis of all data was performed using Stata version 14.0 (StataCorp, College Station, TX, USA). A two-tailed  $p$  value  $< 0.05$  was considered statistically significant.

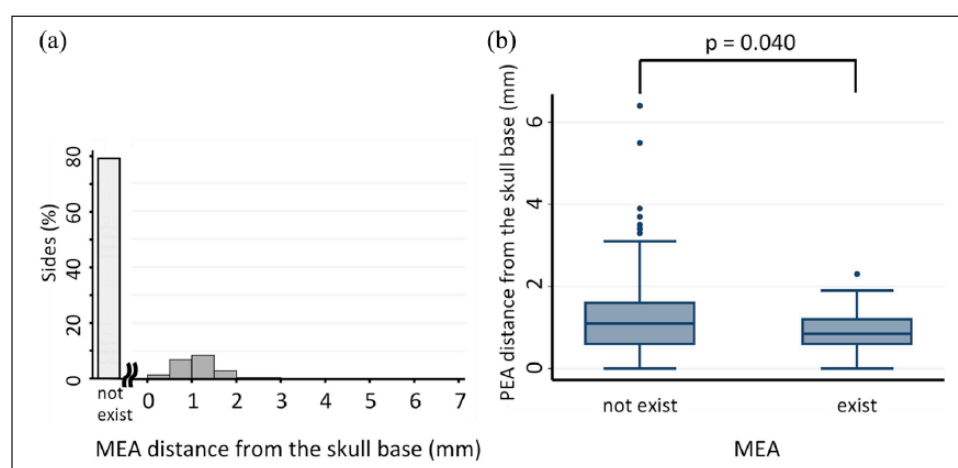
## Results

CT images from 100 patients (200 sides) were analyzed in this study. The primary diagnoses of the patients were cholesteatoma (48 patients), chronic otitis media (46 patients), otosclerosis (2 patients), sensorineural hearing loss (1 patient), mixed hearing loss (1 patient), external auditory canal cholesteatoma (1 patient), and external auditory canal tumor (1 patient). Patient characteristics, including age and sex, and anatomical measurements are summarized in Table 1.

The PEA was present in all nasal cavities and was generally located near the FW (Figures 1 and 3(a)). The PEA was rarely present inside or anterior to the second wall anterior to the optic canal. The PEA distance from the skull base ranged



**Figure 3.** Characteristics of the posterior ethmoidal artery (PEA): (a) frequency of each anatomical type of the PEA based on Figure 1 and (b) PEA distance from the skull base.



**Figure 4.** (a) Middle ethmoidal artery (MEA) distance from the skull base. MEA was absent in 79% of nasal cavities. (b) Absence of the MEA was positively associated with a longer PEA distance from the skull base.

from 0 to 6.4 mm (Figure 3(b)) and was more than 2.0 mm in 24 sides (12%).

The MEA was present in 21% of nasal cavities. The MEA distance from the skull base ranged from 0 to 2.7 mm (Figure 4(a)) and was more than 2.0 mm in two sides (1%).

Multivariate regression analysis indicated that older age, longer length of the PEA exposed in the ethmoid cells, and absence of the MEA were positively associated with a longer PEA distance from the skull base (Table 2, Figures 4(b) and 5). Sex and anatomical type of the PEA were not associated with the PEA distance from the skull base.

## Discussion

Our study had four major findings. First, the PEA was mostly present beside or inside the FW. Second, the PEA distance from the skull base was more than 2.0 mm in 24 sides (12%). Third, the MEA was present in 42 sides (21%), and its distance was more than 2.0 mm in two sides (1%). Finally, the PEA distance from the skull base was positively associated

with advanced age, length of the PEA exposed in the ethmoid cells, and absence of the MEA.

It is important to recognize the location of the ethmoidal arteries during endoscopic endonasal surgery. This involves understanding the relation of the arteries to the surrounding structures, which enables easier identification during endoscopic sinus surgery.<sup>1,13</sup> We chose the ethmoid cell walls as the landmark to aid in PEA identification as they are easy to identify and are adjacent to the PEA. Complex anatomical variations around the posterior ethmoid and sphenoid sinuses exist. An Onodi cell, defined as the posterior ethmoid cell that develops laterally and/or superiorly to the sphenoid sinus, is not suitable as a landmark because it is difficult to determine accurately.<sup>12</sup> We used the FW as a landmark to avoid considering the different types of Onodi cells. When the surgeon identifies the optic canal, determining the first cell wall anterior to the optic canal is straightforward.

The PEA was most commonly present posterior to the FW running along the skull base (Figures 1(b) and 3(a)). The next most common type was a PEA running inside the FW

(Figure 1(c)). In total, a PEA running around the FW (types 1, 2, and 3) was present in 92.5% of nasal cavities. The anatomical type of the PEA was not associated with its distance from the skull base (Table 2). During surgery, caution should be exercised when dissecting the FW.

The incidence rate of a floating PEA that was more than 2 mm from the skull base (12%) was similar to that of the AEA from a previous study. The incidence rate of a floating AEA 2–3 mm from the skull base was 14.3% (10 of 70 cases).<sup>1</sup> However, Cankal et al.<sup>2</sup> reported that the AEA and PEA were identified as separate canals in 84% and 8% of cases, respectively. This huge discrepancy may have resulted from a difference in study design and ethnic-based anatomical heterogeneity.<sup>14</sup> Moon et al. simultaneously employed CT and cadaver dissection, whereas Cankal et al. used CT with a minimum thickness of 1.0 mm. In our study, we used 0.5-mm-thick slices in a three-dimensional manner. These thin-slice CT images, which had a different cut thickness compared to most CT images for sinuses, aided in identifying the PEA and MEA. The identifications might be missed on thicker cut scans, which are the standard in most sinus surgeries. There are more studies on AEA anatomy than on PEA anatomy. The AEA has received more focus, as the anatomy of the frontal recess is complicated and accidental injury to the AEA is possible during frontal sinus surgery. As

the skills and knowledge of surgeons improve and more advanced instruments are developed, more meticulous surgeries will be performed. It is possible that meticulous dissection of the FW has been unnecessary from the viewpoint of functional endoscopic sinus surgery, in which the aim is to create a drainage pathway to the sinuses.<sup>15</sup> A recent study showed that complete removal of the ethmoid cells without any residual lamina reduces the risks of recurrent chronic rhinosinusitis.<sup>16</sup> Very little data are available concerning the benefits of meticulous surgery compared to functional surgery.<sup>17</sup> However, meticulous dissection is still necessary in endoscopic endonasal skull base surgery, which has been widely performed with the advancements in surgical instruments and techniques.<sup>18,19</sup> Conversely, recognizing the PEA through a transethmoidal trajectory helps to localize the optic nerve in advance, thus minimizing the possibility of injury to the nerve.

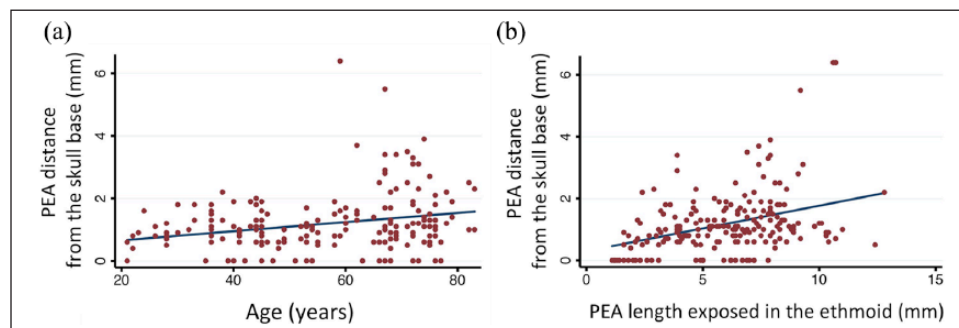
In contrast to the PEA, which was present in all nasal cavities, the MEA was detected in only 21% of patients (Table 1, Figure 4(a)). This number is similar to that in a cadaver study in which the MEA was present in 31.8%–33% of autopsies.<sup>8,11</sup> A recent study on cone beam CT reported that the MEA was identified in 28.6% of nasal cavities.<sup>20</sup> When present, its mean distance from the skull base was 1.0 mm, which was close to that of the PEA (1.2 mm). Unlike the PEA, an extremely long distance from the skull base was not observed with the MEA (Figures 3(b) and 4(a)). The MEA distance from the skull base was more than 2.0 mm in two sides. Although caution should always be exercised, the risk of MEA injury may be lower than that of PEA injury.

The PEA distance from the skull base was positively associated with advanced age, length of the PEA exposed in the ethmoid cells, and absence of the MEA (Table 2). A significant association was observed between the PEA distance from the skull base and advanced age (Figure 5(a)). The reason for this association is not clear, but a possible explanation would be bone remodeling with aging and differences in environmental factors between generations. Although the effect of age is minor considering the interindividual

**Table 2.** Multiple regression analysis of factors associated with longer PEA distance from the skull base.

	Coef.	p	95% CI
Age	0.01	.007	0.00 to 0.02
Sex (male)	−0.21	.118	−0.48 to 0.05
Anatomical type of the PEA	−0.03	.540	−0.14 to 0.07
Length of the PEA	0.14	<.001	0.08 to 0.19
Presence of the MEA	−0.34	.040	−0.66 to −0.02
Constant term	0.00	.990	−0.61 to 0.60

Coef.: regression coefficient; CI: confidence interval; PEA: posterior ethmoidal artery; MEA: middle ethmoidal artery.



**Figure 5.** Posterior ethmoidal artery (PEA) distance from the skull base was associated with age and length of the PEA exposed in the ethmoid cells: (a) scatter graph of the PEA distance from the skull base versus age with fitted line and (b) scatter graph of the PEA distance from the skull base versus length of the PEA exposed in the ethmoid cells with fitted line.



variability, attention is needed when performing endoscopic sinus surgery in older patients.

The length of the PEA exposed in the ethmoid cells was positively associated with the PEA distance from the skull base (Figure 5(b)). The length of the PEA exposed is longer in patients in whom the distance between the orbit and nasal septum is long. This applies to the length of the MEA as well. Attention is needed when performing surgery to well-pneumatized ethmoid cells.

The presence of the MEA was negatively associated with the PEA distance from the skull base. The MEA and PEA supply the nasal septum and ethmoid cells. A reduced blood supply from the MEA leads to an increase in flow through the PEA. When the PEA distance from the skull base is short, the surgeon should pay attention to the presence of the MEA.

Some limitations of the present study must be considered. Images for measurements were reconstructed from 0.5-mm-thick slice CT data. Thus, measured figures less than 0.5 mm are unreliable. Because this study analyzed CT images from the Japanese population, the measurements may be biased. Ethnic variations in the sino-nasal anatomy exist.<sup>14</sup> The PEA and MEA distances from the skull base and their association with age and sex might be different in other ethnic groups.

## Conclusion

The PEA distance from the skull base was more than 2.0 mm in 24 sides (12%), which was similar to that of the AEA distance in a previous study. The PEA distance from the skull base was positively associated with advanced age, length of the PEA exposed in the ethmoid cells, and absence of the MEA. The MEA existed in patients in whom the PEA distance from the skull base was short. When examining CT images, attention should be paid not only to the AEA but also to the PEA and MEA.

## Declaration of conflicting interests

The author(s) declared no potential conflicts of interest with respect to the research, authorship, and/or publication of this article.

## Ethical approval

Ethical approval for this study was obtained from the institutional review board of Jichi Medical University Saitama Medical Center (#S17-067).

## Funding

The author(s) received no financial support for the research, authorship, and/or publication of this article.

## Informed consent

The requirement for written informed consent was waived by the institutional review board and hence not obtained. All data used were previously collected to evaluate and treat ear diseases. We reviewed and analyzed the data without any need for additional physical or psychological examinations or tests.

## ORCID iD

Kazuhiro Nomura  <https://orcid.org/0000-0002-6425-4574>

## References

1. Moon HJ, Kim HU, Lee JG, et al. Surgical anatomy of the anterior ethmoidal canal in ethmoid roof. *Laryngoscope* 2001; 111(5): 900–904.
2. Cankal F, Apaydin N, Acar HI, et al. Evaluation of the anterior and posterior ethmoidal canal by computed tomography. *Clin Radiol* 2004; 59(11): 1034–1040.
3. Bayram M, Sirikci A and Bayazit YA. Important anatomic variations of the sinonasal anatomy in light of endoscopic surgery: a pictorial review. *Eur Radiol* 2001; 11(10): 1991–1997.
4. Erdogmus S and Govsa F. The anatomic landmarks of ethmoidal arteries for the surgical approaches. *J Craniofac Surg* 2006; 17(2): 280–285.
5. Ding J, Sun G, Lu Y, et al. Evaluation of anterior ethmoidal artery by 320-slice CT angiography with comparison to three-dimensional spin digital subtraction angiography: initial experiences. *Korean J Radiol* 2012; 13(6): 667–673.
6. Celik S, Ozer MA, Kazak Z, et al. Computer-assisted analysis of anatomical relationships of the ethmoidal foramina and optic canal along the medial orbital wall. *Eur Arch Otorhinolaryngol* 2015; 272(11): 3483–3490.
7. Jang DW, Lachanas VA, White LC, et al. Supraorbital ethmoid cell: a consistent landmark for endoscopic identification of the anterior ethmoidal artery. *Otolaryngol Head Neck Surg* 2014; 151(6): 1073–1077.
8. Wang L, Youseef A, Al Qahtani AA, et al. Endoscopic anatomy of the middle ethmoidal artery. *Int Forum Allergy Rhinol* 2014; 4(2): 164–168.
9. Perrini P, Cardia A, Fraser K, et al. A microsurgical study of the anatomy and course of the ophthalmic artery and its possibly dangerous anastomoses. *J Neurosurg* 2007; 106(1): 142–150.
10. Isolan GR, de Aguiar PHP, Laws ER, et al. The implications of microsurgical anatomy for surgical approaches to the sellar region. *Pituitary* 2009; 12(4): 360–367.
11. Lang J. Ethmoidal cells arising from the superior (and supreme) nasal meatus. In: Lang J (ed.) *Clinical anatomy of the nose, nasal cavity and paranasal sinuses*. New York: Thieme, 1989, pp. 81–84.
12. Wada K, Moriyama H, Edamatsu H, et al. Identification of Onodi cell and new classification of sphenoid sinus for endoscopic sinus surgery. *Int Forum Allergy Rhinol* 2015; 5(11): 1068–1076.
13. Abuzayed B, Tanriover N, Gazioglu N, et al. Endoscopic endonasal anatomy and approaches to the anterior skull base: a neurosurgeon's viewpoint. *J Craniofac Surg* 2010; 21(2): 529–537.
14. Badia L, Lund VJ, Wei W, et al. Ethnic variation in sinonasal anatomy on CT-scanning. *Rhinology* 2005; 43(3): 210–214.
15. Stammberger H and Posawetz W. Functional endoscopic sinus surgery. Concept, indications and results of the Messerklinger technique. *Eur Arch Otorhinolaryngol* 1990; 247(2): 63–76.
16. Okushi T, Mori E, Nakayama T, et al. Impact of residual ethmoid cells on postoperative course after endoscopic sinus surgery for chronic rhinosinusitis. *Auris Nasus Larynx* 2012; 39(5): 484–489.

17. Fokkens WJ, Lund VJ, Mullol J, et al. European position paper on rhinosinusitis and nasal polyps 2012. *Rhinol Suppl* 2012; 50: 1–12.
18. Hadad G, Bassagasteguy L, Carrau RL, et al. A novel reconstructive technique after endoscopic expanded endonasal approaches: vascular pedicle nasoseptal flap. *Laryngoscope* 2006; 116(10): 1882–1886.
19. Snyderman CH, Carrau RL, Kassam AB, et al. Endoscopic skull base surgery: principles of endonasal oncological surgery. *J Surg Oncol* 2008; 97(8): 658–664.
20. Ferrari M, Pianta L, Borghesi A, et al. The ethmoidal arteries: a cadaveric study based on cone beam computed tomography and endoscopic dissection. *Surg Radiol Anat* 2017; 39(9): 991–998.