

Educational Case: Membranous Nephropathy

Academic Pathology
Volume 5: 1–6
© The Author(s) 2018
Article reuse guidelines:
sagepub.com/journals-permissions
DOI: 10.1177/2374289518813673
journals.sagepub.com/home/apc



Christina C. Smith, MS¹ and Richard Michael Conran, MD, PhD, JD¹

The following fictional case is intended as a learning tool within the Pathology Competencies for Medical Education (PCME), a set of national standards for teaching pathology. These are divided into three basic competencies: Disease Mechanisms and Processes, Organ System Pathology, and Diagnostic Medicine and Therapeutic Pathology. For additional information, and a full list of learning objectives for all three competencies, see <http://journals.sagepub.com/doi/10.1177/2374289517715040>.

Keywords

pathology competencies, organ system pathology, kidney, glomerular disorder, nephrotic syndrome, nephritic syndrome, membranous nephropathy

Received August 21, 2018. Received revised October 08, 2018. Accepted for publication October 22, 2018.

Primary Objective

Objective UTK5.2: Nephrotic Syndrome. Describe the pathophysiology and morphologic features of nephrotic syndrome and contrast with nephritic syndrome.

Competency 2: Organ System Pathology; Topic UTK: Kidney; Learning Goal 5: Renal Syndromes.

Patient Presentation

A 48-year-old Caucasian male with no previous medical history presented to his family physician complaining of widespread swelling, notably around his eyes and upper and lower extremities. He stated the swelling began 2 months ago and complained his urine had a foamy appearance. He denied fatigue, fever, chills, cough, shortness of breath, chest pain, abdominal pain, nausea, vomiting, diarrhea, constipation, hematuria, and rashes/skin lesions. He denied taking any medications. He did not have a history of diabetes, hypertension, heart disease, liver disease, or cancer. He denied using tobacco products or illicit drugs but had consumed alcohol on occasion (1-2 drinks, 1-2 times per month).

Diagnostic Findings, Part I

On physical examination, vital signs showed a temperature of 98°F, a heart rate of 82 beats per minute, a respiratory rate of 16

breaths per minute, and a blood pressure of 128/84 mm Hg. Physical examination showed a well-appearing male with bilateral periorbital edema, 1+ pitting edema two-thirds of the way from the wrists to the elbows bilaterally with moderately edematous hands and wrists, and 2+ pitting edema to the knees bilaterally with markedly edematous feet and ankles. There was shifting dullness on percussion of the posterior thorax. The remainder of the examination was unremarkable.

Questions/Discussion Points, Part I

What Is the Differential Diagnosis Based on the History and Physical Examination?

The differential diagnosis of generalized edema includes a glomerulopathy, heart failure, liver disease, myxedema, lymphatic obstruction, and medications. Given the patient's urinary complaint, the glomerulopathies were given particular consideration.

¹ Eastern Virginia Medical School, Norfolk, VA, USA

Corresponding Author:

Richard Michael Conran, Eastern Virginia Medical School, 700 West Olney, Norfolk, VA 23501, USA.

Email: conranrm@evms.edu



Creative Commons Non Commercial No Derivs CC BY-NC-ND: This article is distributed under the terms of the Creative Commons Attribution-NonCommercial-NoDerivs 4.0 License (<http://www.creativecommons.org/licenses/by-nc-nd/4.0/>) which permits non-commercial use, reproduction and distribution of the work as published without adaptation or alteration, without further permission provided the original work is attributed as specified on the SAGE and Open Access pages (<https://us.sagepub.com/en-us/nam/open-access-at-sage>).

Diagnostic Findings, Part 2

Laboratory Studies

An extensive laboratory workup including a complete blood count, comprehensive metabolic panel, prothrombin time, lipid profile, thyroid profile, urinalysis, and electrocardiogram was conducted. The complete blood count, prothrombin time, thyroid profile, and electrocardiogram were within reference ranges. The comprehensive metabolic panel showed a serum albumin of 1.8 g/dL. The lipid profile showed total cholesterol of 324 mg/dL and triglycerides of 300 mg/dL. The urinalysis showed significant proteinuria (4+).

The findings prompted the following laboratory workup to determine etiology. An antinuclear antibody test, serum C3 and C4 complement levels, hepatitis B and C and HIV serologies, and a 24-hour urine collection were ordered. The antinuclear antibody test, serum C3 and C4 complement levels, and hepatitis B and C and HIV serologies were within reference ranges. The 24-hour urine collection showed 5.5 g/d of protein.

Imaging

Standard erect and lateral decubitus chest radiographs were ordered. The lateral film showed a 3-mm-thick fluid layer (approximately 60 mL of fluid). The posteroanterior film was unremarkable.

Questions/Discussion Points, Part 2

What Is the Differential Diagnosis Based on the Laboratory Findings?

The tetrad of edema, proteinuria, hypoalbuminemia, and hyperlipidemia define the nephrotic syndrome, which may be caused by a primary glomerular disease or be secondary to a systemic disease such as diabetes mellitus, systemic lupus erythematosus, amyloidosis, or certain infections (hepatitis B and C and HIV) or malignancies.^{1,2} As the patient's glucose level, antinuclear antibody test, serum C3 and C4 complement levels, prothrombin time, thyroid profile, and hepatitis B and C and HIV serologies were within reference ranges and his history was negative for malignancy, all secondary causes from the differential diagnosis were eliminated. The primary causes of nephrotic syndrome—membranous nephropathy, minimal change disease, focal segmental glomerulosclerosis, and membranoproliferative glomerulonephritis—were still considered.

What Is the Pathogenesis of Nephrotic Syndrome and How Does It Differ From That of Nephritic Syndrome?

The nephrotic syndrome is a collection of symptoms that result from increased permeability of the glomerular capillary walls.¹⁻⁴ In contrast, the nephritic syndrome is a collection of symptoms that result from glomerular inflammation.^{1-3,5} Both syndromes are caused by immune-mediated injury to the kidney glomerulus.^{1,2,5,6}

Although cell-mediated immunity plays a role in certain glomerulopathies, most are the result of antibody-mediated mechanisms.^{1,5,6} In antibody-mediated glomerular injury, antibodies either react locally, forming immune complexes in situ, or are circulating and form complexes in the bloodstream that later become trapped within the glomeruli.¹ Regardless of the site of their formation, these antigen-antibody complexes deposit in various parts of the glomeruli. To best appreciate this, an understanding of glomerular anatomy is essential and is reviewed here.

The glomerulus is an anastomosing arrangement of capillaries lined directly by a fenestrated endothelium then 2 layers of epithelium—visceral and parietal—that encapsulate Bowman's space, where glomerular filtrate collects.^{1,3,5} The entire glomerular tuft is supported by mesangium, a group of cells that lie between the capillaries.^{1,3,5} Immune complexes may deposit between the visceral epithelial cells and the glomerular capillary wall (subepithelial space), between the glomerular capillary wall and the endothelium (subendothelial space), or in the mesangium.

The site of immune complex deposition gives rise to the varied histology of glomerular disease. For instance, immune complex deposits confined to the subepithelial space, as seen in some cases of nephrotic syndrome, are not exposed to blood elements, and generally do not have an inflammatory pathology.^{1,6} Deposits in the subendothelial space and mesangium, however, are accessible to the circulation and elicit the inflammatory response seen in most causes of nephritic syndrome.^{1,6}

How Does the Pathophysiology of Nephrotic Syndrome Explain Its Clinical Presentation? How Does the Pathophysiology of Nephritic Syndrome Explain Its Clinical Presentation?

In nephrotic syndrome, capillary wall derangement allows protein—notably albumin—to leak from the bloodstream into the urine, causing immense proteinuria (in excess of 3.5 g/d) and consequent hypoalbuminemia.^{1,3} This depletion of protein in the bloodstream decreases capillary oncotic pressure, which promotes fluid movement from the bloodstream into the interstitium (causing generalized edema) or into body cavities such as the thorax or abdomen (causing pleural effusion or ascites).^{1,3} As fluid leaves the bloodstream, a decrease in the effective circulating volume is seen.^{1,3} This decrease in vascular volume leads to a decrease in renal plasma flow and subsequently a decrease in glomerular filtration.^{1,3} A decreased glomerular filtration rate stimulates the renin-angiotensin-aldosterone system and ultimately leads to an increase in sodium and water retention, which further aggravates the edema.^{1,3}

Additionally, the hypoalbuminemia stimulates increased synthesis of lipoproteins by the liver, resulting in hyperlipidemia.^{1,3} The mechanism behind this synthesis is not yet fully understood, but is not a simple compensatory mechanism,

given that lipoproteins will not sufficiently increase the plasma oncotic pressure to normal because of their large size.⁷

In nephritic syndrome, inflammatory processes damage the entire glomeruli, which allows spillage of red blood cells (hematuria) and protein into the urine.^{1,3} Of note, the proteinuria seen in nephritic syndrome is notably less than that seen in nephrotic syndrome because the inflamed glomeruli somewhat limit the passage of protein.^{1,3} As the damaged glomeruli are unable to appropriately filter the plasma flow, there is an increase in the blood urea nitrogen and creatinine concentrations (azotemia). Moreover, there is a decrease in the production of urine (oliguria) and consequent rise in capillary hydrostatic pressure.^{1,3} Elevated hydrostatic pressure leads to hypertension and stimulates fluid movement from the bloodstream to the interstitium, which leads to edema.^{1,3} The edema may also be a result of the proteinuria (via the same mechanism discussed with nephrotic syndrome).

Diagnostic Findings, Part 3

What Is the Next Step in Determining the Cause of the Patient's Nephrotic Syndrome?

A renal biopsy is indicated. The sample contained one core of renal cortex that contained 9 glomeruli. Light microscopy showed diffuse thickening of the glomerular capillary walls throughout all of the glomeruli. The endothelium, mesangium, and interstitium were unremarkable. No proliferative features were seen (Figures 1-3). Basement membrane spikes were evident with methenamine silver stain (Figure 3). Immunofluorescence microscopy demonstrated a diffuse granular pattern that stained positive for IgG and C3 (Figure 4). Electron microscopy demonstrated subepithelial basement membrane electron-dense deposits (antigen-antibody complexes) (Figure 5). Based on the findings on light, electron, and immunofluorescence microscopy, the diagnosis of membranous nephropathy was made.

Questions/Discussion Points, Part 3

What Is Membranous Nephropathy? How Does the Disease-Specific Pathogenesis Explain Its Morphological Presentation and What Is the Disease Treatment?

Membranous nephropathy, one of the primary diseases that cause nephrotic syndrome, occurs when immune complexes deposit within the subepithelial space and subsequently damage the glomerular visceral epithelial cells.^{1,3,6,8} These highly specialized cells—commonly called podocytes—shroud the glomerular capillaries and possess long processes (called foot processes) that interdigitate and form filtration slits.^{1,3,6,8} The filtration slits maintain the glomerular filtration barrier by filtering proteins based on size.^{1,3} As such, injury to these cells results in the massive proteinuria seen in nephrotic syndrome.^{1,3}

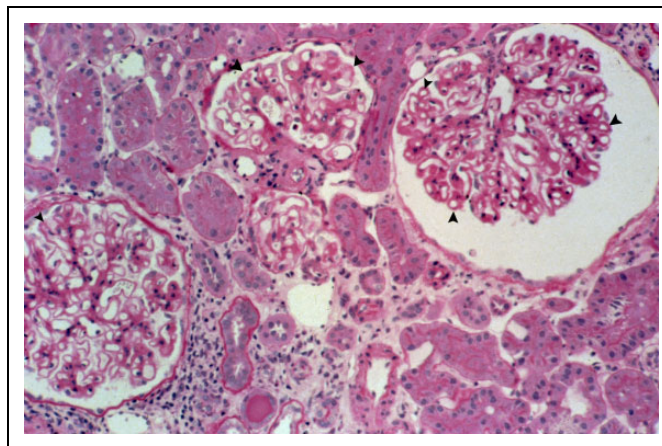


Figure 1. Normocellular glomeruli demonstrating thickening of the capillary walls (arrowheads). (H&E stain, intermediate magnification).

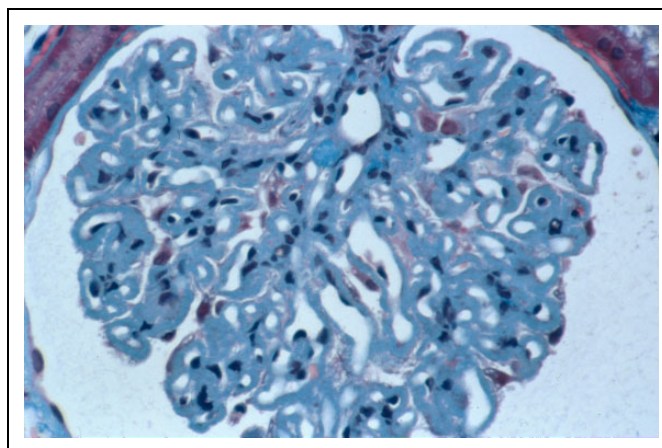


Figure 2. Diffuse thickening of the glomerular capillary wall is seen with no hypercellularity. (Trichrome stain, high power magnification).

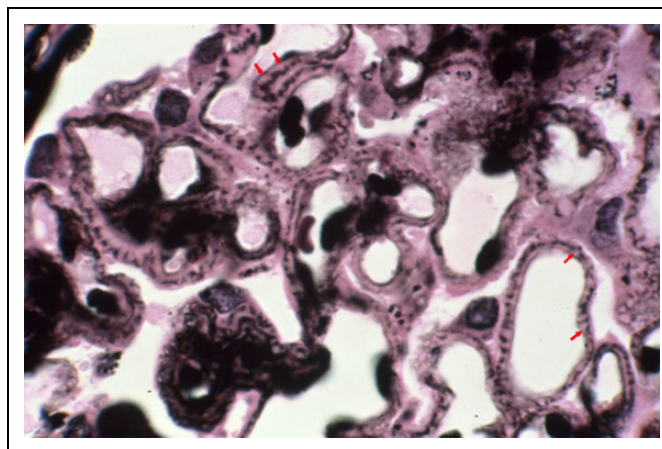


Figure 3. Normocellular glomerulus with diffuse thickening of the capillary wall. The basement membrane matrix that stains positive with the silver stain is seen extending between the subepithelial deposits (red arrows; silver methenamine stain, high power magnification).

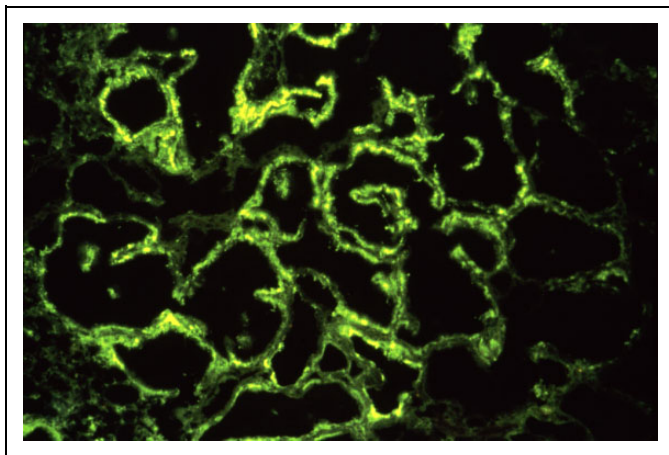


Figure 4. Immunofluorescence microscopy demonstrating a diffuse granular pattern for IgG along the glomerular capillary wall.

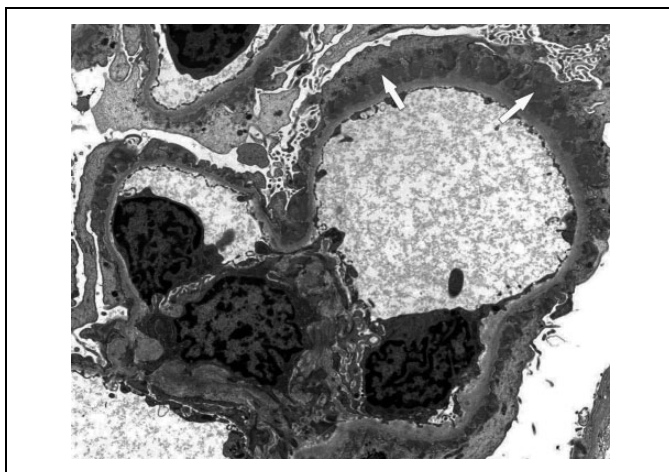


Figure 5. Electron micrograph demonstrating subepithelial electron-dense deposits in the basement membrane (white arrows) along with fusion of the epithelial cell foot processes.

The immune complexes that form in membranous nephropathy may be in response to exogenous or endogenous antigens or to a renal autoantigen, the phospholipase A₂ receptor.^{1,3,5-7} As these complexes deposit in the subepithelial space, thickening of the basement membrane is seen on light microscopy.^{1,3,6} Over time, additional basement membrane is laid down between the deposits, giving the appearance of protruding spikes.^{1,3,6} Eventually, the additional membrane material closes over the deposits, further thickening the basement membrane and effacing part of the overlying podocytes, which can be visualized on electron microscopy.^{1,3,6} As the immune complexes deposit randomly within the subepithelial space, a diffuse granular pattern is seen on immunofluorescence.^{1,3,6}

The disease prognosis is determined by the level of risk (low, moderate, or high) of progressive decline in renal function and is treated with either conservative nonimmunosuppressive therapy or immunosuppressive therapy.^{7,8} While

Table 1. Incidence of Primary Diseases That Cause Nephrotic Syndrome in Adults.^{1,3-5}

Primary Diseases	Approximate Incidence in Adults (% of Primary Disease)	Approximate Incidence in Adults (% of All Diseases That Cause Nephrotic Syndrome)
Minimal change disease	10	6
Focal segmental glomerulonephritis	35	21
Membranous nephropathy	30	18
Membranoproliferative glomerulonephritis	5	3
Other	20	12
Approximate prevalence of primary disease in adults (%)		60

nonimmunosuppressive therapy is administered to nearly all patients with membranous nephropathy, immunosuppressive therapy is given only to those who remain at a moderate or high risk of progression of renal function decline.^{7,8}

What Are the Other Diseases That Cause Nephrotic Syndrome and What Is Their Prevalence? What Are the Diseases That Cause Nephritic Syndrome?

The occurrence of nephrotic syndrome in adults is 3 per 100 000 persons (0.003%) per year.⁴ In addition to membranous nephropathy, the other primary diseases that cause nephrotic syndrome are minimal change disease, focal segmental glomerulosclerosis, and membranoproliferative glomerulonephritis.^{1,3,5} In adults, primary disease accounts for approximately 60% of cases.¹ Refer to Table 1 for the disease incidence of each. Secondary causes of nephrotic syndrome in adults, which account for 40% of cases, commonly include diabetes mellitus, systemic lupus erythematosus, and amyloidosis, with other less common causes being infection and malignancy.^{1,3,5}

The diseases that commonly cause nephritic syndrome include poststreptococcal (or other postinfectious) glomerulonephritis, IgA nephropathy, antiglomerular basement membrane disease, and the small vessel vasculitides (eg, granulomatosis with polyangiitis, microscopic polyangiitis, and eosinophilic granulomatosis with polyangiitis).^{1,3,5}

How Are the Nephrotic and Nephritic Syndromes Diagnosed?

Generally, a diagnosis of nephrotic syndrome is made after urine tests—urinalysis and 24-hour urine collection—have shown nephrotic-range proteinuria and blood chemistries have shown hypoalbuminemia and possibly hyperlipidemia.^{2,4,8} Follow-on laboratory tests and/or a renal biopsy—examined

with light, electron, and immunofluorescence microscopy—are often performed to determine etiology and guide management.^{2,4,8}

A diagnosis of nephritic syndrome is achieved via a similar method. Urinalysis will show hematuria and proteinuria, while blood chemistries will show azotemia, quantified through blood urea nitrogen and creatinine levels.² Follow-on laboratory tests and imaging studies may be performed to determine whether the nephritis is from a primary or secondary cause.² Finally, a renal biopsy may be done if etiology is still uncertain.²

What Are the Morphological Aspects of Renal Biopsies of Patients With Nephrotic Syndrome? How Do They Differ From Renal Biopsies of Patients With Nephritic Syndrome?

As previously mentioned, the morphological presentation of glomerular disease is diverse. The general characteristics of renal biopsies in patients with a glomerulopathy are discussed here, while specific presentations are found in Table 2.

On light microscopy, glomerular injury is described by its location in the glomerulus and by its prevalence in the biopsy sample.^{1,3,6} Injury involving only a portion of the glomerulus is said to be segmental, while that which involves the entire glomerulus is global.^{1,3,6} Injury involving only some of the glomeruli in the sample is said to be focal, while that which involves most or nearly all of the sample's glomeruli is diffuse.^{1,3,6}

Additionally, glomerular injury may cause hypercellularity either from an increase in the number of endothelial or mesangial cells (proliferative) or from an influx of leukocytes from the circulation (exudative).^{1,3,6} Basement membrane thickening, caused by immune complex deposition then formation and addition of new basement membrane material, may also be seen.^{1,3,6} This thickening is typically observed in more chronic forms of glomerular injury.^{1,3,6}

Hyalinosis and sclerosis are 2 other tissue responses seen in long-standing injury to the glomerulus.^{1,3,6} Hyalinosis is the accumulation of hyalin, a homogenous composition of plasma proteins, while sclerosis is the hardening of tissue from abnormal extracellular matrix deposition.^{1,3,6} Both responses can cause obstruction and obliteration of glomerular capillary lumens.^{1,3,6}

As light microscopy is used for a general assessment of glomerular injury, electron and immunofluorescence microscopy provide a more focused evaluation. Electron microscopy is largely used for visualization of the basement membrane and localization of immune deposits, which present as homogenous and electron-dense.^{1,3,6} Immunofluorescence microscopy is used to further examine these deposits by detecting the presence of certain immune reactants including antibodies such as IgG, IgA, and IgM and complement proteins such as C3, C4, and C1q.^{1,3,6}

What Are Complications of Nephrotic Syndrome? What Are the Complications of Nephritic Syndrome?

There are several complications of nephrotic syndrome, including thrombotic and thromboembolic events, infection, cardiovascular disease, hypovolemic crisis, and acute renal failure.^{1,2,4} The most common of these, thrombosis and thromboembolism,⁹ are discussed below.

Several coagulation proteins have altered levels in nephrotic syndrome.^{1,2,4,9} As certain endogenous anticoagulants such as antithrombin III and proteins C and S are lost in the urine at increased levels, the liver upregulates synthesis of certain coagulation proteins such as factors V and VII, fibrinogen, and von Willebrand factor.^{1,2,4,9} Together, these aberrations lead to a hypercoagulable state, increasing the risk of deep vein thrombosis, renal vein thrombosis, and pulmonary embolism.^{1,2,4,9} Notably, renal vein thrombosis is most common in membranous nephropathy, affecting approximately 30% of patients.⁹

In nephritic syndrome, the most notable complications occur as the symptoms of hypertension and renal insufficiency worsen if not properly managed.^{1,2}

Teaching Points

- Immune-mediated mechanisms, particularly those involving immune complexes, underlie most glomerular diseases.
- Immune complexes that deposit in the glomerulus generally localize within the subepithelial space, subendothelial space, or mesangium.
- The site of immune complex deposition within the glomerulus determines the morphology and clinical presentation of the disease.
- Nephrotic syndrome is a collection of symptoms that results from increased permeability of the glomerular capillary walls.
- The tetrad of proteinuria, hypoalbuminemia, generalized edema, and hyperlipidemia characterize the nephrotic syndrome.
- Nephritic syndrome is a collection of symptoms that results from inflammatory damage of the glomeruli.
- Hematuria, azotemia, oliguria, hypertension, proteinuria, and edema characterize the nephritic syndrome.
- Diffuse thickening of the glomerular capillary wall caused by subepithelial immune complex deposits are the morphological findings of membranous nephropathy.
- The diseases that cause nephrotic syndrome are classified as either primary or secondary. The primary causes commonly include minimal change disease, focal segmental glomerulosclerosis, membranous nephropathy, and membranoproliferative glomerulonephritis. Common secondary causes include diabetic nephropathy, systemic lupus erythematosus, and amyloidosis.

Table 2. Morphologic Findings of Common Glomerulopathies.^{1-3,5,6}

		Light Microscopy	Electron Microscopy	Immunofluorescence Microscopy
Primary glomerular diseases	Common causes of nephrotic syndrome			
	Minimal change disease	Normal	No deposits, podocyte effacement	No immune deposits
	Focal segmental glomerulonephritis	Focal, segmental lesions	No deposits, podocyte effacement	No immune deposits
	Membranous nephropathy	Diffuse capillary wall thickening with no hypercellularity	Diffuse subepithelial deposits	Diffuse granular capillary wall IgG and C3
	Membranoproliferative glomerulonephritis	Diffuse capillary wall thickening with hypercellularity	Diffuse subendothelial deposits	Diffuse granular capillary wall complement, possible IgG
	Common causes of nephritic syndrome			
	IgA nephropathy	Diffuse mesangial lesions with mesangial hypercellularity	Diffuse mesangial deposits	Diffuse granular mesangial IgA
	Antiglomerular basement membrane disease	Focal necrosis and crescents	No deposits	Diffuse linear capillary wall IgG
Secondary glomerular diseases	Postinfectious glomerulonephritis	Diffuse enlarged glomeruli, proliferative and exudative endothelial and mesangial hypercellularity	Diffuse subepithelial hump-like deposits	Diffuse granular IgG and C3 in capillary wall and mesangium
	Small-vessel vasculitides	Focal necrosis and crescents	No deposits	No immune deposits

- The diseases that cause nephritic syndrome include poststreptococcal glomerulonephritis and other postinfectious causes, IgA nephropathy, antiglomerular basement membrane disease, and the small vessel vasculitides.
- A diagnosis of nephrotic or nephritic syndrome is achieved through a combination of patient history, physical examination, and serum and urine studies. A renal biopsy is often done to determine etiology.
- A full assessment of a renal biopsy includes evaluation by light, electron, and immunofluorescence microscopy.
- Important complications of nephrotic syndrome are thrombotic and thromboembolic events, while hypertension and renal insufficiency are the primary complications seen with nephritic syndrome.

Acknowledgment

Images, except for Figure 5, were obtained during the scope of US government employment for Dr. Conran. Figure 5 courtesy of Dr. Jolanta Kowalewska.

Declaration of Conflicting Interests

The author(s) declare no potential conflicts of interest with respect to research, authorship, and/or publication of this article.

Funding

The author(s) received no financial support for the research, authorship, and/or publication of this article.

References

1. Alpers CE, Chang A. The kidney. In: Kumar V, Abbas AK, Aster JC, eds. *Robbins and Cotran Pathologic Basis of Disease*. 9th ed. Philadelphia, PA: Elsevier; 2015:897-957.
2. Teitelbaum I, Kooienga L. Nephrotic syndrome versus nephritic syndrome. In: Lerma EV, Berns JS, Nissenson AR, eds. *CURRENT Diagnosis and Treatment: Nephrology and Hypertension*. New York, NY: McGraw-Hill; 2009:211-216.
3. Jennette JC. The kidney. In: Strayer DS, Rubin E, Saffitz JE, Schiller AL, eds. *Rubins Pathology: Clinicopathologic Foundations of Medicine*. 7th ed. Baltimore, MD: Wolters-Kluwer; 2015:903-958.
4. Kodner C. Diagnosis and management of nephrotic syndrome in adults. *Am Fam Physician*. 2016;93(6):479-485.
5. Lewis JB, Neilson EG. Glomerular diseases. In: Kasper DL, Fauci AS, Hauser SL, Longo DL, Jameson JL, Loscalzo J, eds. *Harrison's Principles of Internal Medicine*. 19th ed. New York, NY: McGraw-Hill; 2015.
6. Johnson RJ, Floege J, Feehally J. Introduction to glomerular disease: histologic classification and pathogenesis. In: Johnson RJ, Floege J, Feehally J, eds. *Comprehensive Clinical Nephrology*. 5th ed. Philadelphia, PA: Elsevier; 2015:198-207.
7. Cattran DC. Treatment of idiopathic membranous nephropathy. In: Lam AQ, Glasscock RJ, Fervenza FC, eds. *UpToDate*. Waltham, MA: UpToDate; 2018. Accessed May 18, 2018.
8. Fervenza FC, Sethi S, Specks U. Idiopathic membranous nephropathy: diagnosis and treatment. *Clin J Am Soc Nephro*. 2008;3:905-919.
9. Kerlin BA, Ayoob R, Smoyer WE. Epidemiology and pathophysiology of nephrotic syndrome-associated thromboembolic disease. *Clin J Am Soc Nephro*. 2012;7:513-520.