

# Complications of polyacrylamide hydrogel augmentation mammoplasty: A case report and review of the literature

J Winter BSc, S Shiga MD, A Islur MD FRCSC

J Winter, S Shiga, A Islur. Complications of polyacrylamide hydrogel augmentation mammoplasty: A case report and review of the literature. *Plast Surg Case Studies* 2016;2(3):47-50.



The use of polyacrylamide hydrogel (PAAG) as an injectable filler for breast augmentation has fallen out of popularity since its first use in the 1980s, but has produced an increasing patient population presenting with complications related to PAAG injections. PAAG use was popularized most notably in China, Russia and Iran. However, given immigration trends and medical tourism, PAAG-related complications have become increasingly more common in North America. These complications can be difficult to treat, often necessitating complex surgery that includes gel removal, debridement procedures and, often, breast reconstruction. Approaches to surgical treatment and subsequent breast reconstruction are not universally defined primarily because of the limited knowledge about this group of patients. The present article presents the option of autologous free flap reconstruction for a patient with extensive muscular involvement, and aims to summarize complications and risks associated with PAAG through a case presentation and literature review.

**Key Words:** *Autologous breast reconstruction; Breast augmentation; Polyacrylamide hydrogel*

Polyacrylamide hydrogel (PAAG) injectable filler is a 2.5% cross-linked polyacrylamide combined with nonpyrogenic water. No clinical trials were ever conducted for the safety and use of PAAG for tissue augmentation. However, it was used for >2 decades in the treatment of breast tissue atrophy, reconstruction following malignant tumour mastectomy and breast augmentation due to mammary dysplasia (1,2). This form of augmentation was popularized in the former Soviet Union, and was most notably practiced in Russia, China and Iran (3). PAAG injections were further portrayed by the media and advertised as a relatively inexpensive procedure requiring no anesthesia or surgical skill, and could be performed in an office setting (4). As many as 300,000 women have been treated for PAAG injections (5). PAAG injections have been used in both legal and illegal institutions, such as beauty parlours, by nonmedical professionals (2).

Aquamid (Contura International, Denmark) is a representative of PAAG. The monomer of Aquamid in low-enough concentrations has been regarded as atoxic to humans and animals. However, the acrylamide monomer possesses neurotoxicity and teratogenicity. These monomers can often be residually present during the synthesis of PAAG, which has potential to cause toxicity to nerve and muscle function (1,5). With these findings, in 2006, the Chinese State Food and Drug Administration announced that PAAG would be prohibited from production and clinical application in plastic surgery (6).

We are now progressing into the era in which we can expect to see patients presenting for treatments of PAAG complications and adverse reactions (6). Documented complications following PAAG injections include induration, lumps, hematoma, infection, inflammation, persistent mastodynia, poor cosmetic result, glandular atrophy, gel migration and, potentially, a delayed diagnosis of breast cancer (2,7). These complications can be difficult to treat and often necessitate complex surgery that includes gel removal, debridement procedures and, most often, breast reconstruction. Approaches to surgical treatment and subsequent breast reconstruction are not defined primarily because of the limited knowledge about this group of patients (5). The present article aims to summarize complications and the risks associated with PAAG through a case presentation and literature review.

## CASE PRESENTATION

A 45-year-old Asian woman presented initially with complaints of painful breast masses. She had immigrated to Canada from China in 2010, and had previously received PAAG for breast augmentation in 1996 at a local city hospital. She was an otherwise healthy woman who had become recently pregnant with her first child. She was referred to the authors' plastic surgery service by Obstetrics/Gynecology and Genetics as they were following her for her new pregnancy and were concerned about the teratogenicity surrounding her PAAG injections and considered the removal of the implants and termination of her current pregnancy. Given this history of PAAG injections, magnetic resonance imaging (MRI) of the breasts was performed.

MRI revealed multiple masses in both breasts (Figure 1). The right-sided injectable was more subglandular and the left-sided injectable was more intra- and submuscular. At the initial assessment by the service, painful hard masses were observed in both the right and left breasts. The patient stated this had been unchanged soon after her initial augmentation. There had been enlargement of breasts with pregnancy but no signs of infection, nipple drainage or inflammation.

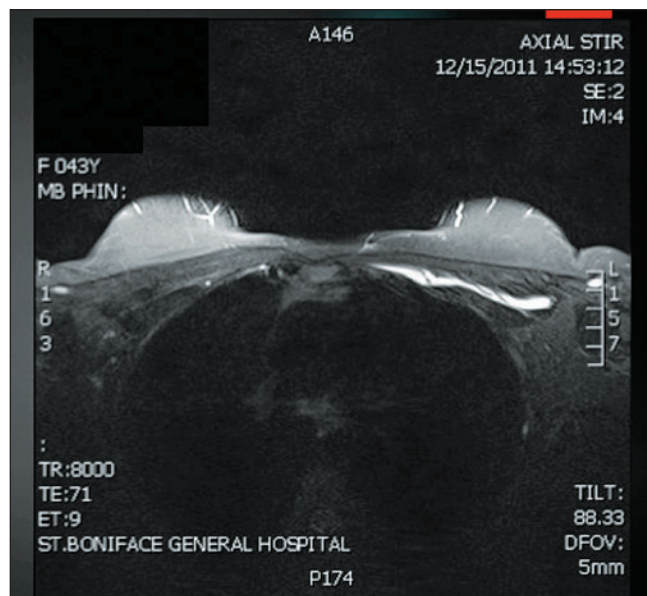
A decision to continue with the pregnancy was made by the patient and the Genetics service, given the lack of specific known teratogenic effects. The patient progressed to deliver her child in May 2012, she did not attempt to breastfeed postpartum. Shortly after the birth of her son, during a second consultation with Plastic Surgery, she was offered the option of PAAG removal and subsequent prosthetic or autologous reconstruction. The patient had desired removal of as much PAAG as possible to minimize future complications (Figure 2). Therefore, given the amount of pectoralis major muscle resection required, concerns about placement of breast implants was raised. Ultimately, the patient elected to undergo bilateral mastectomy with immediate bilateral deep inferior epigastric perforators (DIEP) flaps.

Department of Surgery, Section of Plastic Surgery, University of Manitoba, Winnipeg, Manitoba

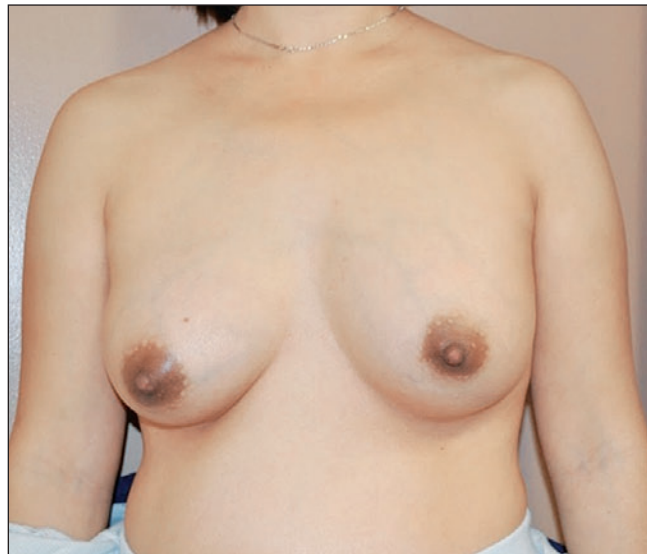Correspondence: Dr Avinash Islur, Department of Surgery, Section of Plastic Surgery, University of Manitoba, Z3027-409 Tache Avenue, St Boniface Hospital, Winnipeg, Manitoba R2H 2A6. Telephone 204-237-2571, e-mail [aislur@sbgh.mb.ca](mailto:aislur@sbgh.mb.ca)



This open-access article is distributed under the terms of the Creative Commons Attribution Non-Commercial License (CC BY-NC) (<http://creativecommons.org/licenses/by-nc/4.0/>), which permits reuse, distribution and reproduction of the article, provided that the original work is properly cited and the reuse is restricted to noncommercial purposes. For commercial reuse, contact [support@pulsus.com](mailto:support@pulsus.com)



**Figure 1)** Magnetic resonance imaging revealing retroglandular, intraglandular, intrapectoral and retropectoral extension of polyacrylamide gel



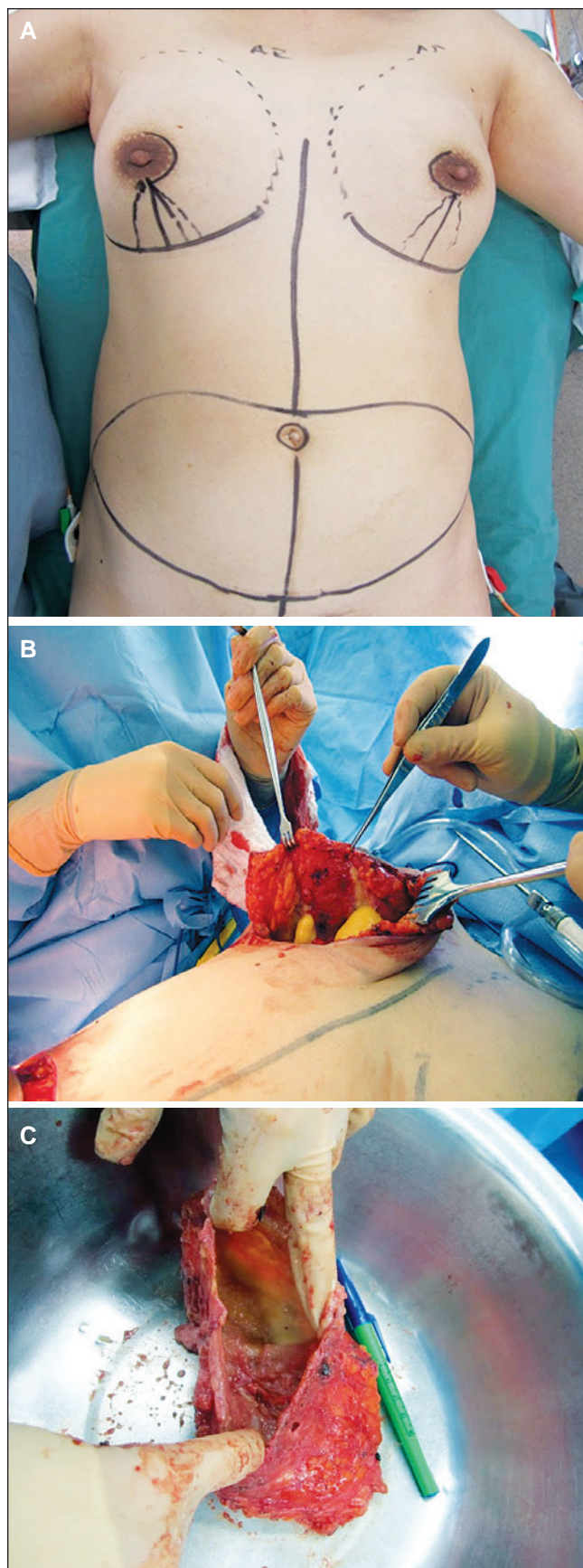
**Figure 2)** Preoperative appearance

Surgery was performed in December 2012 (Figure 3). Intraoperative findings included large amounts of PAAG with a porridge-like consistency deeply infiltrating multiple planes of gland and muscle. Partial capsule formation was identified around some pockets of filler. There was diffuse infiltration throughout pectoralis major, especially on the left side, which necessitated significant amounts of muscle to be removed for maximal PAAG eradication. An uncomplicated immediate reconstruction with bilateral DIEP flaps was performed.

The patient had an uneventful recovery in hospital with complete flap survival bilaterally. On follow-up, good healing was noted in all surgical sites, with no wound dehiscence and the painful masses had complete resolution (Figures 4 and 5). The patient was pleased with the result and future plans to excise the flap skin paddle, which was used for monitoring, and bilateral mastopexy were discussed.

#### DISCUSSION

Global public awareness of PAAG injections has recently been increasing. Surgeons without any experience with these injections are now beginning to encounter patients with PAAG-related complications (5). Knowledge of this implant is important because Canada has



**Figure 3)** A Preoperative markings. B Inframammary fold incision dissection revealing polyacrylamide hydrogel (PAAG) (yellow) material. C Dissected capsule that encased the PAAG



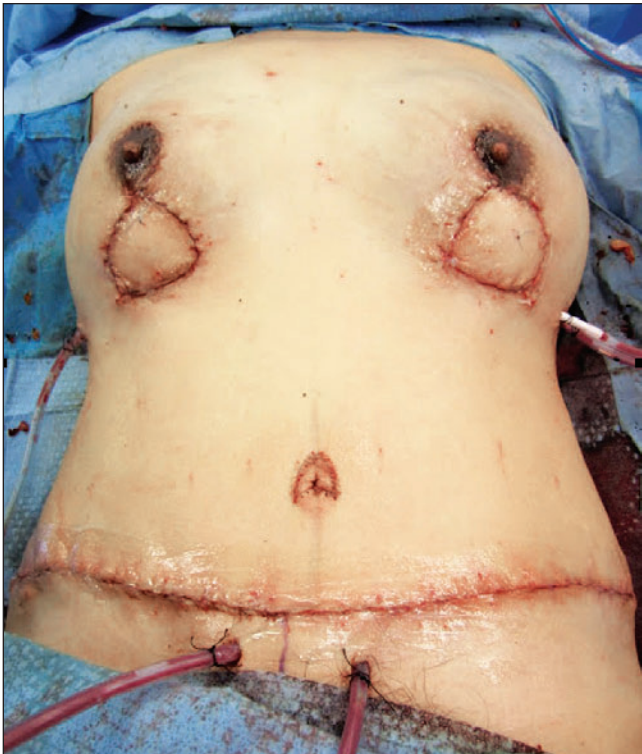

Figure 4) Postoperative appearance

a high Asian population, as well as increasing immigration from the Ukraine, and the recent popularity of the medical tourism industry.

#### Complications

The largest case series of PAAG breast augmentation-related complications was described by Luo et al (6) in their experience with 235 patients. The population ranged in age from 20 to 38 years, and the time from injection to complication presentation ranged from six months to 10 years (39 months). They found the most common complication to be induration and masses (single or multiple) after PAAG breast augmentation, accounting for 78.9% of patients; the second most common complication was pain (67.2%). Other more infrequent complications included asymmetry (20%), psychological problems or worry (12.3%), mastalgia with movement (8.5%), distant gel migration (8.9%), nipple retraction and infection (2.5%). A total of 171 (72.8%) patients experienced multiple complications simultaneously (4,6).

Patlazhan et al (4) shared their 10-year experience in treating patients for PAAG breast augmentation complications in Ukraine and Sweden as fitting into two broad categories: those with (21%) and without (79%) signs of acute inflammation at presentation (mastalgia, hyperemia, fever, swelling, fistula or discharge). All complained of breast asymmetry and/or deformity, with 54% exhibiting significant gel migration.

The most concerning complication, by far, is the increased risk for breast cancer. Cheng et al (7) described two cases of breast cancer following PAAG augmentation. There is evidence to suggest that injectable biomaterial, such as PAAG, does put patients at a greater risk for breast cancer for several reasons. PAAG will inhibit the growth of human fibroblasts and may cause the apoptosis of human fibroblasts, which leaves the potential for carcinogenicity. PAAG also can alter physical parameters, such as the size and the granularity of human fibroblasts, and induce an increase in messenger RNA expression of *c-myc*, a regulatory gene that codes for transcription factor and growth control (7). Also, given the most common clinical manifestations are, in fact, induration or lump and inflammatory reaction caused by PAAG, this may mask the presentation of breast cancer, delaying

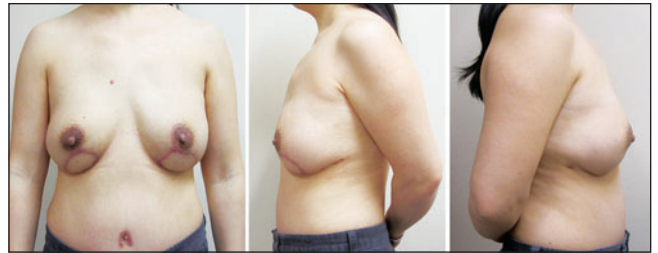

Figure 5) Final result three months postoperatively

correct early diagnosis of malignant changes. Other reasons for a delay in recognition can be accounted for by a confounding effect on interpretation of radiologic studies because mammography cannot accurately assess the postoperative state of a PAAG-injected breast (7).

Wang et al (2) described special considerations for complications related to pregnancy, claiming that PAAG injections cause acute inflammation and galactocele formation during breastfeeding. A large number of PAAGs have the potential to cause mastodynia, the mechanism being secondary to fibrosis and blockage of ducts due to osmotic self-expansion of PAAG. This gel-like substance mixes with breast milk and cannot be excreted. The deposits of PAAG can become a culture medium for infection and inflammation in breast tissue. Additionally, the pressure that is a result of injection may oppress lactiferous ducts, resulting in narrowing. Breastmilk outflow becomes obstructed leading to fermentation in a short time and rapid multiplication bacteria contributing to infection (2).

#### Treatment

Eliciting the appropriate history and early recognition is key to diagnosis and treatment of PAAG-related complications. MRI is recommended as the most reliable screening method for detection of masses following augmentation; the same is true for a PAAG-injected breast. Sentinel lymph node biopsy is also suggested for a PAAG-augmented when a palpable mass is indistinguishable from a gel collection (4,5,7).

A treatment protocol developed by Patlazhan et al (4) uses the presence of acute inflammation and infection as major factors as to whether a patient receive single- or two-stage treatment. Those with signs of infection received two-stage treatment (removal and delayed reconstruction), whereas those with no signs of infection had PAAG masses excised and immediately reconstructed. Similarly, Wang and Li (5) suggested treating local and systemic infections first, allowing the breast to retain its normal shape before performing surgery. This process ranged from approximately two to eight weeks. The literature describes either inframammary or periareolar incision for evacuation of the injectable PAAG (8).

Successful treatment of PAAG augmentation complications requires removal of as much of the material as possible. Conservative management, such as aspiration, is ineffective. Discussion with the patient should explain that complete removal is impossible and that residual PAAG will be left behind. The location, size and extent of infection, and the inter-relation between infected tissues and surrounding tissues, will influence surgical planning and technique. Commonly, incisions at the inframammary fold and drainage at low sites are applied (8). In addition, the injected PAAG that is scattered, foci usually have a capsule and fibrous septum is common between lesions. The key to surgical procedures is to completely separate the infected tissues and cysts, and thoroughly remove the materials and necrotic tissues, granulation tissues and fistula. Given the hydrophilicity of PAAG, the wound should be repeatedly irrigated with antibiotics in normal saline until the fluid in the drainage is clear, and PAAG granules and pus are not observed (5).

#### Reconstruction

There is no literature documenting immediate autologous tissue reconstruction. Reports have only addressed prosthetic reconstruction. Luo et al (6) performed periareolar evacuation of hydrogel in 235 patients,

136 desired volume reconstruction, which was performed via implantation postsurgical resection of PAAG. Dual-plane silicone implants were placed immediately in 108 patients or after six months in 28 patients. Of the 136 who underwent reconstruction, three developed a Baker 2 to 3 capsular contracture, and one inflammatory reaction was documented. Nearly all patients reported a complete resolution of pain, lumps and infection.

DIEP autologous free flap was chosen in our patient because of the extensive amount of PAAG deposits involving the left pectoralis major muscle, necessitating removal of the majority of the muscle; thus, an implant could not be placed. Furthermore, the patient also did not desire the appearance of implants. Nevertheless, in other patients choosing an implant-based reconstruction and the recent popularity of acellular dermal matrix, a total subglandular positioning of an implant could be performed.

## REFERENCES

1. Peters W, Fornasier V. Complications from injectable material breast augmentation. *Can J Plast Surg* 2009;17:89-96.
2. Wang Z, Luo D, Dia X, Yu P, Tao L, Li S. Polyacrylamide hydrogel injection for augmentation mammoplasty; loss of ability for breastfeeding. *Ann Plast Surg* 2012;69:123-8.
3. Kang G, Ong Y. Large unilateral breast autoinflation after breastfeeding linked to polyacrylamide hydrogel injection augmentation. *Aesth Plast Surg* 2011;35:122-4.
4. Patlazhan G, Unukovych D, Pshenishov K. Breast reconstruction and treatment algorithm for patients with complications after polyacrylamide gel injections: A 10 year experience. *Aesth Plast Surg* 2013;37:312-20.
5. Wang Z, Li S, Wang L, Zhang S, Jiang Y, Chen J, Luo D. Polyacrylamide hydrogel injection for breast augmentation: Another injectable failure. *Med Sci Monit* 2012;18:399-408.
6. Luo S, Chen G, Sun Z, Cheng N. Our strategy in complication management of augmentation mammoplasty with polyacrylamide hydrogel injection in 235 patients. *J Plast Reconstr Aesth Surg* 2011;64:731-7.
7. Cheng N, Liu L, Hui L, Chen Y, Xu S. Breast cancer following augmentation mammoplasty with polyacrylamide hydrogel (PAAG) injection. *Aesthetic Plast Surg* 2009;33:563-9.
8. Yu L, Wang J, Zhang B, Zheng D, Zhu C. Treatment of breast injection with polyacrylamide hydrogel with infiltrated fascia capsule removal: Report on 104 cases. *Aesth Plast Surg* 2012;36:1120-7.

## CONCLUSION

While PAAG breast augmentation has been confined to Europe and Asia, North American surgeons may increasingly encounter foreign patients with PAAG-related problems given globalization and the recent popularity of medical tourism. Complications from PAAG injections present from months to years following injection and include lumps, pain, asymmetry and inflammation. Other concerns include breast cancer, long-term toxicity of the material and breastfeeding issues. While PAAG complications are difficult to correct, surgical drainage and debridement is successful in relieving most symptoms. Postdebridement reconstruction is primarily reported with prostheses. We present a case using autologous free-flap reconstruction to be a potentially successful form of reconstruction.

---

**DISCLOSURES:** The authors have no financial disclosures or conflicts of interest to declare.

---