

Fungus Ball of the Middle Ear: A Case Study

Emilie Bois, MD¹, Malika Boucenna, MD²,
Charlotte Sain-Oulhen, MD¹, and Jean-Baptiste Lecanu, MD¹

No sponsorships or competing interests have been disclosed for this article.

Keywords

fungus ball, aspergilloma, middle ear, aspergillus

Received September 29, 2017; revised September 29, 2017; accepted November 16, 2017.

Aspergillus is a filamentous fungus generally acquired after inhalation of airborne spores. It can lead to a variety of diseases in the sinus cavities, including invasive fungal rhinosinusitis and fungus ball. Fungus balls are a noninvasive accumulation of a dense conglomeration of fungal mycelia, inflammatory cells, fibrin, mucus, and tissue debris; they usually develop in body cavities such as the paranasal sinus¹ and lung cavities.² *Aspergillus fumigatus* is the most commonly found species.³

The most frequent fungus ball is located in the maxillary sinus. It can be asymptomatic or, more frequently, simulate chronic rhinosinusitis with purulent nasal discharge. Imagery shows a small hyperdense mass on computed tomography (CT) scan⁴ and a signal decrease in T1 and T2 sequences on magnetic resonance imaging (MRI). Histopathologic examination with Gomori-Grocott coloration shows fungal hyphae.¹ Treatment is solely surgical: extraction of the fungus ball. No local or general antimycotic treatment is needed.

Usually in the middle ear, aspergillosis develops as an invasive fungal infection.⁵ This disease is an acute and potentially lethal infection associated with local otologic signs, facial palsy, and general septic syndrome. Treatment includes extensive surgical debridement and long-term intravenous antimycotic drugs.

We present an original case of fungus ball of the middle ear, presenting all the characteristics of the common sinus entity. This study was approved by our local ethics committee (Arthur Vernes ethics committee).

Case Report

A 15-year-old male patient was referred to our ear, nose, and throat department for a right tympanic membrane microperforation and chronic otorrhea for the past 15 months. Clinical examination results for the left ear were normal, and he had no relevant medical history (ie, no ventilation tubes or any ear surgery). Iterative medical treatment—including antibiotic ear drops (ciprofloxacin and ofloxacin) and antibiotic therapy with amoxicillin plus clavulanic acid—had no effect. Multiple otorrhea samples were sterile. Pure tone audiometry showed a mean conductive hearing loss of 35 dB.

The CT scan revealed a nonspecific opacity of the middle ear, without bony erosion. MRI indicated a heterogeneous hyperintense mass in T2-weighted images in the tympanic cavity and an area with a low signal in T1- and T2-weighted images next to the long process of the incus.

Surgical exploration revealed an organized fungus ball with brown, crumbly, compact material, localized between the malleus and the incudostapedial articulation, measuring 4 mm in diameter (**Figures 1** and **2**). Significant exudative inflammatory reaction of the middle ear mucosa was noticed, the probable origin of the otorrhea. The fungus ball was removed in 1 piece and sent for histopathologic analysis and culture. We decided against myringoplasty to keep natural drainage.

There was no postoperative complication; the patient was discharged the day of the surgery. Histopathologic analysis revealed fungal hyphae on Gomori-Grocott coloration, without any mucosal invasion, which is typical for a fungus ball. The culture came back indicating *A fumigatus*. Follow-up at 3 months showed complete clinical recovery with spontaneous closure of the tympanic membrane perforation, dry ear, and complete recovery of hearing.

¹Department of Otolaryngology–Head and Neck Surgery, Institut Arthur Vernes, Paris, France

²Department of Radiology, Institut Arthur Vernes, Paris, France

Corresponding Author:

Emilie Bois, MD, Department of Otolaryngology–Head and Neck Surgery, Institut Arthur Vernes, 36 rue d'Assas, 75006 Paris, France.
Email: emiliebois@wanadoo.fr



Creative Commons CC-BY-NC: This article is distributed under the terms of the Creative Commons Attribution 4.0 License (<http://www.creativecommons.org/licenses/by/4.0/>) which permits any use, reproduction and distribution of the work without

further permission provided the original work is attributed as specified on the SAGE and Open Access pages (<https://us.sagepub.com/en-us/nam/open-access-at-sage>).

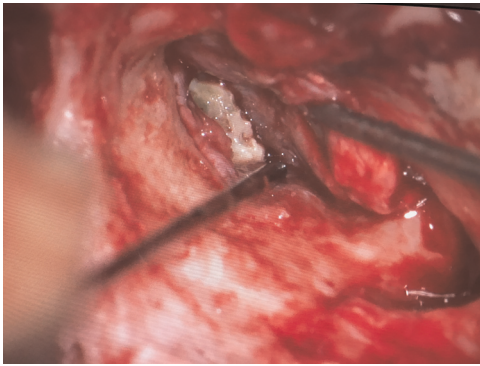


Figure 1. Perioperative photograph of the fungus ball in the middle ear, located next to the long process of the incus.

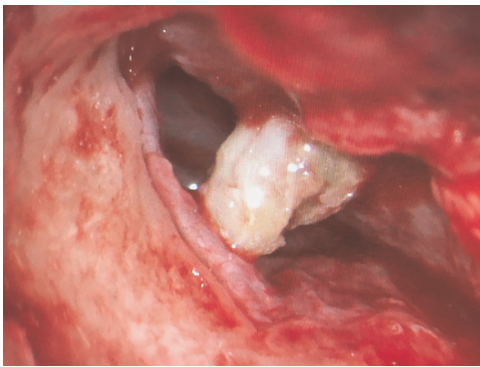


Figure 2. Perioperative photograph of the extraction of the fungus ball, located now in the external auditory canal.

Discussion

To our knowledge, we present the first case of a fungus ball of the middle ear demonstrating all the common characteristics of the disease when found in other cavities. The patient was immunocompetent and presented with benign and aspecific clinical signs. Hypodensity was found in the CT scan and signal loss in T1- and T2-weighted MRI. Typical macroscopic aspect was noted during the surgical exploration. Histopathologic examination and positive culture for fungus confirmed the fungal ball diagnosis.

The nasal sinuses and the middle ear have a relatively similar architecture and physiology: an air cavity with respiratory mucosa. We suppose that the pathology is similar to that found in the sinuses, as the environment is the same: respiratory mucosa, heat, humidity, and darkness, which all promote fungus growth.

Two main physiopathologic hypotheses could explain the presence of *Aspergillus* in the middle ear: spores'

penetration from the respiratory system through the eustachian tube or through a tympanic perforation acquired after simple otitis media.

As with the sinus cavities, there is no need for antimycotic treatment, because there is no invasive mycosis and sole surgical eradication is sufficient.¹ The complete recovery of our patient supports this stance.

Conclusion

This is a case of a fungus ball of the middle ear: it shares the same clinical and imaging characteristics as its sinus cavity counterparts.

Author Contributions

Emilie Bois, collected the data, drafted the initial manuscript, reviewed and revised the manuscript, approved the final version, agree to be accountable for all aspects of this work; **Malika Boucenna**, reviewed the magnetic resonance angiography and computed tomography angiography, reviewed and revised the manuscript, approved the final version, agree to be accountable for all aspects of this work; **Charlotte Sain-Oulhen**, designed the study, drafted the initial manuscript, reviewed and revised the manuscript, approved the final version, agree to be accountable for all aspects of this work; **Jean-Baptiste Lecanu**, operated on the patient, designed the study, reviewed and revised the manuscript, approved the final version, agree to be accountable for all aspects of this work.

Disclosures

Competing interests: None.

Sponsorships: None.

Funding source: None.

References

1. Klossek JM, Serrano E, Peloquin L, et al. Functional endoscopic sinus surgery and 109 mycetomas of paranasal sinuses. *Laryngoscope*. 1997;107:112-117.
2. Soubani AO, Chandrasekar PH. The clinical spectrum of pulmonary aspergillosis. *Chest*. 2002;121:1988-1999.
3. McGuirt WF, Harrill JA. Paranasal sinus aspergillosis. *Laryngoscope*. 1979;89:1563-1568.
4. Kumazawa H, Zehm S, Nakamura A. CT findings of aspergillosis in the paranasal sinuses. *Arch Otorhinolaryngol*. 1987;244:77-83.
5. Ohki M, Ito K, Ishimoto S. Fungal mastoiditis in an immunocompetent adult. *Eur Arch Otorhinolaryngol*. 2001;258:106-108.