

DOT/FAA/AM-00/19

Office of Aviation Medicine  
Washington, D.C. 20591

# **Refractive Surgery in Aircrew Members Who Fly for Scheduled And Nonscheduled Civilian Airlines**

Van B. Nakagawara  
Kathryn J. Wood  
Ronald W. Montgomery  
Civil Aeromedical Institute  
Federal Aviation Administration  
Oklahoma City, Oklahoma 73125

May 2000

Final Report

This document is available to the public  
through the National Technical Information  
Service, Springfield, Virginia 22161.



U.S. Department  
of Transportation  
**Federal Aviation  
Administration**

## N O T I C E

This document is disseminated under the sponsorship of the U.S. Department of Transportation in the interest of information exchange. The United States Government assumes no liability for the contents thereof.

# Technical Report Documentation Page

1. Report No. DOT/FAA/AM-00/19		2. Government Accession No.		3. Recipient's Catalog No.	
4. Title and Subtitle Refractive Surgery in Aircrew Members Who Fly for Scheduled and Nonscheduled Civilian Airlines				5. Report Date May 2000	
				6. Performing Organization Code	
7. Author(s) Nakagawara, V.B., Wood, K.J., Montgomery, R.W.				8. Performing Organization Report No.	
9. Performing Organization Name and Address FAA Civil Aeromedical Institute P.O. Box 25082 Oklahoma City, OK 73125				10. Work Unit No. (TRAIS)	
				11. Contract or Grant No.	
12. Sponsoring Agency name and Address Office of Aviation Medicine Federal Aviation Administration 800 Independence Ave, S.W. Washington, D.C. 20591				13. Type of Report and Period Covered	
				14. Sponsoring Agency Code	
15. Supplemental Notes This work was performed under task AM-A-99-TOX-203.					
16. Abstract <p><b>Introduction.</b> Civil airmen with refractive surgery are present in all classes of aeromedical certificate holders. Refractive surgical procedures have been associated with numerous side effects, including glare, reduced contrast sensitivity, and fluctuating visual acuity. These side effects may render the quality of vision unacceptable in the cockpit environment. This study reviews the aeromedical certification experience with refractive surgery in aircrew members who fly for civilian airlines. <b>Methods.</b> Active airmen with FAA-specific pathology codes 130 (radial keratotomy) and 5179 (general eye pathology with surgical prefix) in the Consolidated Airman Information System medical database during the period 1 January 1994 through 31 December 1996 were identified. Airmen were stratified into those with a first-class medical certificate, an occupational code 1 (pilot, copilot, first, and second officer) or code 2 (flight engineer), and an employer code of a scheduled or nonscheduled airline. The medical records of these airmen were reviewed, and the clinical data were collated and analyzed. <b>Results.</b> A total of 133 flight crewmembers (125 pilots and 8 flight engineers) were identified as employees of airlines and having had refractive surgery. Seventeen airmen (12.8%) were miscoded and 2 airmen (1.5%) were lost to follow-up. Of the 114 pilots with refractive surgery, 97 (85.1%) were incisional procedures, 15 (13.2%) were laser procedures, and 2 (1.7%) were complex surgical procedures. Three airmen (2.6%) had serious complications resulting from the refractive procedure, including postoperative stromal haze, depth perception problems, and a perforated cornea and crystalline lens resulting in a cataract. <b>Conclusions.</b> The preponderance of aircrew members who have had refractive surgery and fly for scheduled or nonscheduled airlines have incisional refractive procedures, which reportedly have the most critical visual side effects. A considerable number of airmen have had laser procedures, of which the long-term effects are still unknown. Although some serious complications have resulted from refractive surgery, the study indicates these complications have not affected an applicant's ability to receive an airman medical certificate.</p>					
17. Key Words Aviation; Vision; Refractive Surgery; Aeromedical Certification; Occupational Health			18. Distribution Statement Document is available to the public through the National Technical Information Service, Springfield, Virginia 22161		
19. Security Classif. (of this report)  Unclassified		20. Security Classif. (of this page)  Unclassified		21. No. of Pages  11	
				22. Price	



---

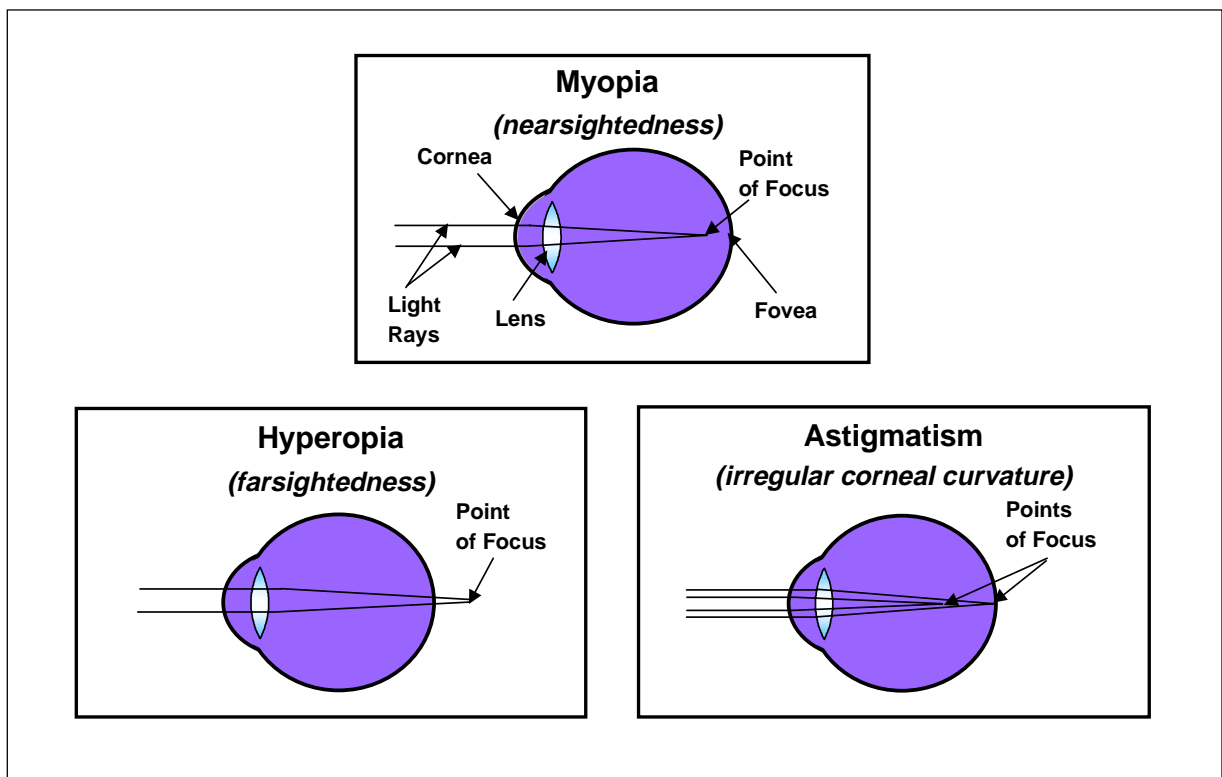
# REFRACTIVE SURGERY IN AIRCREW MEMBERS WHO FLY FOR SCHEDULED AND NONSCHEDULED CIVILIAN AIRLINES

## INTRODUCTION

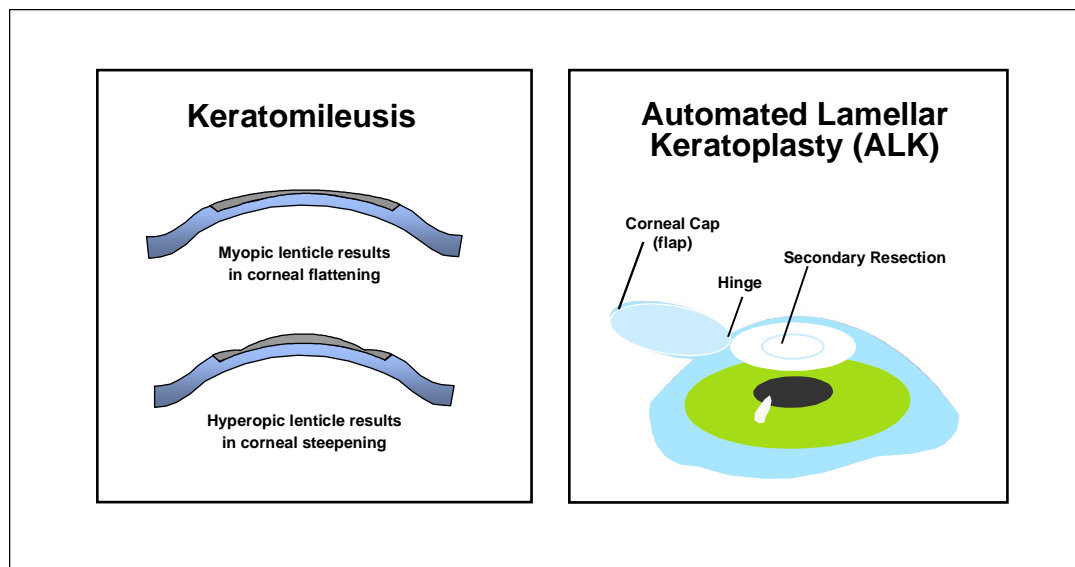
Refractive error is an optical defect that prevents light rays from being focused as a clear, single image on the retina. There are three types of refractive conditions: myopia (nearsightedness), hyperopia (farsightedness), and astigmatism (irregular cornea) (see Figure 1). Approximately 55% of the U.S. population are dependent upon eyeglasses or contact lenses to achieve a quality of vision satisfactory for their daily needs (1). However, some individuals have opted to use refractive surgery to free or reduce their dependence on these traditional ophthalmic devices.

During the 1960s, complex surgical procedures, such as keratomileusis and automated lamellar keratoplasty (ALK), were developed to correct refractive

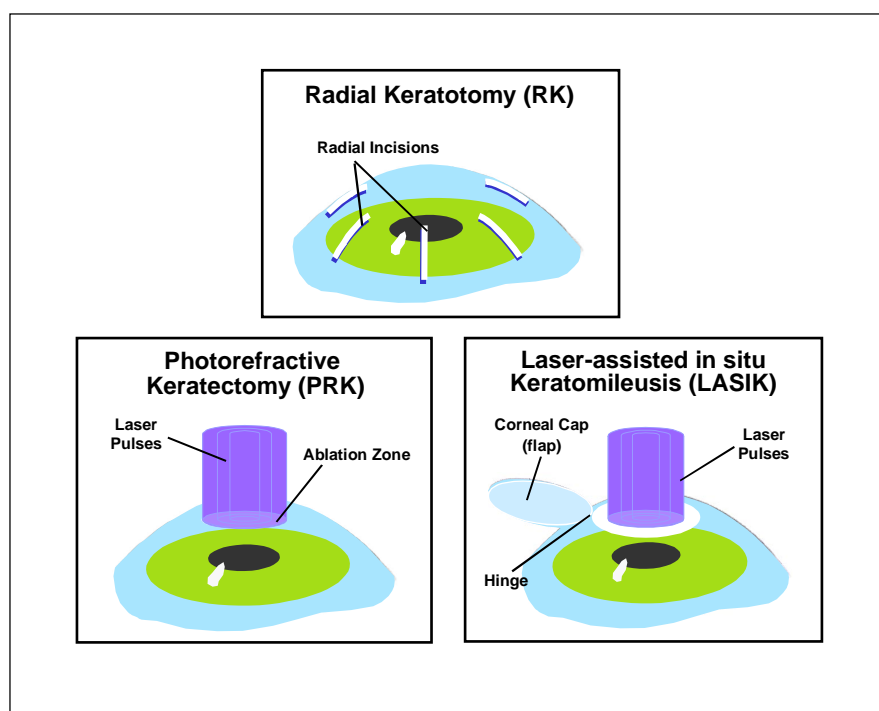
error. Keratomileusis requires the removal of the anterior two-thirds of the cornea with a microkeratome (a specially designed scalpel). The corneal section (lenticle) is then frozen and cryolathed according to a computer program and resutured to the cornea bed (2) (see Figure 2). With ALK, the microkeratome is used to make a primary cap and a second shaping resection (see Figure 2). The cap is then folded back into position (3). Due to complications associated with the sophisticated equipment, inherent unpredictability with lenticle reshaping, individual variability in healing, and the higher level of surgical skill required, these procedures never gained widespread popularity (3,4).



**Figure 1:** The diagrams above illustrate the three most common forms of refractive error.



**Figure 2:** The two diagrams on the left show the cornea in cross section after keratomileusis. After reshaping to correct for myopia or hyperopia, the lenticle sections are returned to their original positions in the cornea. The diagram on the right illustrates an ALK procedure. The stromal tissue beneath the hinged corneal flap is removed prior to returning the flap to its original position.



**Figure 3:** The diagrams above illustrate the most common forms of refractive surgery.

Radial keratotomy (RK) was first introduced in the United States in the late 1970s and has been performed on more than one million Americans (5). The procedure consists of making incisions radially on the peripheral cornea to a depth of 90-95% of the corneal thickness, leaving the clear central optical zone untouched (see Figure 3). These incisions weaken the cornea and allow intraocular pressure to push the peripheral cornea out, flattening the apex and reducing its refractive power (2). Patients with RK normally have stabilized vision within a week post-operatively and minimal risk of vision loss from surgical complications (8.3% mild and 0.3% severe (6,7). When complications do occur, they include decentered optical zone, monocular diplopia, traumatic rupture of keratotomy scars, endothelial cell loss, delayed wound healing, over- or under-correction, induced astigmatism, glare disability, fluctuating acuity, reduced best corrected visual acuity (BCVA), and diminished night vision (2,8,9,10,11,12,13,14,15).

In October 1995, the Food and Drug Administration (FDA) approved the first excimer laser to be used for photorefractive keratectomy (PRK). Since then, PRK and a modified form of this procedure, known as laser-assisted in situ keratomileusis (LASIK), have quickly become the refractive surgical procedures of choice. PRK utilizes the excimer laser light to ablate (remove) tissue from the surface of the cornea, reducing its curvature and minimizing or eliminating myopia (see Figure 3). Following PRK, it can take several days for vision to improve, and most patients become slightly overcorrected for a few weeks before their vision begins to stabilize. The time required for a patient's vision to stabilize ranges from 3 to 6 months for low myopia and 6 to 18 months for high myopia (16). For most PRK patients, clinical studies have shown excellent refractive stability 1 to 2 years after surgery, with re-treatment rates ranging from 0.64 to 9.1% (17,18). At 3 years, post-operative uncorrected visual acuity of 20/40 or better was found in 83% of eyes (19). PRK complications are infrequent but may include delayed healing, over-correction, corneal scarring, myopic regression, glare/halos, loss of BCVA, decreased contrast sensitivity, night vision problems, and corneal haze (16,20,21,22,23,24).

The LASIK procedure is performed using the excimer laser and microkeratome. The microkeratome slices a thin horizontal flap from the anterior cornea, leaving it connected by a small hinge of tissue. The flap is folded aside and the laser ablates tissue from the cornea's stromal bed, and the flap is then replaced (25) (see Figure 3). LASIK has significantly less corneal scarring and regression, since the Bowman's layer (membrane between the epithelium and stroma) of the cornea is not ablated (26). Typically, LASIK patients experience less pain, stabilize faster, and do not require extended use of topical steroids, compared with PRK patients (26). LASIK complications include loss of BCVA, irregular astigmatism, regression, and night vision problems (27,28,29,30). However, unlike PRK, LASIK can have surgical complications including interface deposits, shifted or lost corneal flap, minor corneal bleeding, and improperly set microkeratome depth resulting in too thin of a corneal flap or perforated cornea (28,31,32).

Civil airmen with refractive surgery are present in all classes of aeromedical certificate holders. It is estimated that one million laser refractive surgical procedures will be performed annually in the U.S. in the year 2000. Refractive surgical procedures have been associated with numerous visual side effects that may render the quality of vision unacceptable in the cockpit environment. This report reviews civil aeromedical certification experience with refractive surgery for the study period 1994-96. It specifically examines the frequency and type of refractive surgery performed on crewmembers who fly for scheduled and nonscheduled airlines.

## METHODS

1. A list of all active airmen who carried Federal Aviation Administration (FAA)-specific pathology codes 130 (radial keratotomy) and 5179 (general eye pathology with surgical prefix), during the period 1 January 1994 through 31 December 1996, was generated from the FAA's Consolidated Airman Information System medical database.
2. The general eye pathology code 5179 is assigned to applicants with various types of eye surgeries. A medical record review identified those airmen who carried pathology code 5179 that had refractive surgery. These airmen and those with pathology code 130 were then collated into a common database.

3. First-class medical certificate holders who had an occupational code 1 (captain, co-pilot, and first and second officers) or occupational code 2 (flight engineers), indicating they worked for a scheduled and nonscheduled airline, were identified and their medical records examined. The clinical data were collated into a second database and analyzed.

## RESULTS

A total of 133 airline crewmembers (first-class medical certificate holders with occupational code 1 or 2) who had refractive surgery were identified by pathology codes (see Table 1). A review of the medical records revealed that 17 airmen (12.8%) were miscoded. Interestingly, 7 of those miscoded airmen were using contact lenses for orthokeratology (i.e., contact lenses used to alter the curvature of the cornea and reduce myopia). Two of the 133 medical records (1.5%) were lost to follow-up. The remaining 114 airmen (85.7%) were found to have undergone refractive surgery. Of these, 97 airmen (85.1%) had incisional procedures, 15 (13.2%) had laser

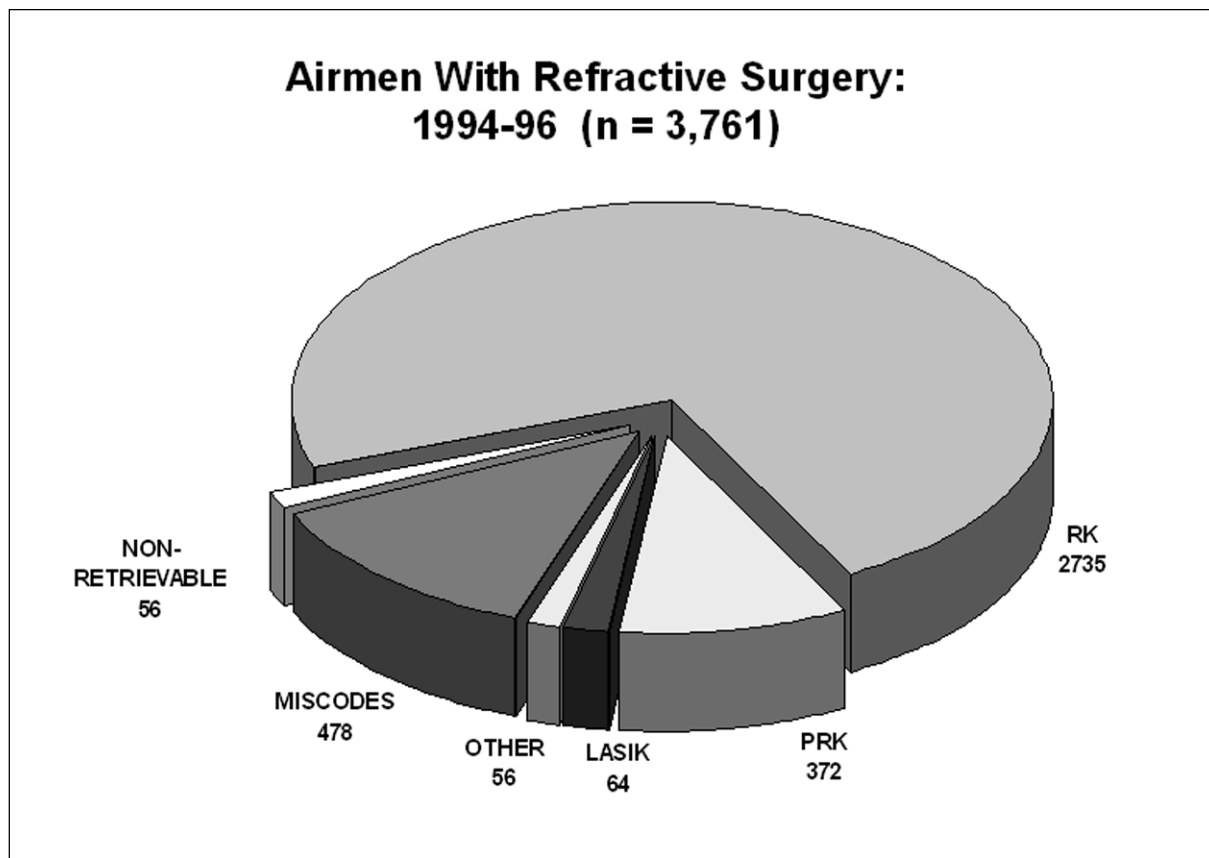
procedures, and 2 (1.7%) had a complex surgical procedure (i.e., ALK). Three airmen (2.6%) had serious complications from their refractive procedure, including postoperative stromal haze after PRK, a perforated cornea and crystalline lens resulting in a cataract after LASIK, and depth perception problems after RK.

Since a physical review of all medical records for aviators with pathology code 130 was not practical, demographic statistics from this sample airline crewmember population ( $n = 132$ ) were applied to those airmen who carried pathology code 130 for the study period 1994-96 ( $n = 3,712$ ). To estimate the total number of airmen with refractive surgery, those with pathology code 5179 ( $n = 50$ ) were then reintroduced to the estimated 130 group ( $n = 3,761$ ). The total estimated refractive surgery population included 2,735 airmen with incisional procedures (RK), 436 airmen with laser refractive procedures (372 with PRK and 64 with LASIK), and 56 airmen with other complex refractive procedures (e.g., ALK), while 478 were miscoded, and 56 records were non-retrievable (see Figure 4).

Types of Refractive Surgery and Complications in First-Class, Code 1 & 2 Airmen				
PROCEDURE	COMPLICATION DESCRIPTION	CODE 1	CODE 2	TOTAL
PRK	STROMAL HAZE ( $n = 1$ , CODE 1)	11	2	13
LASIK	PERFORATED CORNEA ( $n = 1$ , CODE 1)	1	1	2
ALK		2		2
RK	DEPTH PERCEPTION PROBLEMS ( $n = 1$ , CODE 1)	93	4	97
TOTAL		107	7	114
	MISCODED	16	1	17
	RECORDS LOST TO FOLLOW-UP	2		2
TOTAL PROCEDURES		125	8	133

**Table 1:** Results from the review of medical records of all airline crewmembers (1994-96) that held first-class medical certificates with pathology codes for refractive surgery are identified by type of refractive procedure and occupation code.





**Figure 4:** The chart represents the estimated number of aviators in the civil airman population (1994-96) that have various types of refractive surgical procedures. The estimate is based on applying the percentages found in the review of airline crewmembers to the total number of aviators that carried pathology codes for refractive surgery and general eye surgery during the study period.

## DISCUSSION

Optimum vision is essential for pilots who must detect and identify airborne traffic as well as hazards that may be on runways and taxiways. Printed material such as flight manifests, charts and maps, and cockpit instruments need to be clearly visible to ensure that proper flight procedures are safely followed. Therefore, a pilot's choice of refractive correction can affect his/her ability to efficiently perform critical operational activities. The vast majority of pilots who require refractive correction opt for eyeglasses or contact lenses. However, for some aviators who depend on these traditional forms of correction, the cockpit environment can exacerbate what would normally be minor difficulties outside the

cockpit. Spectacle frames can reduce the field of vision, be uncomfortable when not properly fitted, become displaced during flight maneuvers, and are often incompatible with communication and protective breathing equipment. Spectacle lenses may also be dislodged and fogging can occur with changes in air temperature and humidity. Contact lenses have been displaced and even lost in flight, and airmen have reported removing contact lenses in flight, primarily for dryness or a foreign body beneath the lens. The low barometric pressure and low relative humidity (10-15%) of an aircraft at altitude can affect contact lens wear. Soft contact lenses dehydrate in low humidity and may result in visual performance loss (low-contrast acuity). In addition, low humidity can reduce lens movement

and increase conjunctival injection (redness) in contact lens users, indicating a tighter fit. Finally, corneal edema has been reported in seemingly well-fit contact lens users with altitude hypoxia.

Airline crewmembers, who are first-class medical certificate holders with occupational code 1 or code 2 designations, must pass the most stringent vision standards of all 3 classes of FAA medical certificates and are examined more often (every 6-months) to maintain their flying status. Currently, all applicants with refractive surgical procedures may obtain a medical certificate without a waiver if they meet the visual acuity standards for the class of medical certificate requested. However, these applicants are required to submit verification from an eyecare specialist that their vision is stable, healing is complete, and that no increased glare sensitivity is present.

The majority (85.1%) of airline crewmembers with refractive eye surgery had incisional refractive surgery (RK). The ophthalmic literature suggests that this procedure is more frequently associated with visually compromising side effects (10,14,15). About 13.2% of airline crewmembers had laser refractive procedures (PRK = 13 and LASIK = 2). Since the excimer laser used to perform refractive surgery was not approved by the U.S. Food & Drug Administration (FDA) until October 1995, this suggests that aviators had their procedures performed in other countries or as a part of the original FDA clinical trials. In our population, only 2.63% reported serious visual side effects attributable to their refractive procedures. Fortunately, these complications did not affect their ability to obtain an aeromedical certificate and continue their aviation careers.

There are several important factors regarding refractive surgery that may increase the risk of operational errors for aviators. These include:

- **The long-term effects of laser refractive surgery techniques are unknown.** Aviators often continue to fly professionally and/or privately for decades. Normal age-related changes in vision performance might be exacerbated by these procedures. Younger pilots may choose refractive surgery to satisfy aeromedical vision standards and to qualify for low-cost pilot training (e.g., school programs, civilian employers).
- **The quality of vision that results from refractive surgery may be compromised.** Although the high-contrast Snellen visual acuity test used in aeromedical certification examinations may be normal after refractive surgery, results from more sensitive measures of vision performance, such as glare or contrast sensitivity tests, are often abnormal.
- **Unequal refractive surgery is used on some patients to induce monovision for the correction of presbyopia.** Monovision (one eye corrected for distance and one eye for near) is often performed using refractive surgery (33,34). The effect of monovision refractive surgery may result in additional operational errors (Note: Monovision contact lenses were found to be a causal factor in an airline accident (35).). Currently the "Guide for Aviation Medical Examiners" states that "the use of a contact lens in one eye for distant visual acuity and a lens in the other eye for near visual acuity is not acceptable (36)."
- **The compatibility of refractive surgery to the aviation environment has not been fully investigated.** Rapid acceleration and deceleration, lower relative humidity and oxygen levels, decompression, and increased cosmic and ultraviolet radiation may affect the surgically altered corneal tissue. Future use of high-altitude civil transport aircraft may further increase these environmental stresses on the pilots' vision.

In conclusion, the majority of aircrew members with refractive surgery who fly for airlines have had incisional refractive procedures, which are associated with more visual side effects. However, this study found a low complication rate and no reported aeromedical certification problems with incisional refractive surgery. There were a considerable number (13.2%) of aircrew members with laser refractive surgery procedures (e.g., PRK, LASIK), for which the long-term effects are still unknown. The number of such procedures is expected to increase significantly in the future. Although there were airmen who reported serious complications resulting from these types of refractive surgery, this study indicates these complications have not affected the airman's ability to obtain an aeromedical certificate. Additional research is recommended to evaluate the effects of aviation environmental stressors on the visual performance of pilots with laser refractive surgery.

## REFERENCES

1. American Optometric Association. Caring for the eyes of America: A profile of the of the optometric profession. 1996 ID1/196.
2. Wilson DR, Keeney AH. Corrective measure for myopia. *Surv Ophthalmol*. Jan-Feb 1990; 34(4):294-304.
3. Slade SG, Updegrapp SA. Advances in lamellar refractive surgery. *International Ophthalmol Clinics*. Fall 1994; 34(4):147-62.
4. Slade SG, Updegraff SA. Complications of automated lamellar keratectomy. *Arch Ophthalmol*. Sep 1995; 113(9):1092-3.
5. Minarik KR. Correction vision after RK. *Optom Manage*. June 1995; 30(6):34-6.
6. Binder PS. Radial keratotomy and excimer laser photorefractive keratectomy for the correction of myopia. *J Refract Corneal Surg*. Jul-Aug 1994; 10(4):442-64.
7. Kraff MC, Sanders Dr, Karcher D, Ragnan M, DeLuca M, Neumann G. Changing practice patterns in refractive surgery: Results of a survey of the American Society of Cataract and Refractive Surgery. *J Cataract Refract Surg*. Mar 1994; 20(2):172-8.
8. Editor. Radial keratotomy for myopia. *Ophthalmol*. July 1993; 100(7):1102-15.
9. McDonnell PJ, Caroline PJ, Salaz JJ. Irregular astigmatism after radial and astigmatic keratotomy. *Am J Ophthalmol*. Jan 1989; 107(1):42-6.
10. Lee BI, Manchee EE, Glasgow BJ. Rupture of radial and arcuate keratotomy scars by blunt trauma 91 months after incisional keratotomy. *Am J Ophthalmol*. Jul 1995; 121(1):108-10.
11. Binder PS, Nayak SK, Deg JK, Zavala EY, Sugar J. An ultrastructural and histochemical study of long-term wound healing after radial keratotomy. *Am J Ophthalmol*. Mar 1987; 103(3):432-40.
12. Waring GO 3rd, Lynn MJ, McDonnell PJ, PERK Study Group. Results of the prospective evaluation of radial keratotomy (PERK) study 10 years after surgery. *Arch Ophthalmol*. Oct 1994; 112(10):1298-1308.
13. Duling K, Wick B. Binocular vision complications after radial keratotomy. *Am J Optom Physiol Opt*. Mar 1988; 65(3):215-23.
14. Enzenauer RW, Wolter A, Cornell FM, Tucker S. Radial keratotomy in the soldier-aviator. *Mil Med*. Aug 1993; 158(8):584-90.
15. Bullimore MA, Sheedy JE, Owen D, Refractive Surgery Study Group. Diurnal visual changes in radial keratotomy; Implications for visual standards. *Optom Vis Sci*. Aug 1994; 71(8):516-21.
16. Epstein D, Fagerholm P, Hamberg-Nyström H, Tengroth B. Twenty-four month follow-up of excimer laser photorefractive keratectomy for myopia, refractive and visual acuity results. *Ophthalmol*. Sep 1994; 101(9):1558-64.
17. Salaz JJ, et al. A two-year experience with excimer laser photorefractive keratectomy for myopia. *Ophthalmol*. June 1993; 100(6):873-82.
18. Lavery FL. Photorefractive keratectomy in 472 eyes. *Refract Corneal Surg*. Mar-Apr 1993; 9(Suppl):S98-100.
19. Hong JC, Salz JJ. Retrospective comparison of photorefractive keratectomy and radial keratotomy. *J Refract Surg*. Nov-Dec 1995; 11(6):439-47.
20. Maguen E. et al. Results of excimer laser photorefractive keratectomy for the correction of myopia. *Ophthalmol*. Sep 1994; 101(9):1548-57.
21. Tengroth B, Fagerholm P, Söderberg P, Hamberg-Nyström H, Epstein D. Effect of corticosteroids in postoperative care following photorefractive keratectomies. *Refract Corneal Surg*. Mar-Apr 1993; 9(suppl):S61-4.
22. Gimbel HV, Van Westenbrugge JA, Johnson WH, Willerscheidt AB, Sun R, Ferensowicz M. Visual, refractive, and patient satisfaction results following bilateral photorefractive keratectomy for myopia. *Refract Corneal Surg*. Mar-Apr 1993; 9(suppl):S5-10.
23. Nizam A, et al. Stability of refraction and visual acuity during 5 years in eyes with simple myopia. *Refract Corneal Surg*. Nov-Dec 1992; 8(6):439-47.

24. Butuner Z, Elliott DB, Gimbel HV, Slimmon S. Visual function one year after excimer laser photorefractive keratectomy. *J Refract Corneal Surg.* Nov-Dec 1994; 10(6):625-30.
25. Ruid LA, Slade SG, Updegraff SA. Laser in situ keratomileusis (LASIK): Form meets function. *Eyecare Technol.* Mar-Apr 1995; 5(2):67-9.
26. Augustine JM. Postoperative advantages of LASIK outweigh intraoperative risks. *Prim Care Optom News.* Mar 1996; 1(2):32.
27. Salchow DJ, Zirm ME, Steildorf C, Parisi A. Laser in situ keratomileusis for myopia and myopic astigmatism. *J Cataract Refract Surg.* Feb 1998; 24(2):175-82.
28. Pesando PM, Ghringhello MP, Tagliavacche P. Excimer laser in situ keratomileusis for myopia. *J Refract Surg.* Sep-Oct 1997; 13(6):521-7.
29. Maldonado-Bas A, Onnis R. Results of laser in situ keratomileusis in different degrees of myopia. *Ophthalmol.* Apr 1998; 105(4):606-11.
30. Burrato L, Ferrarim, Rama P. Excimer laser intrastromal keratomileusis. *Am J Ophthalmol.* Mar 1992; 113(3):291-5.
31. Gimbel HV, Anderson-Penno EE, van West-enbrugge JA, Ferensowicz M, Furlong MT. Incidence and management of intraoperative and early postoperative complications in 1000 consecutive laser in situ keratomileusis cases. *Ophthalmol.* Oct 1998; 105(10):1839-48.
32. Davidorf JM, Zaldivar R, Oscherow S. Results and complications of laser in situ keratomileusis by experienced surgeons. *J Refract Surg.* Mar-Apr 1998; 14(2):114-22.
33. Wright KW, Guemes A, Kapadia MS, Wilson SE. Binocular function and patient satisfaction after monovision induced by myopic photorefractive keratectomy. *J Cataract Refract Surg.* Feb 1999; 25(2):177-182.
34. Maguen E, Nesburn AB, Salz JJ. Bilateral photorefractive keratectomy with intentional unilateral undercorrection in an aircraft pilot. *J Cataract Refract Surg.* Mar 1997; 23(2):169-176.
35. PB97-910403. NTSB/AAR-97-03. NYC97M A005. National Transportation Safety Board. Washington, DC 20594. Aug 1997.
36. Department of Transportation/Federal Aviation Administration. Guide for aviation medical examiners. Washington, DC:1999; FAA Office of Aviation Medicine.