

Case Report

Open Access

Pleomorphic adenoma of minor salivary gland in the parapharyngeal space

Bipin T Varghese*, Paul Sebastian, Elizabeth K Abraham and Anitha Mathews

Address: Department of Surgical Oncology and Pathology, Regional Cancer Centre, Trivandrum, Kerala, India, 695 011

Email: Bipin T Varghese* - geenu@eth.net; Paul Sebastian - deepakpaul@eth.net; Elizabeth K Abraham - cytology@rcctvm.org;

Anitha Mathews - cytology@rcctvm.org

* Corresponding author

Published: 25 February 2003

Received: 27 January 2003

World Journal of Surgical Oncology 2003, 1:2

Accepted: 25 February 2003

This article is available from: <http://www.wjso.com/content/1/1/2>

© 2003 Varghese et al; licensee BioMed Central Ltd. This is an Open Access article: verbatim copying and redistribution of this article are permitted in all media for any purpose, provided this notice is preserved along with the article's original URL.

Abstract

Background: Majority of tumours occurring in minor salivary gland are malignant. Pleomorphic adenoma is of rare occurrence in parapharyngeal space.

Case presentation: A rare case of a minor salivary gland pleomorphic adenoma of the parapharyngeal space is reported. Review of literature, clinical features, pathology, radiological findings and treatment of these tumours are discussed.

Conclusions: Parapharyngeal salivary tumours presents as a painless progressive swelling with majority of these being malignant. Pleomorphic adenoma in parapharyngeal space is of rare occurrence. Complete surgical excision is the treatment of choice.

Background

The majority of minor salivary gland tumours are malignant [1]. Among benign tumours of the minor salivary glands pleomorphic adenoma is the commonest, found most often in the oral cavity. The parapharyngeal space is a very rare site for this tumour. A case of a large pleomorphic adenoma arising *de novo* in the parapharyngeal space is reported.

Case Presentation

A 40-year-old man presented with a gradually progressive painless swelling in the throat and change in quality of speech of one-year duration. On examination there was a smooth firm bulge of the soft palate and right lateral pharyngeal wall and a diffuse firm fullness of the right retro-mandibular fossa and the adjacent submandibular trigone. The swelling was bimanually palpable and ballotable. Postnasal examination showed extension of the swelling into the nasopharynx and indirect laryngoscopy

revealed the lower limit of swelling at the level of vallecula. There was no significant lymph node enlargement in the neck. With the clinical diagnosis of parapharyngeal tumour a CT scan of the head and neck was taken which showed a poorly enhancing tumour measuring 5 × 4 cm in the right parapharyngeal space, extending from the base of skull to the level of vallecula (Figure 1).

Through a mandibular swing approach, to gain entry into parapharyngeal space, the tumour was excised, after controlling right external carotid artery. On gross examination the lesion was 6 × 4 × 2.5 cm in size with a whitish faintly lobulated and focally glistening cut surface. Histopathological examination showed a neoplasm having an admixture of epithelial and stromal components. Ducts lined by inner epithelial and outer myoepithelial cells were seen surrounded by a chondromyxoid stroma consistent with pleomorphic adenoma (Figure 2). Postoperative period was uneventful. Patient was treated with

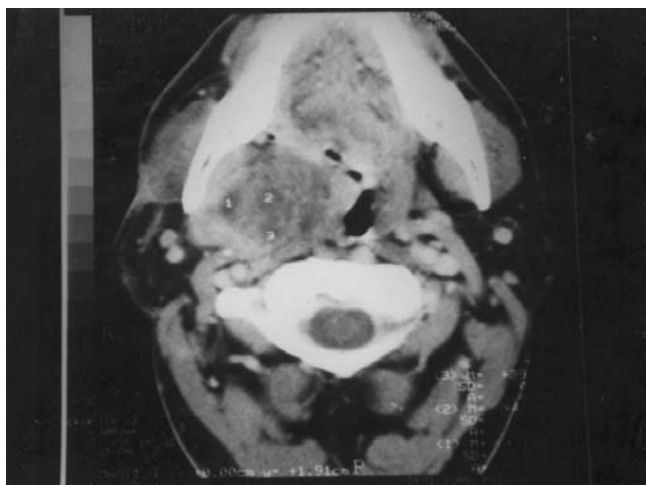


Figure 1
CT Scan of the parapharyngeal tumour.

postoperative adjuvant external radiotherapy delivered to the right parapharyngeal space to a dose of 45 Gy in 15 fractions over 3 weeks, and is disease free after a follow-up of three years.

Discussion

Tumours arising in the minor salivary gland accounts for 22% of all salivary gland neoplasms [1]. Majority of them are malignant with only 18% being benign. Of the benign tumours pleomorphic adenoma is the commonest [1]. The most common site of a pleomorphic adenoma of the minor salivary gland is the palate followed by lip, buccal mucosa, floor of mouth, tongue, tonsil, pharynx, retro-molar area and nasal cavity [1-4].

Benign mixed tumours may occur primarily in parapharyngeal space probably from displaced or aberrant salivary gland tissue within a lymph node. This site of origin is in contrast to the tumours that arise in minor salivary glands medial to the constrictor muscles of the pharynx. Another source of such a tumour is the deep lobe of parotid gland, in which case the tumour may present either as a dumb-bell tumour abutting the stylohyoid ligament or a round tumour within the parapharyngeal space [5]. A comprehensive review of literature showed very few case reports of pleomorphic adenoma arising *de novo* in the parapharyngeal space [6].

Though most of the benign tumours of the minor salivary gland in the oral cavity present as a painless submucosal swelling [1], those from the parapharyngeal space may show additional symptoms, like otalgia, neuralgia, palsies of 9th, 10th or 11th cranial nerves or trismus. Classical

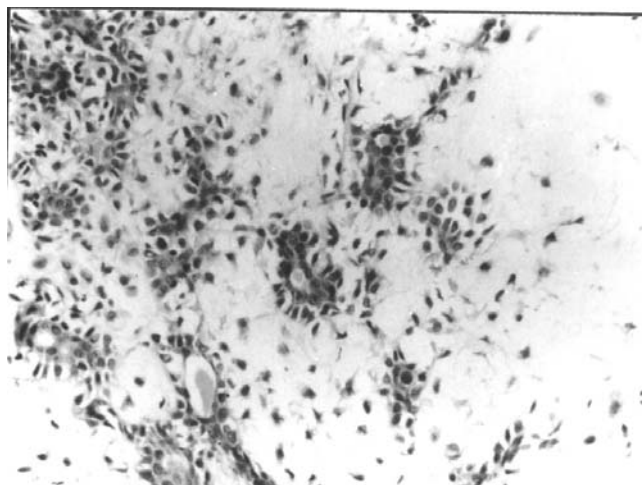


Figure 2
Photomicrograph showing epithelial ducts seen in a chondromyxoid stroma (Haematoxylin and Eosin ×250)

finding of a benign parapharyngeal swelling is a submucosal swelling in the lateral pharyngeal wall with or without extension to retromandibular fossa or the submandibular trigone and bimanual ballotability [5,7,8].

CT scan is an important diagnostic tool in tumours of parapharyngeal space because it helps in determining the extent of disease, local spread and also help to some extent in determining the type of tumour. Contrast enhancement is seen in vascular and neurogenic tumours. Presence of intact fat plane helps in distinguishing benign tumours from malignant. Extension of tumours from the deep lobe of a parotid gland is distinguishable from tumour arising *de novo* in the parapharyngeal space by a fine lucent line representing the compressed layer of fibroadipose tissue between the tumour and deep lobe of parotid [9].

Histopathologically, pleomorphic adenoma is an epithelial tumour of complex morphology, possessing epithelial and myoepithelial elements arranged in a variety of patterns and embedded in a mucopolysaccharide stroma. Formation of the capsule is as a result of fibrosis of surrounding salivary parenchyma, which is compressed by the tumour and is referred to as "false capsule" [9].

The treatment of pleomorphic adenoma is essentially surgical. Though these benign tumours are apparently well encapsulated, resection of the tumour with an adequate margin of grossly normal surrounding tissue is necessary to prevent local recurrence as these tumours are known to

have microscopic pseudopod like extension into the surrounding tissue due to "dehiscences" in the false capsule [9]. Spiro reported a recurrence in 7% of 1342 patients with benign parotid neoplasms and 6% of patients with benign minor salivary gland tumours [1]. It is logical to infer that the recurrence rate would be higher after surgery for parapharyngeal tumour of similar histology, as a wide resection may not be possible at the site due to proximity of vital structures. Postoperative radiotherapy to the parapharyngeal space could possibly reduce the recurrence rate in such tumours [10].

Pleomorphic adenoma arising *de novo* in the parapharyngeal space is of rare occurrence. High index of suspicion and an adequate clearance of the tumour with a cuff of surrounding dispensable normal tissues is the key to successful treatment of such tumours.

Conflict of interest

None declared.

Acknowledgement

We acknowledge with thanks secretarial assistance of Ms. Suseela Devi in the preparation of this manuscript.

References

1. Spiro RH **Salivary Neoplasms: overview of a 35 year experience with 2807 patients.** *Head Neck Surgery* 1986, **8**:177-184
2. Waldron CA, el-Mofty SK and Gnepp DR **Tumours of the intra oral salivary glands: A demographic and histologic study of 426 cases.** *Oral Surg Oral Med Oral Pathol* 1988, **66**:323-333
3. Eveson JW and Cawson RA **Tumour of the minor (oropharyngeal) salivary glands: demographic study of 336 cases.** *J Oral Pathol* 1985, **14**:500-509
4. Cohen MA **Pleomorphic adenoma of the cheek.** *Int J Oral Maxillofac Surg* 1986, **15**:777-779
5. Work PV and Gates GA **Tumours of parapharyngeal space.** *Otolaryngol Clin N Am* 1969, **October**:479-514
6. Bent JP, Dinges D and Whitehouse A **Pathologic quiz case-Minor salivary gland pleomorphic adenoma of the parapharyngeal space.** *Arch Otolaryngol Head Neck Surg* 1992, **118**:664-666
7. Work WP and Hybels RL **A study of tumours of the parapharyngeal space.** *Laryngoscope* 1974, **84**:1748-1755
8. Carrau RL, Myers EN and Johnson JT **Management of tumours arising in the parapharyngeal space.** *Laryngoscope* 1990, **100**:583-589
9. Heeneman H **Parapharyngeal Space tumours.** In: *Scott Brown's Otolaryngology* (Edited by: Kerr AG) Butterworth & Co Ltd 1987, 380-391
10. Perez CA and Brady LW **Treatment of pleomorphic adenoma.** In: *Principles of practise of radiation oncology* JB Lippincott company Philadelphia 1987, 521

Publish with **BioMed Central** and every scientist can read your work free of charge

"BioMed Central will be the most significant development for disseminating the results of biomedical research in our lifetime."

Sir Paul Nurse, Cancer Research UK

Your research papers will be:

- available free of charge to the entire biomedical community
- peer reviewed and published immediately upon acceptance
- cited in PubMed and archived on PubMed Central
- yours — you keep the copyright

Submit your manuscript here:
http://www.biomedcentral.com/info/publishing_adv.asp

